

## **Evaluation of the Accelerator Effects of Platelet Rich Fibrin and Fibrin Adhesive on Wound Healing: Clinical and Histological Findings**

Ali Said Durmuş<sup>1\*</sup>, Ali Osman Çeribaşı<sup>2</sup>, Eda İşgör<sup>1</sup>

<sup>1</sup>Department of Surgery, Faculty of Veterinary Medicine, Firat University, Elazığ, Turkey

<sup>2</sup>Department of Pathology, Faculty of Veterinary Medicine, Firat University, Elazığ, Turkey

---

### **Abstract:**

**Background:** Wound healing is achieved through four phases as hemostasis, inflammation, proliferation, and remodeling. Wound healing is a complicated and important repair process. Studies on wound healing are still continuing. This study was performed to determine the efficacy of platelet rich fibrin (PRF) and fibrin adhesive (FA) on wound healing.

**Materials and Methods:** Fourteen New Zealand rabbits were divided into 2 groups for 7 and 14 day postoperative follow-ups. It was performed that four full-thickness wounds which 5 mm in diameter on the dorsal back skin of each rabbits (totally 54 wounds in all rabbits). Saline solution was instilled to the control group, PRF, FA and PRF plus FA were used in other wounds, respectively (n=14). Clinical examination and measurements of wound were performed every day. On days 7th and 14th seven rabbits were sacrificed and skin specimens were obtained for histological examinations.

**Results:** Measurements of the wound areas were determined that the healing of the treatment groups was better than the control group. On the seventh day, least inflammatory cell infiltration was observed in PRF group, and collagen accumulation and granulation tissue were in the best PRF group.

**Conclusion:** As a result, it was concluded that PRF and FA increase wound healing, is shown that best wound healing in PRF plus FA group. Findings from the study showed that PRF and FA can be used confidently in open wound treatment.

**Key Word:** Platelet rich fibrin; fibrin adhesive; wound healing.

---

Date of Submission: 13-06-2020

Date of Acceptance: 28-07-2020

---

### **I. Introduction**

Fibrin is the activated form of inactive fibrinogen in the blood. Fibrin controls vascular bleeding during hemostasis. Fibrinogen, which is a soluble protein, converts to fibrin, a molecule that cannot be dissolved, forming fibrin gel in the bleeding area. Based on these features, Fibrin Adhesive (FA), Platelet Rich Plasma (PRP) and Platelet Rich Fibrin (PRF) applications have been developed in recent years<sup>1</sup>.

Platelets are essential for clot formation and are responsible for the release of growth factors to initiate and support wound healing. After injury, platelets form a permanent blood clot in the area<sup>2</sup>. The release of growth factors begins to promote tissue formation, healing and strengthening<sup>3,4</sup>. From platelets in the PRF are secreted cytokines such as Transforming Growth Factor- $\beta$  (TGF- $\beta$ ), Platelet Derived Growth Factor (PDGF) and Insulin-Like Growth Factor-I (IGF-I)<sup>5,6</sup>. Cytokines secreted by leukocytes in PRF are IL-1 $\beta$  (Interleukin-1 $\beta$ ), IL-6 (Interleukin-6), TNF- $\alpha$  (Tumor Necrosis Factor  $\alpha$ ), Interleukin 4 (IL-4) and Vascular Endothelial Growth Factor (VEGF)<sup>2,3,4,7</sup>. It has been reported that PRF reduces bleeding, accelerates soft and hard tissue healing, accelerates vascularization of healing tissues through growth factors, increases regeneration when used with bone graft materials, and is non-toxic<sup>1,2,3</sup>.

Tissue adhesives are examined in two groups as FA and cyanoacrylate derivatives. It has been reported that cyanoacrylate derivatives are synthetic compounds and FA is a natural hemostatic agent<sup>8</sup>. FA can be used in regions with difficult sewing application (in organs such as spleen and liver), in vascular and nerve anastomoses, coagulation defects, parenchymatous hemorrhages, hemophilic patients, porous vascular prostheses, bone defects, and skin transplantations<sup>8,9,10</sup>. The aim of the study is to determine the effects of platelet rich fibrin (PRF) and fibrin adhesive (FA) on wound healing.

## II. Material And Methods

Fourteen, 5-6-months old, New Zealand male rabbits were used in the present study. The study was approved by the institutional animal ethics committee. The present study was supported by Firat University Scientific Research Projects Coordination Unit (FUBAP) (project number VF.16.07).

Rabbits were randomly divided into two groups (n = 7) for postoperative 7 and 14 days follow-up. Animals were anaesthetized with intramuscular injection of 35 mg/kg ketamine hydrochlorure (Ketalar, Parke-Davis, 50 mg/ml) and 5 mg/kg xylazine hydrochloride (Rompun, Bayer, 23.32 mg/ml).

PRF was prepared by centrifuging of 6 ml of blood (10 minutes, 400 g). In the study, the combi set of FA (Beriplast P Combi-Set, 1 mL, CSL Behring, Marburg, Germany) was used.

The dorsal surface of the back skin of the rabbits was shaved and four full-thickness excisional wounds were created in rabbits with a disposable 5 mm diameter skin punch biopsy instrument. Saline solution were instilled to the control group, autogenous PRF, FA and PRF plus FA were used in other wounds, respectively (n=14).

In FA group, fibrinogen solution was applied to the wound area and a solution containing thrombin spread just above it. In the PRF plus FA group, after placing the appropriate size PRF in the wound area, a thrombin solution was spread on it by applying a fibrinogen solution. Applications were performed once after postoperatively in all groups, and the wound area was closed with dressing for 1 day.

Wound borders were drawn on a transparent millimeter paper every day and their measurements were performed. On the 7th and 14th days after the operation, 7 rabbits were sacrificed and the skin samples harvested were fixed in 10% buffered neutral formalin solution for 48 hours. Paraffin blocks were prepared from samples undergoing tissue follow-up. Serial sections taken 5 µm thick from the blocks were stained with Hematoxylin Eosin (HE). Microscopic evaluation was performed as indicated in Table 1.

**Table 1:** Scoring values used in the evaluation of wound healing in the control and trial group

Score	Re-epithelialization	Granulation tissue	Collagen accumulation	Inflammatory cell	Angiogenesis	Ulcer
0	None	None or immature	None	None	None	Large or deep ulcer, abscess formation
1	Partial	Little	Little	Little	Less than 5 vessels	Large ulcer
2	Complete but immature or fine	Moderate maturation	Moderate	Moderate	6-10 vessels	None or too small
3	Complete and mature	Mature	Large amount	Large amount	More than 10 vessels	None

### Statistical analysis

SPSS (22.0 version) program was used for the statistical evaluation of wound measurement values and histological scoring. On the 7th day, comparisons between control, PRF, FA and PRF plus FA groups on the same animal were made with the non-parametric Kruskal-WallisH test. In-group comparisons were made with the Mann-Whitney-U test. The same tests were used in comparisons between groups on the 14th day. Intra-group comparisons of each group on different animals on the 7th and 14th days were made with the non-parametric Mann-Whitney-U test. Data were presented as ± SEM value. P <0.05 value was accepted as significantly.

## III. Result

No mortality was observed during this study and all rabbits survived until the end of this study.

In some cases, there was no difference between the minimum levels of inflammation observed between the groups. Results for wound measurements are given in Table 2.

**Table 2:** Wound sizes in healing periods (mm<sup>2</sup>)

Days	Groups				
	Control	PRF	FA	PRF + FA	P
0 (n=14)	19.625	19.625	19.625	19.625	
7 (n=14)	9.43±0.17 <sup>a</sup>	4.00±0.16 <sup>b</sup>	3.54±0.23 <sup>b</sup>	2.93±0.22 <sup>c</sup>	0.001
14 (n=7)	1.86±0.09 <sup>a</sup>	0.43±0.13 <sup>b</sup>	0.43±0.17 <sup>b</sup>	0.28±0.10 <sup>b</sup>	0.001
<b>P</b>	0.000	0.000	0.000	0.000	

<sup>a,b,c</sup> The differences between the groups in the same row are significant.

Control: Untreated group. PRF: Platelet rich fibrin group. FA: Fibrin adhesive group. PRF+FA: Platelet rich fibrin plus fibrin adhesive group.

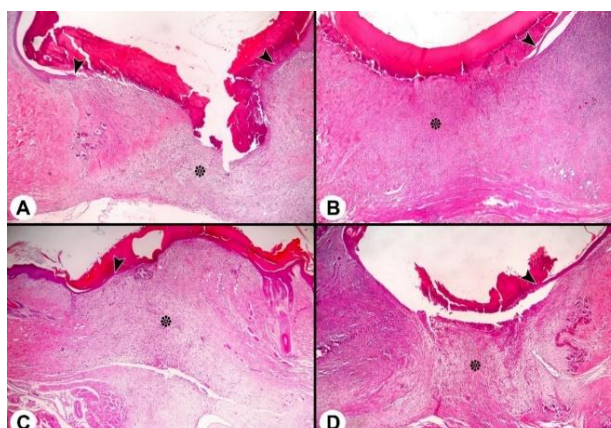
On the seventh day, allergic dermatitis was observed which characterized with edema and severe eosinophilic infiltration in the FA and PRF plus FA groups. No such reaction was observed in the control and

PRF groups. Regarding the allergic reaction, it was observed that wound healing was suppressed in the FA and PRF plus FA groups compared to the other groups at the end of the 7th day. When the groups were evaluated in terms of reepithelialization in a 7-day period (Figure 1, Figure 2), statistically difference was not among the control and treatment groups ( $P>0.05$ ). It was noted that there was a significant difference between the groups in terms of granulation tissue, collagen accumulation, inflammatory cell infiltration and angiogenesis. No difference was observed in terms of epithelialization and ulcer formation. Granulation tissue ( $P<0.05$ ) and collagen accumulation ( $P<0.01$ ) were best shaped in the PRF group. It was observed that the weakest granulation tissue development was in the FA group (Figure 3). The mean score values for the 7th day wound healing in the control and treatment groups are given in Table 3.

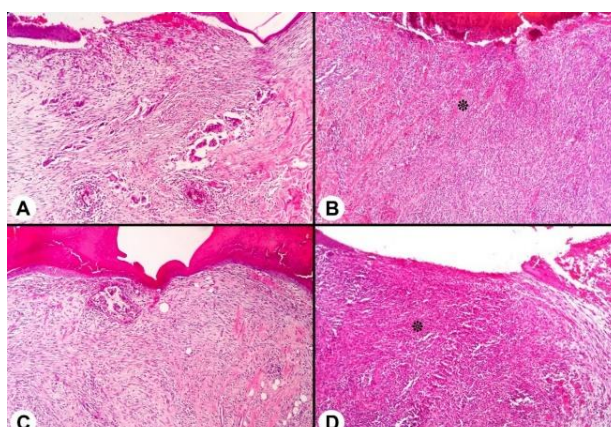
**Table 3:** Average score values for the 7th day wound healing in the control and treatment groups

Parameters	Control	FA	PRF	PRF+FA	SE	P
Re-epithelialization	1.14 ± 0.14	1.43 ± 0.20	1.71 ± 0.18	1.14 ± 0.14	0.09	NS
Granulation tissue	1.71 ± 0.18 <sup>ab</sup>	1.14 ± 0.14 <sup>c</sup>	1.86 ± 0.14 <sup>a</sup>	1.29 ± 0.18 <sup>bc</sup>	0.10	0.05
Collagen accumulation	1.00 ± 0.00 <sup>b</sup>	0.86 ± 0.14 <sup>b</sup>	1.57 ± 0.20 <sup>a</sup>	1.14 ± 0.14 <sup>b</sup>	0.09	0.01
Inflammatory cell	2.00 ± 0.31 <sup>ab</sup>	2.71 ± 0.29 <sup>a</sup>	1.71 ± 0.29 <sup>b</sup>	2.71 ± 0.18 <sup>a</sup>	0.15	0.05
Angiogenesis	2.57 ± 0.20 <sup>ab</sup>	3.00 ± 0.00 <sup>a</sup>	2.29 ± 0.18 <sup>b</sup>	2.86 ± 0.14 <sup>a</sup>	0.09	0.05
Ulcer	1.57 ± 0.48	1.71 ± 0.47	2.43 ± 0.43	1.14 ± 0.34	0.22	NS

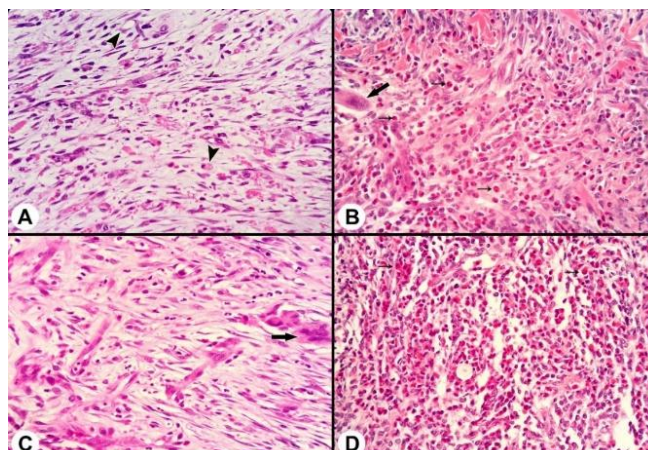
<sup>a,b,c</sup>: There is a statistical difference between the average values carrying different letters in the same rows.  
 NS: There is no statistically significant difference between the groups.



**Fig 1.** A. Control, B. FA, C. PRF, D. PRF+FA. In all groups on the 7th day, partial under scab reepithelialization (arrowheads) and the appearance of early granulation tissue (asterisks), × 20 HE.



**Fig 2.** A. Control, B. FA, C. PRF, D. PRF+FA. On day 7, the appearance of early granulation tissue in wound area, intensive eosinophil infiltrations (asterix) × 50 HE.



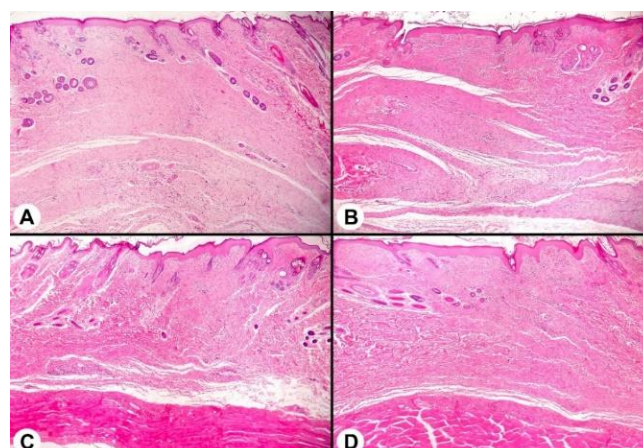
**Fig 3. A.** Control, **B.** FA, **C.** PRF, **D.** PRF+FA. On the 7th day, the appearance of the early granulation tissue in the wound area, angiogenesis (arrowheads), foreign body giant cells (large arrows), eosinophil infiltration (small arrows),  $\times 200$  HE.

On the 14th day, there was no statistically significant difference between the groups (Figure 4) in terms of wound healing, except for inflammatory cell infiltration ( $P > 0.05$ ). Allergic dermatitis was present in the mentioned groups, but its severity decreased compared to the 7th day (Figure 5). There was a significant difference between the FA and PRF groups (Figure 6) in terms of inflammatory cell infiltration ( $P < 0.05$ ). The average score values for the 14th day wound healing in the control and treatment groups are given in Table 4.

**Table 4:** Average score values for the 14th day wound healing in the control and treatment groups

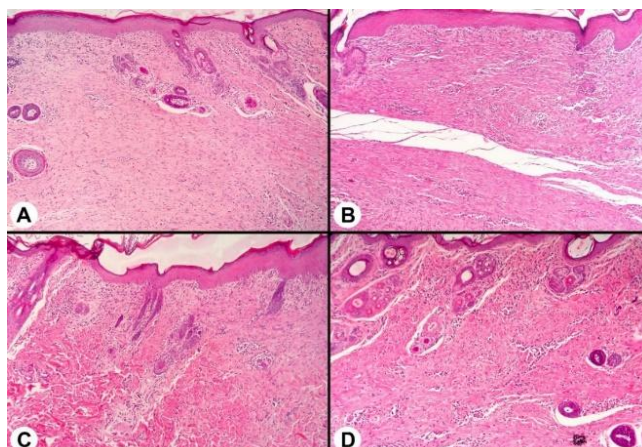
Parameters	Control 14	FA 14	PRF 14	PRF +FA 14	SE	P
Re-epithelialization	$2.29 \pm 0.18$	$2.14 \pm 0.14$	$2.43 \pm 0.20$	$2.43 \pm 0.20$	0.90	NS
Granulation tissue	$3.00 \pm 0.00$	$2.43 \pm 0.20$	$2.71 \pm 0.18$	$2.71 \pm 0.18$	0.09	NS
Collagen accumulation	$2.71 \pm 0.18$	$2.00 \pm 0.31$	$2.57 \pm 0.20$	$2.57 \pm 0.20$	0.12	NS
Inflammatory cell	$1.14 \pm 0.14$ <sup>ab</sup>	$1.86 \pm 0.34$ <sup>a</sup>	$1.00 \pm 0.22$ <sup>b</sup>	$1.71 \pm 0.18$ <sup>ab</sup>	0.13	0.05
Angiogenesis	$1.14 \pm 0.14$	$1.57 \pm 0.20$	$1.14 \pm 0.26$	$1.43 \pm 0.20$	0.10	NS
Ulcer	$3.00 \pm 0.00$	$2.57 \pm 0.43$	$3.00 \pm 0.00$	$3.00 \pm 0.00$	0.11	NS

<sup>a,b</sup>: There is a statistical difference between the average values carrying different letters in the same rows.  
 NS: There is no statistically significant difference between the groups.

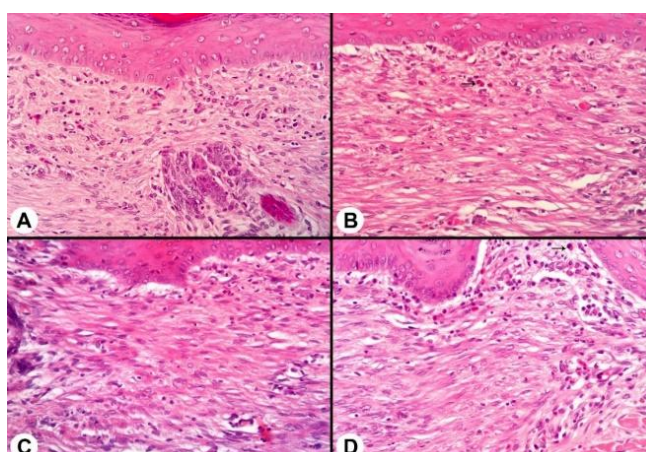


**Fig 4. A.** Control, **B.** FA, **C.** PRF, **D.** PRF+FA. The appearance of completed epithelialization in all groups in the wound area on the 14th day,  $\times 20$  HE.





**Fig 5. A. Control, B. FA, C. PRF, D. PRF+FA.** The appearance of completed epithelization and mature granulation tissue in all groups on the 14th day in the wound area,  $\times 50$  HE.



**Fig 6. A. Control, B. FA, C. PRF, D. PRF+FA.** On the 14th day, the appearance of late granulation tissue in all groups in the wound area, the severity of the eosinophil infiltrations decreased significantly compared to the 7th day (thin arrows),  $\times 200$  HE.

#### IV. Discussion

Long healing process in the skin wounds decreases the quality of life of patients. It is desired to open wounds without infection, in a short time, without scarring and proper healing<sup>11,12,13,14</sup>.

Acceleration of healing in wound treatment is among the main goals. For this purpose, different treatment methods are applied today<sup>1,15,16,17</sup>. In this study, it was aimed to evaluate the findings obtained by applying PRF and FA in experimental skin defects. With this study, it is aimed to find fast, efficient, reliable, uncomplicated, easy and cheap alternative treatment method.

In many studies have investigated the effects of systemic hormones and growth factors on hard and soft tissue metabolism. It is reported that growth factors plays important role in the regulation of cellular events such as proliferation, differentiation, chemotaxis and morphogenesis in the wound healing process<sup>1,18,19,20</sup>.

PRF contains high platelet concentration, FGF, TGF- $\beta$ , PDGF, VEGF, IGF-1, and connective tissue growth factor<sup>21</sup>. These factors accelerate wound healing and tissue regeneration by promoting cell proliferation, increasing collagen synthesis, promoting vascularization, inducing cell differentiation, and leading to the destruction of necrotic tissues<sup>12</sup>. Many studies have shown that PRF supports wound healing in many pathological processes<sup>17,19,22</sup>.

There are studies reporting platelet rich plasma (PRP) use to increase tissue healing<sup>23,24</sup>. However, since PRP, which is in liquid form, flows away from the wound area immediately after application to the wound area, the use of PRP is limited. PRF, on the other hand, has intensive growth factors that accelerate wound healing. Due to PRF clot structure, it can be permanent where it is applied and secretes these factors continuously to the wound area. In this study, it is aimed to benefit from growth factors in the PRF. Therefore, it was considered to use PRF, which has the property to stimulate wound healing for maximum time.

Wounds of different sizes were created in studies investigating wound healing. Wound sizes significantly affect wound healing time<sup>11,12,15,18</sup>. In experimental wound studies, it is considered that it is

sufficient to create wound sizes that does not healing during the follow-up period in the untreated (control) group. In this study, the presence of wounds that did not heal in the control group on the 14th day indicates that the excised skin wound of 5 mm in diameter was of appropriate size.

In this study, it was determined that PRF is easy to apply to the wound area, but the PRF is difficult to fixed in the wound area. FA was easily applied to the wound area according to the method of the manufacturer. It was easy to apply PRF plus FA, and it was determined that FA had a positive effect to the fixating of the PRF in the wound area.

In the present study, in accordance with the other studies<sup>11,12</sup>, it was not observed such as infection and hemorrhage observed.

In this study, it was determined that the healing in the treatment groups was faster than the control group on the 7th day in all of the wound area measurements. In addition, on the 7th day, wound healing in the PRF plus FA group was found to have the best healing. On the 14th day, it was observed that healing in treatment groups better than the control group. On the 14th day, although there was no statistical difference compared to the PRF and FA groups, the improvement in the PRF plus FA group was observed to be better.

On the 7th day, although there is no statistical difference between the PRF and FA groups, the rapid decrease on the FA group's wound area can be explained by the positive contribution of FA to the wound contraction. It is considered that FA helps for uninterrupted release of growth factors from the PRF via fixating the PRF to the wound area for the faster healing in the PRF plus FA group.

It has been reported that PRF significantly contributes to the improvement of sciatic nerve healing compared to the control group<sup>25</sup>. It is reported that PRF accelerates skin wound healing by increasing blood vessel formation in diabetic mice models<sup>18</sup>.

In the present study, the allergic dermatitis table characterized by edema in the wound area and severe eosinophilic infiltration was observed on the 7th day, in the FA and PRF plus FA groups in histological examinations. The absence of such a reaction in the control and PRF groups shows that FA caused these reactions. Similarly, it is considered that FA plays a role in suppressing wound healing.

On the seventh day, the observation of the best accumulation of granulation tissue collagen in PRF group, and the monitoring of the weakest granulation tissue development in the FA group shows the positive contribution of PRF to wound healing.

On the fourteenth day, no statistically significant difference was found between the groups except for inflammatory cell infiltration ( $P>0.05$ ). Minimum inflammatory cell infiltration was observed in the PRF group, and it was significantly less in the PRF group than in the FA group ( $P<0.05$ ). These findings were evaluated as an advantage for the use of PRF in wound healing.

## V. Conclusion

As a result, it was concluded that PRF and FA can be used as a useful material in accelerating the healing of wounds. The use of PRF and FA together not only helps the fixation of PRF to the wound area, but also increases wound healing even if there is no statistical difference. However, it is considered that their contribution to wound healing can be better demonstrated by further clinical studies.

## References

- [1]. Can HN, Durmuş AS. Effects of platelet-rich fibrin on bone healing. *FU Sag Bil Vet Derg.* 2015; 29(2): 91-95.
- [2]. Dohan DM, Choukroun J, Diss A, Dohan SL, Dohan AJ, Mouhyi J, Gogly B. Platelet-rich fibrin (PRF): A second-generation platelet concentrate. Part II: Platelet-related biologic features. *Oral Surg Oral Med Oral Pathol Oral Radiol Endod.* 2006; 101(3): E45-50.
- [3]. Choukroun J, Diss A, Simonpieri A, Girard MO, Schoeffler C, Dohan SL, Dohan AJ, Mouhyi J, Dohan DM. Platelet-rich fibrin (PRF): A second-generation platelet concentrate. Part IV: Clinical effects on tissue healing. *Oral Surg Oral Med Oral Pathol Oral Radiol Endod.* 2006; 101(3): E56-60.
- [4]. Dohan DM, Choukroun J, Diss A, Dohan SL, Dohan AJ, Mouhyi J, Gogly B. Platelet-rich fibrin (PRF): A second-generation platelet concentrate. Part III: Leucocyte activation: A new feature for platelet concentrates? *Oral Surg Oral Med Oral Pathol Oral Radiol Endod.* 2006; 101(3): E51-55.
- [5]. Lee EH, Kim JY, Kweon HY, Jo YY, Min SK, Park YW, Choi JY, Kim SG. A combination graft of low-molecular-weight silk fibroin with Choukroun platelet-rich fibrin for rabbit calvarial defect. *Oral Surg Oral Med Oral Pathol Oral Radiol Endod.* 2010; 109: 33-38.
- [6]. Anitua E, Andia I, Sanchez M, Azofra J, del Mar Zaldueño M, de la Fuente M, Nurden P, Nurden AT. Autologous preparations rich in growth factors promote proliferation and induce VEGF and HGF production by human tendon cells in culture. *Journal of Orthopaedic Research.* 2005; 23: 281-286.
- [7]. Dohan DM, Choukroun J, Diss A, Dohan SL, Dohan AJ, Mouhyi J, Gogly B. Platelet-rich fibrin (PRF): A second-generation platelet concentrate. Part I: Technological concepts and evolution. *Oral Surg. Oral Med Oral Pathol Oral Radiol Endod.* 2006; 101(3): E37-44.
- [8]. Taha MO, De Rosa K, Fagundes DJ. The role of biological adhesive and suture material on rabbit hepatic injury. *Acta Cir Bras.* 2006; 21: 310-314.
- [9]. Demirel AH, Basar OT, Ongoren AU, Bayram B, Kisakurek M. Effects of primary suture and fibrin sealant on hemostasis and liver regeneration in an experimental liver injury. *World J Gastroenterol.* 2008; 14: 81-84.
- [10]. Garza JL, Rumsey E. Fibrin glue and hemostasis in liver trauma: A case report. *J Trauma.* 1990; 30: 512-513.

- [11]. Durmus AS, Yaman M, Can HN. Effects of extractum cepae, heparin, allantoin gel and silver sulfadiazine on burn wound healing: An experimental study in a rat model. *Veterinari Medicina*. 2012; 57(6): 287-292.
- [12]. Han MC, Durmuş AS, Karabulut E, Yaman İ. Effects of Turkish propolis and silver sulfadiazine on burn wound healing in rats. *Revue Med Vet*. 2005; 156(12): 624-627.
- [13]. Hom DB. New developments in wound healing relevant to facial plastic surgery. *Arch Facial Plast Surg*. 2008; 10: 402-406.
- [14]. Yaman İ, Durmuş AS, Çeribaşı S, Yaman M. Effects of Nigella sativa and silver sulfadiazine on burn wound healing in rats. *Vet Med-Czech*. 2010; 55(12): 619-624.
- [15]. Durmus AS, Tuzcu M, Ozdemir O, Orhan C, Sahin N, Ozercan IH, Komorowski JR, Ali S, Sahin K. Arginine silicate inositol complex accelerates cutaneous wound healing. *Biol Trace Elem Res*. 2017; 177: 122-131.
- [16]. Juang P, Fish D, Jung R, MacLaren R. Enteral glutamine supplementation in critically ill patients with burn injuries: a retrospective case-control evaluation. *Pharmacotherapy*. 2007; 27: 11-19.
- [17]. Chignon-Sicard B, Georgiou CA, Fontas E, David S, Dumas P, Ibrai T, Lebreton E. Efficacy of leukocyte- and platelet-rich fibrin in wound healing: a randomized controlled clinical trial. *Plast Reconstr Surg*. 2012; 130: 819e-829e.
- [18]. Ding Y, Cui L, Zhao Q, Zhang W, Sun H, Zheng L. Platelet-rich fibrin accelerates skin wound healing in diabetic mice. *Ann Plast Surg*. 2017;79: e15–e19.
- [19]. Jorgensen B, Karlsmark T, Vogensen H, Haase L, Lundquist R. A pilot study to evaluate the safety and clinical performance of Leucopatch, an autologous, additive-free, platelet-rich fibrin for the treatment of recalcitrant chronic wounds. *Int J Low Extrem Wounds*. 2011; 10: 218-223.
- [20]. Fırat Öztöpalan D, Işık R, Durmuş AS. Growth factors and the role of cytokines in wound healing. *Dicle Univ Vet Fak Derg*. 2017; 10(1): 83-88.
- [21]. Nurden AT, Nurden P, Sanchez M, Andia I, Anitua E. Platelets and wound healing. *Front Biosci*. 2008; 13: 3532-3548.
- [22]. Lundquist R, Holmstrom K, Clausen C, Jørgensen B, Karlsmark T. Characteristics of an autologous leukocyte and platelet-rich fibrin patch intended for the treatment of recalcitrant wounds. *Wound Repair Regen*. 2013; 21: 66-76.
- [23]. Sakata J, Sasaki S, Handa K, Uchino T, Sasaki T, Higashita R, Tsuno N, Hiyoshi T, Morimoto S, Rinoie C, Saito N. A retrospective, longitudinal study to evaluate healing lower extremity wounds in patients with diabetes mellitus and ischemia using standard protocols of care and platelet-rich plasma gel in a Japanese wound care program. *Ostomy Wound Manage*. 2012; 58: 36-49.
- [24]. Sampson S, Gerhardt M, Mandelbaum B. Platelet rich plasma injection grafts for musculoskeletal injuries: a review. *Curr Rev Musculoskelet Med*. 2008; 1: 165-174.
- [25]. Metineren H, Dülgeroğlu TC, Metineren MH. Histopathological effects of platelet rich fibrin on peripheral nerve healing. *Dicle Tip Dergisi*. 2017; 44 (3): 243-250.

Ali Said Durmuş, et. al. "Evaluation of the Accelerator Effects of Platelet Rich Fibrin and Fibrin Adhesive on Wound Healing: Clinical and Histological Findings." *IOSR Journal of Agriculture and Veterinary Science (IOSR-JAVS)*, 13(7), 2020, pp. 33-39.