

Effect of Retin a (tretinoin) on skin wound healing in dogs

Ali SalehMahdi

Surgery and obstetric department, Veterinary medicine college/Al-Qasim green University, Babylon, Iraq

Abstract: Retinoids are widely used in different dermal pathologies. The objective of this study is to determine the effect of retinA in enhancing wound healing in skin of dogs. Eight local breed's dogs weighting from 7 to 10 kg were used in this study. By aseptic technique a 15 cm vertical incision was done in the left flank and then closed by simple interrupted pattern by (2/0) silk. The animals were divided into two equal groups; the first one was treated with 0.5 mg Retin-A cream twice daily for three weeks. Biopsies were taken at 7th and 21st days. The histopathological evaluation revealed that retin A greatly enhanced skin healing by increasing the amount of granulation tissue and accelerating scar formation in comparison with the control group.

Keywords: RetinA, Dog, wound healing.

I. Introduction

Retin A is a vitamin A derivative(1) ,vitamin A presents in three oxidation states; retinal,retinol and retinoic acid which is the retin A(2).Vitamin A is a fat soluble vitamin with four main functions in the body ;cell differentiation (including wound healing),vision ,normal growth and development of both fetus and embryo and a reproduction function (3).There are many dietary sources for vitamin A mainly liver , egg yolk ,yellow green and orange colored fruits and vegetables (4).Retin A or Tretinoin (all – trans retinoic acid) is a topical preparation to improve the integrity and the appearance of photodamagedskin.The main adverse effect are sore eyes, hairloss, skin irritation and dryness, steatosis even cirrhosis(5),all these are rare with topical application (6).

Wounds are breaks in the skin , they are of several types but most undergo an almost similar stages of healing.(7).Wound healing pass into four stages ; inflammation(which is the first stage usually mediated by cytokins and tissue chemotactic factors), the second stage is debridment of the wound by the action of neutrophils and macrophages ,then the third stage of fibroblast proliferation and repair ,finally the stage of maturation of fibrous scar.(8,9).

The aim of the study is to determine the effect of retinA in enhancing wound healing in skin of dogs.

II. Materials And Methods

In this study, eight dogs were examined, their age range from 9 to 12 months and their weight from 7 to 10 kg , they were apparently healthy and treated with antihelminthes.

Intra muscular general anesthesia was given using a mixture of ketamine hydrochloride (15 mg / kg B.W.) and Xylazine hydrochloride (5 mg / kg B.W.)(10,11).

Prior to incision, shaving, disinfection with 70% ethyl alcohol and by using aseptic surgical technique a (15 cm) skin incision is made in the left flank using number (24) surgical blade and haemostasis is achieved by using sterile gauze then the incision is closed by simple interrupted suture pattern using (2/0) silk.

Systemic antibiotics were given to prevent infection using. (procainepenicillin 22000 I.U /kg B.W., streptomycin 10 mg/kg B.W.) by intramuscular injection half an hour before the operation and repeated every 12 hours for 4 days.

Animals were divided into two equal groups; treated and untreated, the first group was treated with retinA cream (tretinoin 0.5 mg/g JANSSEN – CILAG – Switzerland) twice daily for three weeks and the second group is the control group.

Biopsies had been taken at the seventh (7th) and twenty first (21st) days, Specimens were fixed in a solution of 10% formalin (12), and then embedded in wax to be stained with the hematoxylin –eosin staining method. (13).

III. Results

By the seventh day the histopathological picture of the wounds treated with retin A was that of a stratified squamous epithelial lining with hair follicles and sebaceous glands, there is an area of ulceration (discontinuation of the surface epithelium) filled with vascular granulation tissue (small capillaries, many neutrophils and macrophages) with scattered fibroblasts. The degree of the inflammatory response is obviously greater than the untreated group.

The second biopsy at 21st day shows that in the treated group there was a restoration of the epithelial layer, formation of some hair follicles and presence of some although not prominent collagen fibers, the inflammatory response subsided in the treated group but not the untreated one.

Variable	Treated	Untreated
Inflammation	More	Less
Restoration of the Epithelium	Complete	Partial
Collagen fibers	Less	More
Shape of the Scar	Linear-Regular	Irregular
Strength	Less	More

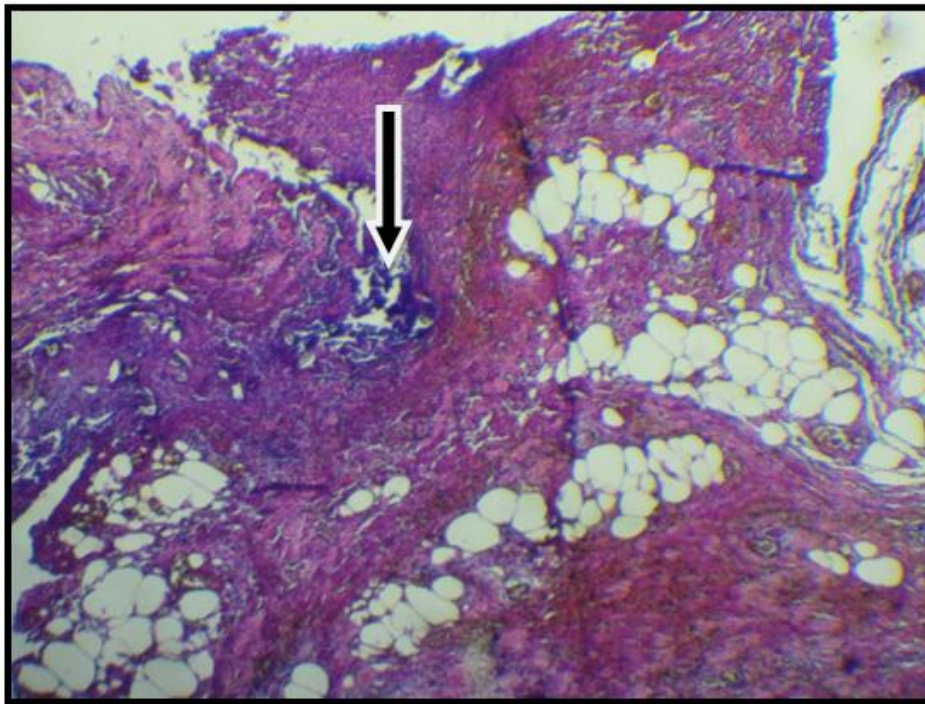


Fig 1: Treated day 7 Mature granulation tissue with heavy inflammation(x10objective)

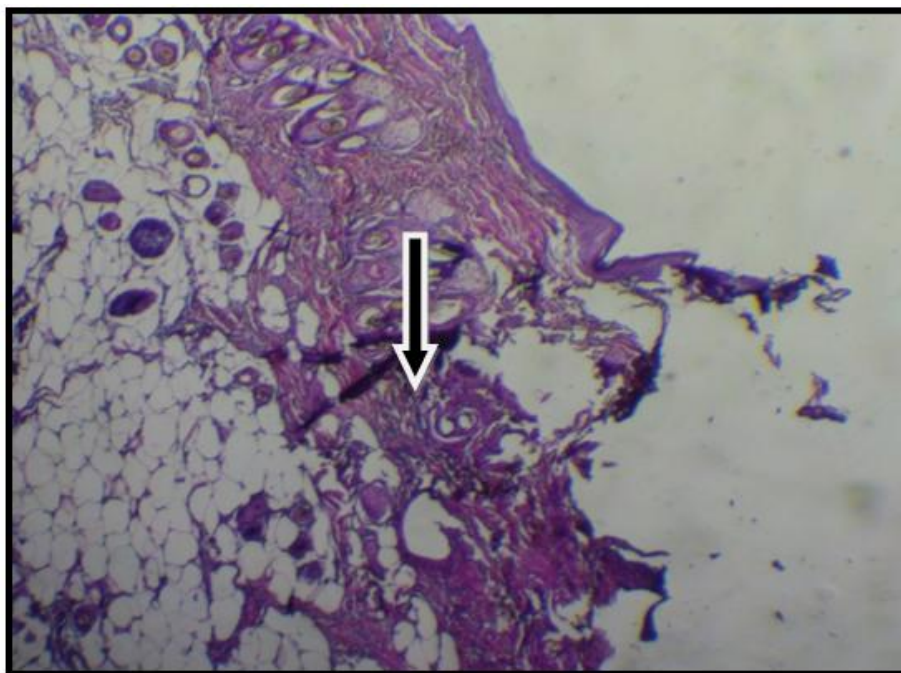


Fig 2: Untreated days 7 less mature granulation tissue with moderate inflammation (x10 objective)

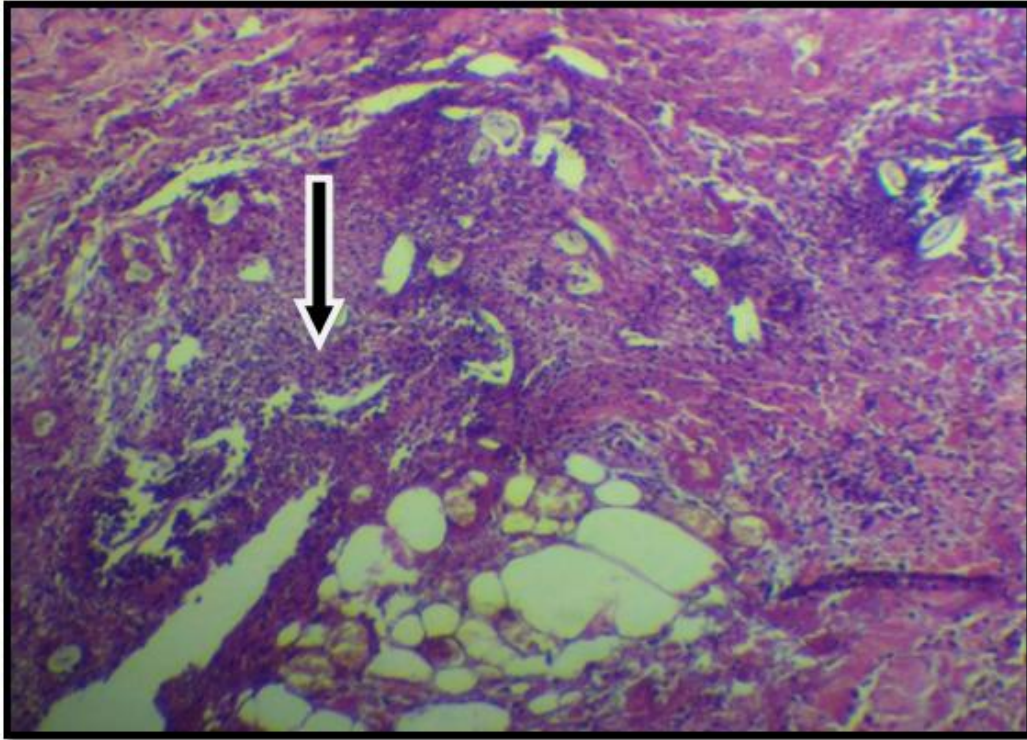


Fig 3: Treated day 7 (x40 objective) mature granulation tissue.

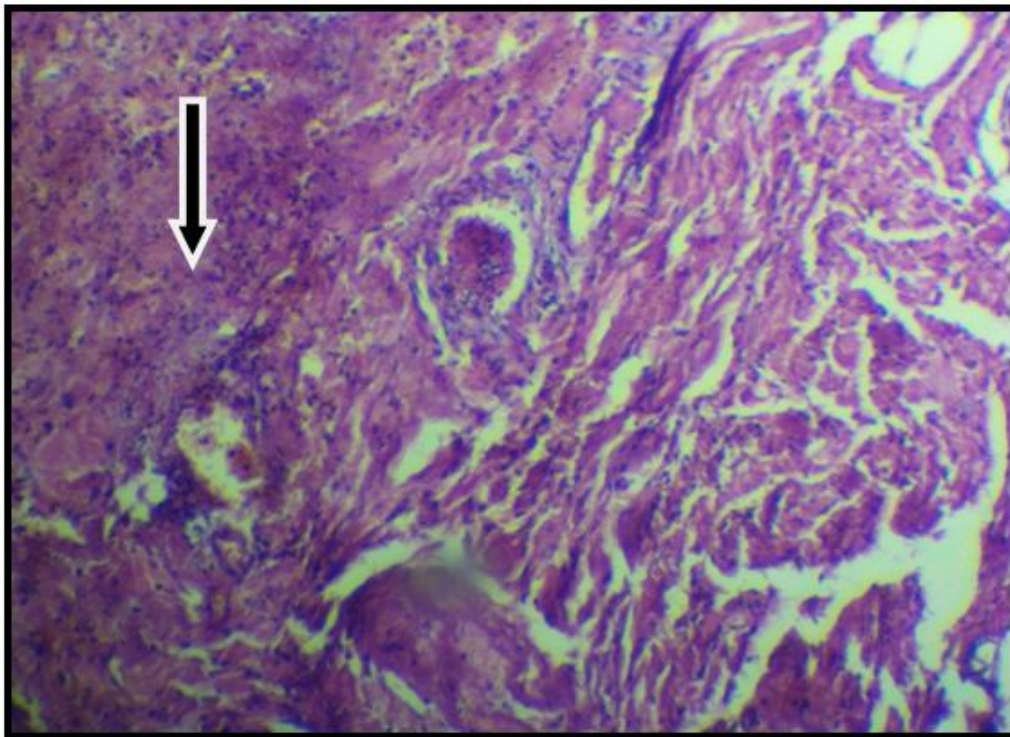


Fig 4: Untreated days 7 (x 40 objectives) early granulation tissue

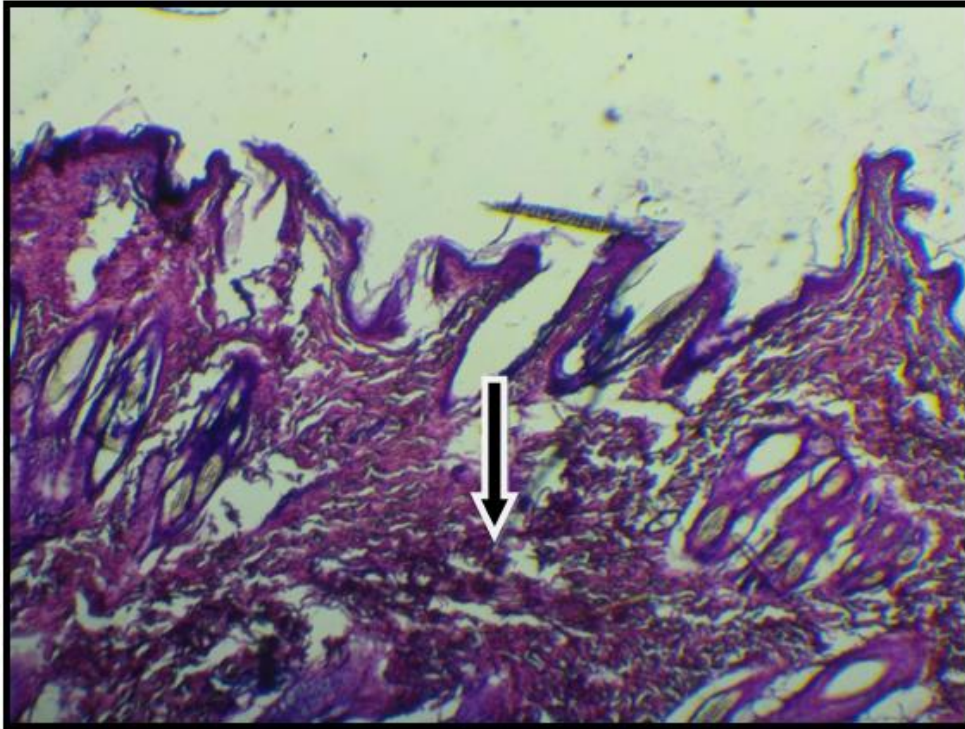


Fig 5: Treated day 21 complete reepithelialization with collagen fibers (x10objective)

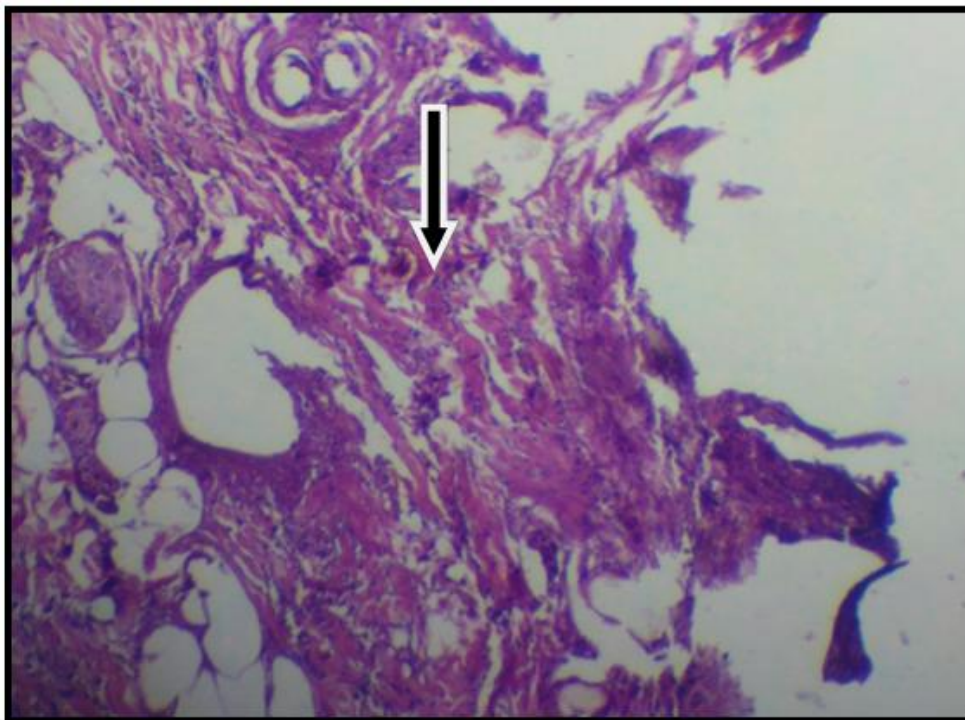


Fig 6: Untreated day 21 incomplete reepithelialization and early collagen formation (x 10 objectives)

IV. Discussion

Retin A is widely applied in human pathology; for cosmetics, wound healing, treatment of hyperpigmentation, treatment of chronic leg ulcerations and others (14 ,15),it is yet to be applied widely in veterinary medicine . Enhancement of wound healing can be achieved by using several modalities with different goals, some aim to accelerate healing others aim to reduce or limit scar production and prevent keloid formation ,of these; chemical factors like vitamins(A,E,C) , hormones and growth factors are among the most widely

used.(16,17). Physical factors such as ultrasonic waves, laser, and magnetic field were applied for the same purpose (18, 19, and 20).

These factors were used to accelerate wound healing in different phases and in different durations, since the inflammatory phase is the most important one, this study shows that retin A had a pronounced effect on the magnitude and the quality of inflammatory infiltrate reflected by the amount and type of granulation tissue, which in turn has a great impact on the time required for healing (21, 22, 23).

On the other hand, the amount and the quality of the produced fibrous tissue will determine the ultimate shape and strength of the scar tissue respectively, this study support the role of retin A in decreasing scar tissue and producing a thin linear scar reflected by the limited amount of the produced fibrous tissue (24,25), while causing some decrease in the scar strength in the initial stage (26).

Acknowledgment

I wish to thanks Dr. Roaa S. Mahdi and Dr. HussainRaooof for their efforts.

References:

- [1]. Alberts D, Ranger-Moore J, Einspahr J, et al (2004): Safety and efficacy of dose-intensive oral vitamin A in subjects with sun-damaged skin. *Clin Cancer Res.*; 10:1875-1880.
- [2]. Larry R. Engelking(2015):Textbook of Veterinary Physiological Chemistry (Third Edition), Pages 282–287.
- [3]. Institute of Medicine. Dietary Reference Intakes for Vitamin A, Vitamin K, Arsenic, Boron, Chromium, Copper, Iodine, Iron, Manganese, Molybdenum, Nickel, Silicon, Vanadium, and Zinc. Washington, DC: National Academy Press; 2001.
- [4]. SanGiovanni JP, Chew EY, Clemons TE, Ferris FL, Gensler G, Lindblad AS, Milton RC, Seddon JM, Sperduto RD.(2007): The relationship between dietary carotenoid and vitamin A, E and C intake with age-related macular degeneration in a case-control study. Report No. 22. *Arch Ophthalmol.* 125(9):1225-32.
- [5]. Vetrugno M, Maino A, Cardia G, et al (2001): A randomised, double masked, clinical trial of high dose vitamin A and vitamin E supplementation after photorefractive keratectomy. *Br J Ophthalmol.* 85(5):537-539.
- [6]. Zouboulis CC. (2001): Retinoids -- which dermatological indications will benefit in the near future? *Skin PharmacolAppl Skin Physiol.*; 14(5):303-315.
- [7]. Thornquist MD, Kristal AR, Patterson RE, et al (2000): Olestra consumption does not predict serum concentrations of carotenoids and fat-soluble vitamins in free-living humans: early results from the sentinel site of the olestra post-marketing surveillance study. *J Nutr.*; 130(7):1711-1718.
- [8]. Blazs G, Gbor M, Schnlau F, Rohdewald P. (2004): Pycnogenol accelerates wound healing and reduces scar formation. *Phytother Res.* Jul; 18(7):579-8.
- [9]. Ermertcan AT, Inan S, Ozturkcan S, Bilac C, Cilaker S. (2008): Comparison of the effects of collagenase and extract of *Centellaasiatica* in an experimental model of wound healing: an immunohistochemical and histopathological study. *Wound Repair Regen.* Sep-Oct; 16(5):674-81.
- [10]. Mckelvey, D. and Holingsheab, K. (1994): Textbook of small Animal Anaesthesia Canine and Feline practice.
- [11]. Moens Y, Fargetton X. (1990): A comparative study of medetomidine/ketamine and xylazine/ketamine anaesthesia in dogs. *Vet Rec.* Dec 8; 127(23):567-71.
- [12]. In: Bancroft JD, Gamble M, ed.(2008): Theory and practice of histological techniques, ed.6. Edinburgh: Churchill Livingstone;
- [13]. Rosai J.(1998): The H & E technique: old mistress apologue. *Pathologica*; 90:739-742.
- [14]. Hung VC, Lee JY, Zitelli JA, HebdaPA .(1989):Topical tretinoin and epithelial wound healing. *Arch Dermatol.* Jan;125(1):65-9.
- [15]. Yoshimura K, Momosawa A, Aiba E, Sato K, Matsumoto D, Mitoma Y, Harii K, Aoyama T, Iga T.(2003): Clinical trial of bleaching treatment with 10% all-trans retinol gel. *Dermatol Surg.* Feb; 29(2):155-60; discussion 160.
- [16]. Sinno, H. and Prakash, S. (2013) Complements and the Wound Healing Cascade: An Updated Review. *Plastic Surgery International*, 2013, Article ID: 146764, 7 p.
- [17]. Riedel, K., Riedel, F., Goessler, U.R., Germann, G. and Sauerbier, M. (2007) TGF- β Antisense Therapy Increases AngiogenicPotential in Human Keratinocytes in Vitro. *Archives of Medical Research*, 38, 45-51.
- [19]. Dirk Meyer-Rogge, Frank Rösken, Peter Holzschuh, Bruno D’hont, IljaKruglikov.(2012) : Facial Skin Rejuvenation with High Frequency Ultrasound: Multicentre Study of Dual-Frequency Ultrasound. *JCDSA*>June ;Vol.2 No.2.
- [20]. MasoudParirokh, ShahriarDabiri, AliRezaBahrampour, Mahmoud Homayonzadeh, Mohammad JafarEghbal.(2006): Effect of Low Power Laser on Incisional Wound Healing Iran Endod J. Winter; 1(4): 157–160. Published online 2007 January 20.
- [21]. Strauch B, Patel MK, Navarro JA, Berdichevsky M, Yu HL, Pilla AA. (2007): Pulsed magnetic fields accelerate cutaneous wound healing in rats. *PlastReconstr Surg.*; 120:425–30.
- [22]. Boo, S. and Dagnino, L. (2013) Integrins as Modulators of Transforming Growth Factor Beta Signaling in Dermal Fibroblasts during Skin Regeneration after Injury. *Advances in Wound Care (New Rochelle)*, 2, 238-246.
- [23]. Popp C, KligmanAM, Stoudemayer TJ. (1995): Pretreatment of photoaged forearm skin with topical tretinoin accelerates healing of full-thickness wounds. *Br J Dermatol.* Jan; 132(1):46-53.
- [24]. Taheri A, MoradiTuchayi S, Alinia H, Orscheln CS, Mansoori P, Feldman SR.(2014): Topical clobetasol in conjunction with topical tretinoin is effective in preventing scar formation after superficial partial-thickness burn ulcers of the skin: A retrospective study. *J Dermatolog Treat.* Dec 29:1-4.
- [25]. Tom WL1, Peng DH, Allaei A, Hsu D, Hata TR.(2005): The effect of short-contact topical tretinoin therapy for foot ulcers in patients with diabetes. *Arch Dermatol.* Nov; 141(11):1373-7.
- [26]. GunesBilgili S, Calka O, Akdeniz N, Bayram I, Metin A.(2013): The effects of retinoids on secondary wound healing: biometrical and histopathological study in rats. *J Dermatolog Treat.* Aug; 24(4):283-9. doi: 10.3109/09546634.2012.697985. Epub 2012 Jul 25.
- [27]. Muehlberger T, Moresi JM, Schwarze H, Hristopoulos G, Laenger F, Wong L.(2005): The effect of topical tretinoin on tissue strength and skin components in a murine incisional wound model. *J Am AcadDermatol.* Apr; 52(4):583-8.