

## Gingival Squamous Cell Carcinoma: A Case Report

Dr. P.S.Rakhewar<sup>1</sup>, Dr. Vrunda Kanjalkar<sup>2</sup>, Dr.Ruby Syed<sup>3</sup>

<sup>1</sup>Professor, Dept. of Periodontics, CSMSS Dental College, Muhs Nashik University, Maharashtra, India.

<sup>2</sup>Professor, Dept. of Oral Pathology, CSMSS Dental College, Muhs Nashik University, Maharashtra, India.

<sup>3</sup>Dept. of Periodontics, CSMSS Dental College, Muhs Nashik University, Maharashtra, India.

---

**Abstract:** Squamous cell carcinoma (SCC) is the most frequent malignant neoplasm affecting structures of the oral mucosa, which accounts for more than 90% of all malignant lesions in the mouth. The aim of this study was to report a case of well differentiated squamous cell carcinoma of gingiva. A 50 year old female seen with 3 weeks history of a painless mass over the lower left posterior buccal gingival area. Clinical examination revealed, a reddish white, ulcerative spongy asymptomatic lesion around the buccal area of teeth 33 to 37 and a leukoplakic lesion over the left border of the tongue & whole of posterior left buccal mucosa. Thus, in view of the clinical symptoms and differential diagnosis of a malignant neoplasm, an incisional biopsy was obtained from the lesion. The diagnosis of well differentiated squamous cell carcinoma was made and fourteen days after incisional biopsy, healing was found to be unsatisfactory. The patient was referred for treatment consisting of surgical excision of the tumour.

**Key Words:** Gingiva, Leukoplakia, Neoplasm, Squamous cell carcinoma, Tumour.

---

### I. Introduction:

Oral cancer is a serious health concern, and is one of the leading cancers in India. Squamous cell carcinoma (SCC) is the most frequent malignant neoplasm affecting structures of the oral mucosa, which accounts for more than 90% of all malignant lesions in the mouth.<sup>[1]</sup> This neoplasm is generally more frequent in males, which is not observed in cases of SCC located in the gingiva.<sup>[1,2]</sup>

Except for carcinoma of the lip vermilion, the most common sites of oral SCC are the tongue and floor of mouth, followed at a lower frequency by the soft palate, gingiva and buccal mucosa.<sup>[3]</sup> The clinical characteristics of SCC vary from case to case and include the exophytic, endophytic, ulcerated, leukoplakic, erythroplastic or erythroleukoplakic forms. Depending on their extent and/or location, these lesions may cause painful symptoms and resorption of adjacent bone seen as a "moth-eaten" appearance on radiographs. SCC of the gingiva is normally painless and it is located in the keratinized portion.<sup>[4]</sup> According to Yoon et al.<sup>[5]</sup>, the clinical aspect of oral SCC can range from a white plaque to an ulcerated lesion. Importantly, when located in the gingiva this type of malignant tumour may resemble inflammatory lesions frequently observed in this region.

Regardless of advances in diagnosis and treatment during the past 40 years, the overall 5 year survival rates for oral and oropharyngeal squamous cell cancer have only slightly improved and remain around 50%. Thus, the early diagnosis and treatment of carcinoma by health care providers is essential in achieving a good prognosis.

### II. Case report:

A 50 year old female patient reported to our dental institute with a chief complaint of swelling in lower left back region of the jaw. According to the patient's description, she had found the painless mass over the lower left posterior buccal gingival area before 3 weeks. Recently, she had begun to feel a toothache and sought medical help. She was neither suffering of any systemic disease nor did she give any positive history as well. She had a habit of betel nut chewing for over 10 years. Extra oral examination showed a hard swelling which extended vertically from inferior to the line joining ala to corner of mouth up to inferior border of mandible and horizontally from angle of mouth to angle and posterior border of mandible.[Fig.1] During intra oral examination, a reddish white, spongy and ulcerative asymptomatic lesion around the buccal area of teeth 33 to 37 [Fig. 2] and a leukoplakic lesion over the left border of the tongue & whole of posterior left buccal mucosa was noted. Poor oral hygiene, halitosis, plaque and calculus deposition over the entire dentition, and gingival bleeding were noted. There was no induration but the lesion showed necrosis of the buccal gingiva and the buccal vestibule region in the 3<sup>rd</sup> quadrant. Separation of the vestibule and the gingiva was observed due to the necrotic destruction in the vestibule region[Fig.3]. The preoperative radiography showed severe alveolar bone loss around the left lower posterior dentition and around 41, 47 region as well. [Fig. 4].

On the first visit, after routine blood examination, an incisional biopsy of the lesion was planned. With the patient's consent, an incisional biopsy was obtained from the part visible, under local anesthesia. The cut surface was grayish white, and the consistency was soft and spongy. This specimen was then submitted for histopathologic examination. Microscopic examination showed oral mucosa with florid epithelial hyperplasia, and marked nests of neoplastic squamous epithelial cells infiltrating into the stroma. The epithelium exhibited dyskeratosis and cellular crowding. Additionally, scattered keratin pearls were present as well as prominent keratinization of individual cells was seen [Fig. 5]. A diagnosis of well-differentiated squamous cell carcinoma was made. The patient was then referred to the Department of Oral Surgery for surgical treatment of the malignant tumor of the gingiva.

### **III. Discussion:**

SCC is the most frequent malignant neoplasm of the mouth, corresponding to 96% of all malignant tumours in this region. Regardless of advances in diagnosis and treatment during the past 40 years, the overall 5-year survival rates for oral and oropharyngeal squamous cancers have improved only slightly and remained around 50%.<sup>[6]</sup> Guggenheimer et al.<sup>[7]</sup> proposed three reasons for a delayed diagnosis of oral cancer: 1) patients at risk did not avail themselves for an examination, 2) oral examinations were not frequently being performed, and 3) the lesions were often overlooked. Although early detection and treatment improved the overall prognosis of oral cancer, delays from the onset of symptoms to clinical diagnosis were common.

SCC of the gingiva more frequently involves the mandible than the maxilla<sup>[3]</sup> and is mainly seen in female older than 50 years.<sup>[2,5]</sup> However, some investigators have reported a higher incidence in male. This controversy in the literature is mainly observed between current studies and those performed before the 1980s, a fact indicating a trend towards a higher incidence among females over the years, as also observed for carcinomas involving other oral sites. One important aspect of gingival SCC is its higher risk of causing metastases and consequent death. Gingival SCC is more aggressive. According to Yoon et al.<sup>5</sup> and Meleti et al.<sup>[8]</sup>, gingival SCC does not show a strong association with classical risk factors such as actinic radiation, tobacco use, either smoked or chewed in its various forms especially when associated with excessive consumption of alcohol. Otherwise, Souza et al.<sup>[9]</sup> have reported a significant association between gingival SCC and smoking and alcohol consumption.

In a study analyzing a period of 18 years (1975 and 1992), Barasch et al.<sup>[2]</sup> reported a non-significant increase in the proportion of gingival SCC compared to the total number of SCCs affecting other oral sites and also observed an increase of the tumour among females. With respect to age, in that study, gingival SCC was most frequent in the seventh decade of life.

Carcinoma of the gingiva is an insidious disease that is usually painless and is often misdiagnosed as one of the many inflammatory lesions of the periodontium such as pyogenic granuloma, periodontitis, papilloma, or even fibroid epulis (inflammatory hyperplasia). Gingival carcinoma typically arises from keratinized mucosa in a posterior site, most often in the mandible, where it often destroys the underlying bone structure, causing tooth mobility.<sup>[10]</sup>

In the present case, an ulcerative lesion was detected in the mandibular gingiva of the patient. After detailed assessment of clinical characteristics; such as staining, verruciform surface and ulceration led to its inclusion in the differential diagnosis of the lesion. SCC should be diagnosed early for a better prognosis. Considering that some of the more severe lesions may mimic common periodontal infections, dentists must be aware that lesions that do not respond normally to routine therapy should be biopsied.

### **References:**

- [1] Wallace ML, Neville BW. Squamous cell carcinoma of the gingiva with an atypical appearance. *J Periodontol.* 1996 Nov;67(11):1245-8.
- [2] Barasch A, Gofa A, Krutchkoff DJ, Eisenberg E. Squamous cell carcinoma of the gingiva. A case series analysis. *Oral Surg Oral Med Oral Pathol Oral Radiol Endod.* 1995 Aug;80(2):183-7.
- [3] Torabinejad M, Rick GM. Squamous cell carcinoma of the gingiva. *J Am Dent Assoc.* 1980 Jun;100(6):870-2.
- [4] Helldén L, Jonsson R. A papillary-verrucous lesion in the gingiva, developing into squamous cell carcinoma. *J Clin Periodontol.* 1987 Jan;14(1):56-61.
- [5] Yoon TY, Bhattacharyya I, Katz J, Towle HJ, Islam MN. Squamous cell carcinoma of the gingiva presenting as localized periodontal disease. *Quintessence Int.* 2007 Feb;38(2):97-102.
- [6] Mashberg A, Samit AM. Early diagnosis of asymptomatic oral and oropharyngeal squamous cancers. *CA Cancer J Clin* 1995;45:328-351
- [7] Guggenheimer J, Weissfeld JL, Kroboth FJ. Who has the opportunity to screen for oral cancer? *Cancer Causes Control* 1993;4:63-66.
- [8] Meleti M, Corcione L, Sesenna E, Vescovi P. Unusual presentation of primary squamous cell carcinoma involving the interdental papilla in a young woman. *Br J Oral Maxillofac Surg.* 2007 Jul;45(5):420-2. Epub 2006 Feb 17.
- [9] Souza RP, Moreira PTB, Paes Junior AJO, Pacheco Neto CM, Soares AH, Rapoport A. [Gingival squamous cell carcinoma: imaging analysis of seven patients] *Radiol Bras* 2003 Aug;36(4):225-7.
- [10] Neville BW, Damm DD, Allen CM, et al. *Epithelial pathology.* In: *Oral and Maxillofacial Pathology*, 2nd ed. Philadelphia: W.B. Saunders; 2002:356-367.

## **Gingival Squamous Cell Carcinoma: A Case Report**

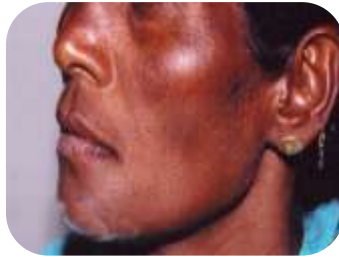

Fig.1: Extra-oral view: firm and hard swelling seen at angle of mandible.

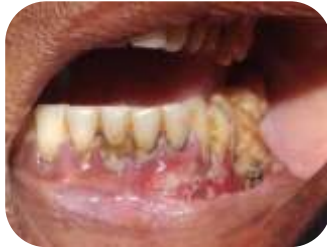
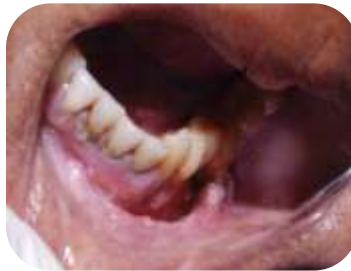
Fig.2: Intra-oral view showing ulcerative asymptomatic lesion.



[1] Fig.3: Intra-oral view showing separation of vestibule and gingiva.

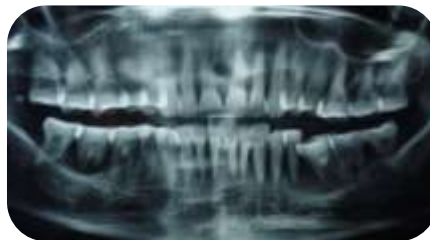

Fig.4: OPG

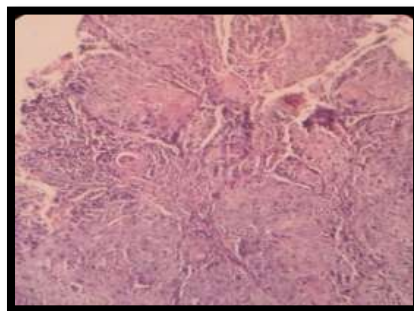


Fig.5: Histological Examination