

Volvulus with perforation of ascending colon in right sided Bochdalek hernia in an 11years old female child-A rare case report

Dr Rana Ranjit Singh, Dr Darpan Bansal, Dr Gurlal Singh Puar

Department of General and Paediatric Surgery, Sri Guru Ram Dass Institute of medical sciences and research, Amritsar

Abstract: Bochdalek hernia is a congenital defect of the diaphragm that is usually diagnosed in the neonatal period and incidentally in asymptomatic adults. Volvulus with perforation of colon in a right sided Bochdalek hernia is exceptional.

Case presentation: An 11 yr old girl was admitted with acute dyspnoea, tachycardia, hypotension and fever. On admission, chest x-ray was done and was interpreted as right pleural effusion and pneumothorax with mediastinal shift to the left side. The thoracoabdominal CT examination suspected an intestinal incarceration through a right diaphragmatic defect. At laparotomy, a right sided Bochdalek hernia was confirmed with volvulus and perforation of the ascending colon. Right hemicolectomy with ileocolic anastomosis was done and she made an uneventful recovery.

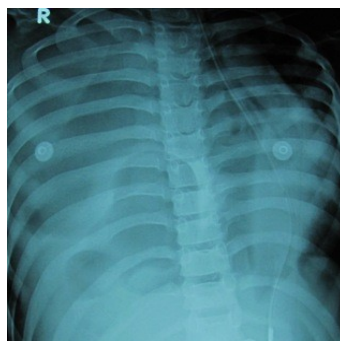Conclusion: Intrathoracic perforation with volvulus of ascending colon is a rare occurrence, for which our patient was treated successfully. Even though rare, this disorder should be recognized, examined and treated appropriately to avoid complications.

I. Introduction

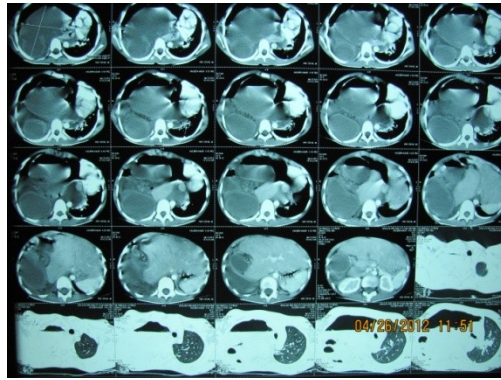
Faecopneumothorax is a very rare but potentially fatal occurrence due to perforation of the colon or the small bowel into the thorax. It may occur as a complication of traumatic diaphragmatic injury but is exceptional in case of a congenital defect. We describe an unusual presentation of Bochdalek hernia in a girl complicated by right sided incarceration, volvulus and secondary perforation of the ascending colon.

II. Case report

An 11 yr old girl presented to the Pediatric Intensive care unit for acute onset respiratory distress. There was no history of previous abdominal trauma or any respiratory or gastrointestinal illness. On arrival in the PICU, the patient was tachypnoeic (respiratory rate 40 per min) and presented with peripheral cyanosis. The oxygen saturation (spo₂) on room air was only 75%, so she was put on ventilator immediately. Other vital signs were temperature 38.4 degree celcius, heart rate was 130 per minute and arterial blood pressure was 110/50mm Hg. Chest auscultation revealed diminished breath sounds on the right side. The abdomen was soft with decreased bowel sounds. Laboratory investigations revealed white blood cell count 14300 / mm³, blood urea 17 mg/ dl and serum creatinine 0.5 mg per dl. Chest x-ray showed large lucent right hemithorax with left mediastinal shift. The patient was suspected to have hydropneumothorax. A contrast enhanced thoracoabdominal Computed Tomography (CT) was performed. This examination showed right hydropneumothorax with herniation of dilated gut loops in the right hemithorax.

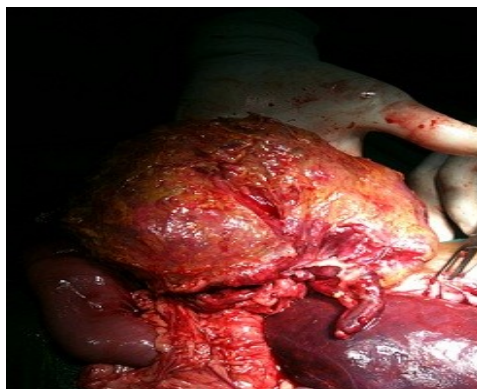

1. Xray chest showing right pneumothorax with shift of mediastinum to opposite side

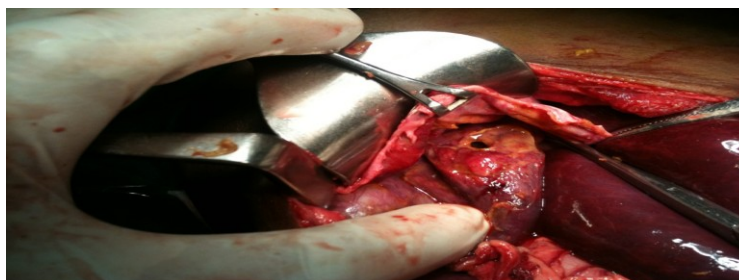


2. CT Chest showing Hydropneumothorax with herniation of gut loops in right chest

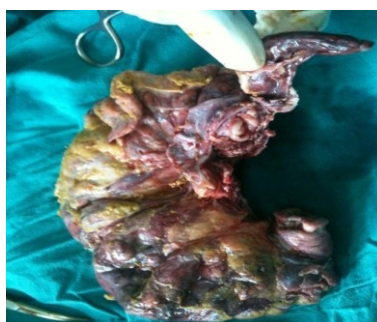Exploratory laparotomy was performed and terminal ileum, caecum, ascending colon and proximal transverse colon was seen to enter the right thoracic cavity. There were dense omental adhesions at the point of entry. Thereby, diaphragm was opened from a de novo site and 1.5 litres of faecal fluid came out. The posterolateral defect (Bochdalek) was then opened and contents visualised. There was present a volvulus of the ascending and transverse colon with perforation at hepatic flexure. Right hemicolectomy with ileocolic anastomosis was done. Chest tube was inserted and the diaphragm was repaired. Post operative chest x-ray showed full expansion of the right lung and the clinical condition improved rapidly after surgery.



3. volvulus of ascending colon. appendix is also seen



4. perforation of hepatic flexure



5. resected specimen showing ileum, caecum, appendix, ascending colon and proximal transverse colon

III. Discussion

Faecopneumothorax is a rare occurrence that usually results from the perforation of the bowel after incarceration in a diaphragmatic hernia. Mostly the herniation of the colon occurred in the left thorax. The main etiology of the diaphragmatic hernia is blunt abdominal trauma and penetrating injuries. [1]

In 1848, Bochdalek first described a congenital hernia resulting from the developmental failure of the posterolateral foramina to fuse properly[2]. Bochdalek hernia is a congenital diaphragmatic defect that occurs in about 12500 live births. As this type of defect is usually symptomatic and badly tolerated, diagnosis is usually made in neonates, and only 5% are discovered after childhood. Right sided Bochdalek hernias are far less common than left sided ones (80-90%) [3]. This is presumably due to the fact that the pleuroperitoneal canal closes earlier on the right side or due to narrowing of the right pleuroperitoneal canal by the caudate lobe of the liver.

There are fewer than 100 cases of Bochdalek hernia reported in adults in the literature and fewer than 20 of those cases involve right sided hernia [2].

In 50% of acute presentations, the hernia sac contains colon, and in 40% the sac may contain multiple other viscera including small bowel, stomach, liver, kidney and gall bladder [2]. The clinical presentation of right sided Bochdalek hernia can also present as strangulation of the contents of the hernia, colon necrosis and haemothorax [4,5].

Symptoms may be intermittent [6] and mechanical factors, including large meals [7], post operative ileus, ileal loop construction [8], gastroenteritis, trauma, obesity, pregnancy and physical exertion [7] which either raise intraabdominal pressure or cause acute distension of abdominal viscera which may precipitate herniation and the onset of symptoms. These precipitating factors were absent in our case. Transabdominal and transthoracic approaches have been recommended for Bochdalek hernia repair [9]

When the patient has signs of intestinal obstruction or strangulation as in our case, the abdominal approach is the first option. A thoracotomy could be additionally required if the intrathoracic bowel cannot be reduced Trans diaphragmatically. If there is no incarcerated bowel, transthoracic repair of a right diaphragmatic hernia seems more appropriate.

In conclusion, a rare case of right sided Bochdalek hernia with intrathoracic volvulus and perforation of ascending colon is described. People with a Bochdalek hernia may not have any symptoms and the disorder may be detected unexpectedly, or the symptoms and expressions may vary from mild to serious complications. Even though rare, this disorder should be recognized, examined and treated appropriately to avoid complications.

References

- [1] M.J. Ramdass, S.Kamal, A.Paice and B.Andrews, "Traumatic diaphragmatic herniation presenting as a delayed tension faecopneumothorax," Emergency medicine Journal volume 23, no.10, p. e 54, 2006.
- [2] Rout. S, Foo F J, Hayden JD, Guthrie A, Smith AM, : RT sided Bochdalek hernia obstructing in an adult : case report and review of literature. *Hernia* 2007, 11 : 359- 362.
- [3] Kanazawa A, Yoshioka Y, Inoi O, Murase J, Kinoshita H: Acute respiratory failure caused by an incarcerated right sided adult Bochdalek hernia: report of a case. *Surg today* 2002, 32:812-815.
- [4] Kocakusak A, Arıkan S, Senturk O, Yeel AF : Bochdalek 's hernia in an adult with colon necrosis. *Hernia* 2005, 9:284-287
- [5] Niwa T, Nakamura A, Kato T, Kutsuna.T, Tonegawa K, Kawai A, Itoh M : An adult case of Bochdalek hernia complicated with hemothorax. *Respiration* 2003, 70: 644-646.
- [6] Hight D.W., Hixson,S.D.,Reed. J.O., Watts. F.B., and Hertzler ,J.H.: Intermittent diaphragmatic hernia of Bochdalek : Report of case and literature review. *Pediatrics* 1982, 69,601-604
- [7] Mac Donald, J.T Abbot, A.C. and Goodhand, T.M. Herniation through congenital diaphragmatic defects in adults. *Can J surg* 1963, 6: 301-316.
- [8] Day, B. Later appearance of Bochdalek hernia. *Br Med J* 1972, 1:786.
- [9] S.Thomas and B.Kapur, "Adult Bochdalek hernia- clinical features, management and results of treatment," *Japanese Journal of Surgery*, vol 21 ,no 1 pp. 114-119,1991.