

## Dandy Walker Syndrome in 5<sup>th</sup> Decade of Life Case Report

Dr. Rajeev Kumar Singh, Dr. Mridul Shahi, Dr. A.N. Mhaske.

People's College Of Medical Science & Research Center, Bhopal(M.P) India.

**Abstract:** DWS is hydrocephalus associated with a posterior fossa cyst and dysgenesis of the cerebellum. In USA the incidence of DWS is thought to be between 1 in 25000 – 35000, live births. This is a case of middle aged male patient with large head since birth, which was asymptomatic till 57 yrs of age. After LOC and CT scan he was diagnosed to have DWS. This case was successfully managed with conservative management plan.

**Keywords** Large head, Computerized tomography, Ventricular peritoneal shunt, hydrocephalus

### I. Introduction:

The Dandy–Walker syndrome (DWS), or Dandy–Walker complex hydrocephalus associated with a posterior fossa cyst and dysgenesis of cerebellum, is relatively uncommon but intervene in its teratogenic and therapeutic implication 1<sup>st</sup> clinical description was published by Dandy and Blackfan in 1914. The pathogenic theory of atresia at the foramina of Luschka and Magendie was introduced at that time and was later elaborated by Taggart and Walker. A second theory was proposed by Benda who believed that the syndrome represented maldevelopment in the region of the fourth ventricle but not limited to the foramina.

The Diagnosis depends on radiological investigations, and three main features of DWS which are Bilateral cerebellar hypoplasia or agenesis, posterior fossa cyst, hydrocephalus. Till date only few cases has been reported in literature. (*J.neurosurg.2006 mar; 104(3suppl)206-9*). In USA the incidence of DWS is thought to be between 1 in 25000 – 35000, live births.

This is a description of a middle aged man with large head , that was unnoticed by him or his family until patient had loss of consciousness and computerized tomography scan revealed a surprising finding. The findings and its clinic relevance has been discussed in this case study.

### II. Case presentation:

A 58 year old male patient, was admitted in 1<sup>st</sup> week of November 2012 in private hospital at Chhattisgarh , with history of fall in bathroom followed by loss of consciousness for an hour. This patient was managed as per ABCD Guidelines and found to be hemodynamically stable. Patient was referred for plain CT scan head (Figure 1).

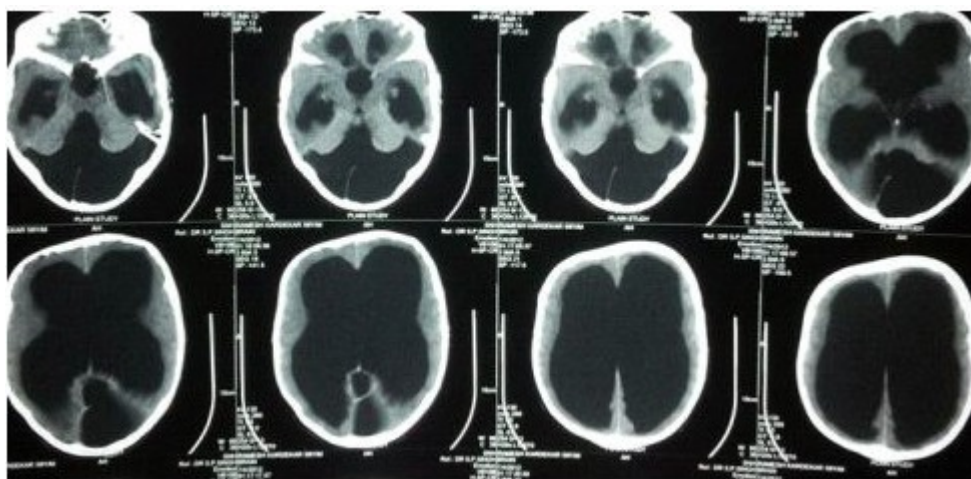


Figure 1

CT scan report showed grossly hydrocephalus and posterior fossa cyst and dysgenesis of cerebellum. Neurosurgical intervene was done for hydrocephalus. V-P shunting was done thinking that hydrocephalus is cause for neurological problem, but it didn't solved problem. His attendants reported a few days of improvement of sensorium following the surgery but soon after that the patient passed again into a coma, following which patient went on ventilator and developed ventilator associated respiratory complication. Patient underwent Tracheostomy and he was referred to our hospital in the last week of November 2012 with V-P shut in situ with tracheostomy, with foley's catheter with complain of insomnia, breathlessness. He was in comatose state since

15 days and in our center he slowly regained consciousness over a few days of conservative management followed by improvement in his cognitive and motor skills within one week, he was able to sit, recognize and talk to his family members. Repeat CT scan was advised which showed VP shunt in situ bilateral subdural effusion frontoparietal, no decrease in ventriculomegaly position. CT scan was suggestive of Dandy Walker Syndrome with craniomegaly.

Patient was asymptomatic till the age of 57 years with preminimally thin cortex mental. He lived his normal life like any normal person of his age. He had bout of stroke which was probably cause of his unconsciousness. Surgery was advised for bilateral subdural effusion but patient attendant refused. The patient gradually improved on conservative management. Body compensated for his normal life till the age of 57 years. Patient was again readmitted after a month with continuous partial seizure which was later well controlled on antiepileptic drugs.

His mother and wife informed us that patient had a big head since childhood (figure 2) but was completely normal otherwise and worked as a clerk in an office.

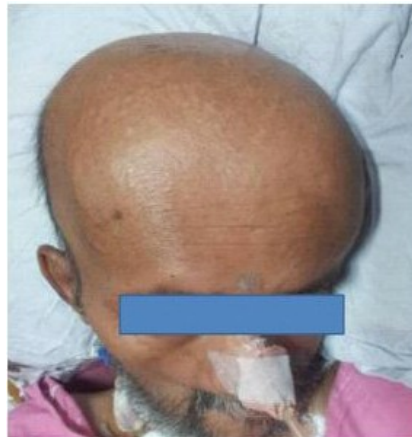

Figure 2

He had never been noticed to have a difficulty in walking or doing any other work with his hands. He has 2 children who are completely normal.

Although it was interesting to think that he had lived his 58 years of life with that strikingly less amount of brain tissue accidentally noticed for the first time we found that such a phenomenon had been reported earlier in the literature ( "Man Live Normal Life",2007)

Since the past 1 year the patient's wife related that he had 3 previous episodes of sudden fall that was interpreted by us as transient ischemic attacks. He has Diabetes and Hypertension since 12 years and was fairly controlled on medications.

### III. Discussion-

In addition to the large dilated ventricles in a thin layer of cerebral cortices (massive ventriculomegaly) along with increase of the cisterna magna and defect of the cerebellar vermis with a communication of the cyst with the fourth ventricle in his first CT head which was suggestive of the Dandy Walker syndrome, his postoperative CT head scan showed evidence of bilateral subdural hematoma along with the Ventriculo peritoneal shunt in situ. (figure 3)

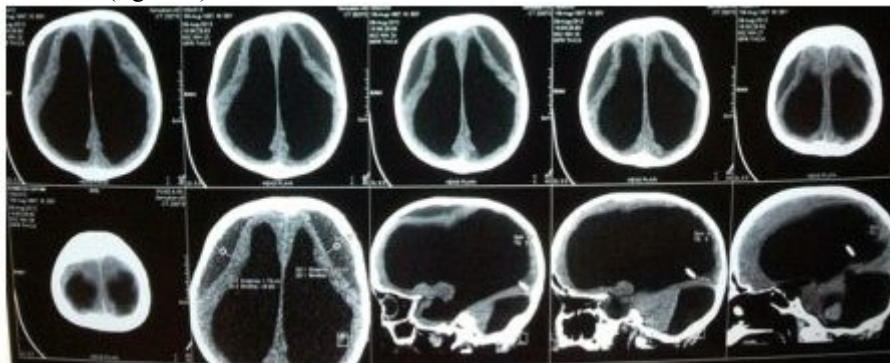


Figure 3

Our final impression was stroke in a patient of preexisting but asymptomatic Dandy Walker syndrome. Most of the patients with Dandy Walker syndrome, signs and symptoms caused by abnormal brain development appear within the first year of life with hydrocephalus that causes macrocephaly. Affected individuals typically

have intellectual disability that ranges from mild to severe and often have delayed development, particularly a delay in motor skills such as crawling, walking and coordinating movements.

People with Dandy Walker syndrome frequently experience muscle stiffness and paralysis of the lower limbs (spastic paraplegia), and they may also have seizures. (Osenbach et al, 1991)

Our patient developed his first syndrome at age of 57 years possibly due to a stroke related to his atherosclerosis risk factors in the form of hypertension and diabetes and unrelated to his congenital malformation. He also underwent a ventriculo- peritoneal shunt and developed acute bilateral subdural hematoma following the decompression which is again well described in the literature. ( Salomao et al 1990)

The Dandy–Walker syndrome (DWS), or Dandy–Walker complex hydrocephalus associated with a posterior fossa cyst and dysgenesis of cerebellum, is relatively uncommon but intervene in its teratogenic and therapeutic implication. 1<sup>st</sup> clinical description was published by Dandy and Blackfan in 1914. The pathogenic theory of atresia at the foramina of Luschka and Magendie was introduced at that time and was later elaborated by Taggart and Walker. A second theory was proposed by Benda who believed that the syndrome represented maldevelopment in the region of the fourth ventricle but not limited to the foramina. The Diagnosis depends on radiological investigations, and three main features of DWS which are Bilateral cerebellar hypoplasia or agenesis, posterior fossa cyst, hydrocephalus. Till date only few cases has been reported in literature. (*J.neurosurg.2006 mar;104(3suppl)206-9*) In USA the incidence of DWS is thought to be between 1 in 25000 – 35000, live births.

Symptoms, which often occur in early infancy, include slower motor development and progressive enlargement of the skull. In older children, symptoms of increased intracranial pressure such as irritability, vomiting and convulsions and signs of cerebellar dysfunction such as unsteadiness and lack of muscle coordination or jerky movements of the eyes may occur. Other symptoms include increased head circumference, bulging at the back of the skull, problems with the nerves that control the eyes, face and neck, and abnormal breathing patterns. Dandy–Walker syndrome is frequently associated with disorders of other areas of the central nervous system including absence of the corpus callosum, the bundle of axons connecting the two cerebral hemispheres, and malformations of the heart, face, limbs, fingers and toes

The DWS malformation is the most severe presentation of the syndrome. The posterior fossa is enlarged and the tentorium is in high position. There is partial or complete agenesis of the cerebellar vermis. There is also cystic dilation of the fourth ventricle, which fills the posterior fossa. This often involves hydrocephalus and complications due to associated genetic conditions, such as Spina Bifida.

The third type is the variant, which is less severe than the malformation. This form (or forms) represents the most wide-ranging set of symptoms and outcomes of DWS. Many patients who do not fit into the two other categories of DWS are often labeled as variant. The fourth ventricle is only mildly enlarged and there is mild enlargement of the posterior fossa. The cerebellar vermis is hypoplastic and has a variably sized cyst space. This is caused by open communication of the posteroinferior fourth ventricle and the cisterna magna through the enlarged valleculla. Patients exhibit hydrocephalus in 25% of cases and supratentorial CNS variances are uncommon, only present in 20% of cases. There is no torculolambdoid inversion, as usually seen in patients with the malformation. The third and lateral ventricles as well as the brain stem are normal.

#### Treatment

Treatment of the dandy walker syndrome has undergone evolutionary change since the entity was originally recognized, and even today there is no universal agreement regarding its management.

The most disheartening aspect of DWS is the long term results

Treatment for individuals with Dandy–Walker Syndrome generally consists of treating the associated problems, if needed.

A special tube (shunt) to reduce intracranial pressure may be placed inside the skull to control swelling.

Endoscopic third ventriculostomy is also an option.

Treatment may also consist of various therapies such as occupational therapy, physiotherapy, speech therapy or specialized education. Services of an ophthalmologist may be helpful if the eyes are affected.

#### **IV. Conclusion**

This is the first reported case of DWS in a male middle aged person who has lived for 58 years without any clinical features of this ailment, and this case has been successfully managed, with the help of conservative approach, which itself is a rare occurrence. This patient had very thin cortex for almost 58 years and there was no symptoms or signs observed during his 58 years of life, which is very rare. The Diagnosis depends on radiological investigations, and three main features of DWS which are Bilateral cerebellar hypoplasia or agenesis, posterior fossa cyst, hydrocephalus. Patient didn't require VP shunt if there was no raise in intracranial pressure. Dandy walker syndrome is not limited to a mechanical disturbance of CSF circulation but rather represents a more generalized disorder of neural development.

**References:**

- [1]. "Man Lives Normal Life Despite Having Abnormal Brain" the globe and mail. July 19, 2007. Archived from the original on august 28, 2007.
- [2]. [http:// web archive. Org/ web/ 20070828013153/ http://www.theglobeandmail.com/servlet/ story/ RTGAM20070719.wbrainn 0719/BNSStory/Science/home](http://web.archive.org/web/20070828013153/http://www.theglobeandmail.com/servlet/story/RTGAM20070719.wbrainn0719/BNSStory/Science/home) Retrived July 15, 2012.
- [3]. Osenbach R.K.Menezes A.H (1991) Diagnosis and Management of the Dandy Walker malformation: 30 years of experience. *Pediatr Nurosurg* 18: 179-185.
- [4]. Salomao J.F, Leibinger R.D. Lima Y.M Servico de. (1990) "Chronic subdural hematoma as a complication of ventriculoperitoneal shunts. [www.ncbi.nlm.nih.gov/pmed/ 2260956](http://www.ncbi.nlm.nih.gov/pmed/2260956)
- [5]. National Institute of Neurological Disorders and Stroke, "NINDS Dandy-Walker Syndrome Information Page," <http://www.ninds.nih.gov/disorders/dandywalker/dandywalker.htm>. Last updated September 16, 2008. Last accessed July 6, 2009.
- [6]. Osenbach RK, Menezes AH (1992). "Diagnosis and management of the Dandy-Walker malformation: 30 years of experience." *Pediatr Neurosurg* 18 (4): 179-89.
- [7]. Guibaud L, Larroque A, Ville D, Sanlaville D, Till M, Gaucherand P et al. (2012). "Prenatal diagnosis of 'isolated' Dandy-Walker malformation: imaging findings and prenatal counselling."
- [8]. Romero R, Pilu G, Jeanty P, Ghidini A, Hobbins JL. Prenatal diagnosis of congenital anomalies. Appleton & Lange, Norwalk, 1988, pp. 30-33.
- [9]. Kaplan LC (Dec 1985). "Congenital Dandy Walker malformation associated with first trimester warfarin: A case report and literature review". *Teratology* 32 (3): 333-337.
- [10]. [http://www.jneurosurj.2006 mar;104\(3suppl\)206-9](http://www.jneurosurj.2006.mar;104(3suppl)206-9)
- [11]. Benda CE. The Dandy- Walker syndrome or the so called atresia of the foramen Magendie. *J Neuropathol Exp Neurol* 1954; 13:14-29.
- [12]. Dandy WE, Blackfan KD. Internal hydrocephalus; an experimental clinical and pathological study. *AmJ Dis Child* 1914; 8:406-482.
- [13]. Fischer EG, Dandy Walker syndrome: an evaluation of surgical treatment. *J Neurosurg* 1973; 39: 615-621.
- [14]. Taggart JK JR. Walker AE. Congenital atresia of the foramina of Luschka and Magendie. *Arch Neurol Psychiatry* 1942; 48:583-612.
- [15]. Altman Nr. Maidich TP Braffman BH. Posterior fossa malformations. *Am J Neuroradiol* 1992; 13:691-724.