

Mucoepidermoid carcinoma of lacrimal sac

Dr. A. Venkateshwaran¹, Dr. S. Jaiganesh², Dr. S. Yousuf³, Dr. V. Ashwin⁴

¹(Assistant professor, Department of radiodiagnosis, Meenakshi medical college, Meenakshi university, India)

²(Assistant professor, Department of radiodiagnosis, Meenakshi medical college, Meenakshi university, India)

³(Post graduate, Department of radiodiagnosis, Meenakshi medical college, Meenakshi university, India)

⁴(Post graduate, Department of radiodiagnosis, Meenakshi medical college, Meenakshi university, India)

Abstract: Lacrimal sac is the closed upper end of the nasolacrimal duct and has a fibro-elastic wall lined internally by mucosa that is continuous with the conjunctiva through the lacrimal canaliculi and within the nasal mucosa through the nasolacrimal duct. Primary lacrimal sac tumors are rare compared to other orbital tumors. Mucoepidermoid carcinoma is a tumor that contains both neoplastic mucin producing and epidermoid cells. Mucoepidermoid carcinoma of the LS is very rare. Early treatment of these tumors is essential because they tend to be infiltrating tumors. Multiplanar CT imaging of the paranasal sinuses and orbit is essential for defining the extent of the tumor and for finding evidence of bony destruction of the lacrimal fossa.

Keywords: Lacrimal sac, Mucoepidermoid carcinoma, CT

I. Introduction

Lacrimal sac is the closed upper end of the nasolacrimal duct and has a fibro-elastic wall lined internally by mucosa that is continuous with the conjunctiva through the lacrimal canaliculi and within the nasal mucosa through the nasolacrimal duct (1). Primary lacrimal sac tumors are rare compared to other orbital tumors. Early treatment of these tumors is essential because they tend to be infiltrating tumors.

II. Case report

A 76-year-old male came with complaints of swelling in right orbit for 8 months and discharge from the same site for 6 months. Swelling was gradual in onset, increasing in nature and painless. Discharge was watery and sticky in nature. H/O blurring of vision was present. On examination eyeball was pushed laterally with congested conjunctiva. No evidence of corneal ulcer.

CT orbit was done in both coronal and axial views show an ill defined soft tissue density lesion (fig1) involving the medial aspect of the right orbit and is adherent to the medial rectus muscle. Following intravenous contrast administration the mass lesion enhances moderately (fig4). There is erosion of the right lacrimal and ethmoid bone (fig2) with extension of the mass into the ethmoid sinuses and maxillary ostium (fig1). The mass is seen to cause mass effect on the optic nerve (fig3) and the right globe displacing it laterally (fig3,4). The superior orbital fissure and optic canal are normal. However, there is no evidence of intracranial extension of the mass lesion, our final conclusion was a metastasis deposit and suggested biopsy for further evaluation.

So the patient underwent biopsy and turned out to be mucoepidermoid carcinoma and is currently under preoperative radiotherapy.

III. Discussion

Lacrimal sac tumors are malignant in 55% of cases with a distinction made between epithelial and non epithelial tumors. Epithelial tumors account for more than two-thirds of all malignant tumors of the lacrimal sac. (2) The most frequent malignant lesions of the LS are squamous and transitional cell carcinoma: the less common types are adenocarcinoma, oncocytic adenocarcinoma, adenoid cystic carcinoma and mucoepidermoid poorly differentiated carcinoma. (3,4,5) Non epithelial LS tumors include mesenchymal lesions (fibrous histiocytoma, fibroma, hemangioma, angiosarcoma and lipoma), lymphoid lesions. Malignant melanoma, granulocytic sarcoma and neuronal tumors.

The mucoepidermoid carcinoma is the salivary glands most frequent malignant tumor and it affects the major and minor salivary glands (6, 7). It's the most common malignant tumor in the parotid (60-70% cases) (6, 7). Its origin is the epithelium of the glandular excreting duct, and it may also develop in the nasal cavity minor salivary glands, maxillary sinuses, nasopharynx, oropharynx, larynx, vocal cords, trachea, lungs and lacrimal glands (6, 8, 9).

Mucoepidermoid carcinoma is a tumor that contains both neoplastic mucin producing and epidermoid cells. (10). Mucoepidermoid carcinoma of the LS is very rare. Ni et al (11) postulate that it may arise from either

the LS wall serous gland epithelium or the columnar epithelium of the conjunctiva, with its goblet cells. The first case of MEC arising in the LS was described in Brazil in 1981 by Bambirra et al (12)

An LS biopsy is the most important tool (13), biopsies are performed either to establish the diagnosis of a suspicious mass or to identify an abnormal lesion seen in the LS mucosa during DCR (14). The diagnosis of MEC typically requires the coexistence of 3 cell types: epidermoid, intermediate and mucin secreting cells. (15) Multiplanar CT imaging of the paranasal sinuses and orbit is essential for defining the extent of the tumor and for finding evidence of bony destruction of the lacrimal fossa (16). Magnetic resonance imaging is useful for distinguishing the lesion from adjacent retained secretions, hypertrophic inflammatory mucosa and adipose tissues (17)

The treatment of LS tumors is often multidisciplinary and modalities can include surgery, chemotherapy, immunotherapy, and radiotherapy, depending of the histologic type and anatomic extent of the tumor (14) most patients underwent exenteration with postoperative radiation therapy when the soft tissue margins were positive for tumor infiltration. (11,12)

The old age of our patient argued in favor of preoperative radiation to reduce the mass, followed by wide resection of the tumor

IV. Conclusion

MEC of the lacrimal sac is challenging in early diagnosis as it mimics dacryocystitis and need to be detected as early as it is an infiltrating tumor, CT is an essential tool in diagnosis the lesion and extent of it.

References

- [1]. Montalban A, Lietin B, Lourier C, Russies M, Kemeny JL, Mom T, Gilam L, malignant lacrimal sac tumours. Eur AM otorhinolaryngol Head neck Dis 2010;127:165-172
- [2]. Stefanyszyn MA, Hidayat AA, Peer JJ, et al, lacrimal sac tumors. Ophthal Plast Reconstr Surg 1994;3:169-184
- [3]. Parmar DN, Rose GE. Management of lacrimal sac tumours. Eye 2003;7:599-606
- [4]. Stefanyszyn MA, Hidayat AA, Pe'er JJ, et al. Lacrimal sac tumors. Ophthal Plast Reconstr Surg 1994;10:169-184
- [5]. Flanagan JC, Stokes DP. Lacrimal sac tumours. Ophthalmology 1978;85:1282-1287
- [6]. Pires FR, Alves FA, Almeida OP, Kowalski LP. Carcinoma mucoepidermóide de cabeça e pescoço: estudo clínico-patológico de 173 casos. Rev Bras Otorrinolaringol. 2002, 68(5):679-84.
- [7]. Devita VT, Hellman S, Rosenberg SA. Cancer of the Head and Neck. In: Cancer - Principles & Practice of Oncology, 5th ed. Philadelphia: Lippincott-Raven Publishers; 1997, p. 833.
- [8]. Salazar CM, Saa J, Sánchez-Jara MR, García JL, González M. Carcinoma mucoepidermóide de vestíbulo nasal. Acta Otorrinolaring Esp. 2000, 51(7):729-32.
- [9]. Thomas GR, Regalado JJ, McClinton M. A rare case of mucoepidermóide carcinoma of the nasal cavity. Ear Nose Throat J. 2002, 81(8):519-22.
- [10]. Blake J, Mullaney J, Gillan J. Lacrimal sac mucoepidermoid carcinoma. Br J Ophthalmol 1986;70:681-685
- [11]. Ni C, Wagoner MD, Wang WJ, et al. Mucoepidermoid carcinomas of the lacrimal sac. Arch Ophthalmol 1983;101:1572-1574
- [12]. Bambirra EA, Miranda D, Rayes A. Mucoepidermoid of the lacrimal sac. Arch Ophthalmol 1981;99:2149-2150
- [13]. Altan-Yaycioglu R, Bolat F, Akova YA. Basosquamous carcinoma of the lacrimal sac: a case report. Orbit 2007;26:267-269
- [14]. Valenzuela AA, McNab AA, Selva D, et al. Clinical features and management of tumors affecting the lacrimal drainage apparatus. Ophthal Plast Reconstr Surg 2006;22:96-101
- [15]. Fliss DM, Freeman JL, Hurwitz JJ, et al. Mucoepidermoid carcinoma of the lacrimal sac: a report of two cases, with observations on the histogenesis. Can J Ophthalmol 1993;28:228-235
- [16]. Salib RJ, Afoakwah EO. De novo papillary squamous carcinoma of the lacrimal sac. Auris Nasus Larynx 2003;30:205-208
- [17]. Sakaida H, Kobayashi M, Yuta A, et al. Squamous cell carcinoma of the nasolacrimal duct. Eur Arch Otorhinolaryngol 2009;266:455-458

Figures

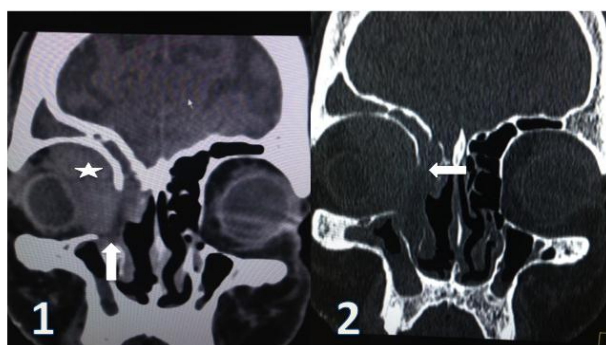

Fig1- Coronal CT section (soft tissue window) of the orbit shows a soft tissue density lesion (marked by star) on the medial aspect of right orbit in the region of lacrimal sac and medial rectus muscle and seen extending up to inferior nasal cavity and maxillary ostium (marked by block white arrow)

Fig2- Coronal CT section (bone window) of the orbit shows the destruction of medial wall of right orbit (marked by white block arrow)

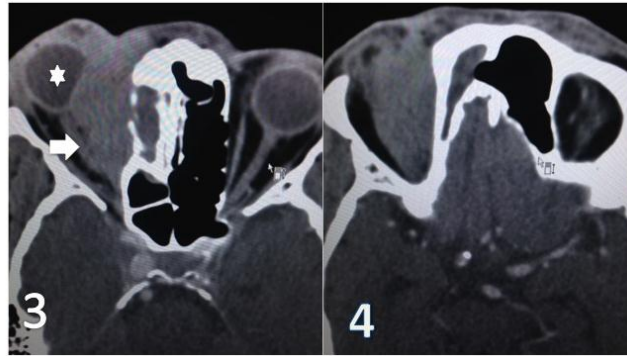


Fig 3- Axial contrast enhanced CT sections shows the moderately enhancing lesion causing compression on the right globe and optic nerve (marked by white block arrow)

Fig4-Axial contrast enhanced CT sections show the lesion, which appears predominately extraconal.