

## Resin bonded bridge: A forgotten first frontier for an aesthetically critical edentulous space- A case report

Dr Rahul Vishnoi<sup>1</sup>, Dr Anand Bele<sup>2</sup>, Dr Deshraj Jain<sup>3</sup>

<sup>1</sup>(MDS, Department of Prosthodontics, Government College of Dentistry, Indore, India)

<sup>2</sup>(Assistant Professor, Department of Prosthodontics, Government College of Dentistry, Indore, India)

<sup>3</sup>(Professor, Department of Prosthodontics, Government College of Dentistry, Indore, India)

---

**Abstract:** Introduction and the succeeding acceptance and popularity of implants has made the choice of other restoration options a little less common. The resin bonded bridges, though an excellent alternative to less conservative procedure like complete coverage fixed bridges and economically dearer choice like implant, are still not embraced by the common dentist. However, in circumstances of a proper case selection and financial limitations on the part of the patient, the use of resin bonded bridge should not be avoided. The missing anterior tooth in young patients who cannot afford a more expensive option of implant has so far been the most ideal case choice for these prostheses. This article explains the restoration of a missing, maxillary right central incisor in a young male with open bite, using resin bonded bridge.

**Keywords:** cantilever, etching, implant, resin-bonded bridge

**Abbreviations:** RBB- Resin-bonded bridge; FPD- Fixed Partial Denture; RPD- Removable Partial Denture; IOPAR-Intra oral periapical radiograph

---

### I. Introduction

Resin bonded bridges (RBBs) are minimally invasive fixed prostheses which employ composite resin cements for retention. These restorations were first introduced in the 1970s and since then, multiple modifications have been done to improve them. [1]

Buonocore [2] in 1955 introduced bonding to dentistry and thus heralded new possibilities in the restoration procedures. Adhesive technology means that more conservative preparation of the abutment teeth is possible in comparison to conventional restorations.

In 1973, Rochette [3] introduced the concept of bonding a metal retainer to enamel by adhesive resin. However, his application was to splint periodontally involved mandibular anterior teeth using a cast gold bar bonded to the lingual surfaces of the teeth.

Howe and Denehy [4] used this technique to introduce the first form of RBB which became popular as the 'Rochettebridge'. Livaditis [5] proposed abutment preparation, including reduction of proximal and lingual surfaces to create a path of insertion, along with occlusal rest seat preparation to resist tissueward displacement of the retainer.

Livaditis and Thompson [6] of Maryland university in 1982 pioneered the concept of electrolytically etching a non-precious metal to microscopically roughen the metal surface, introducing Maryland bridge.

In contrast to the micro-mechanical retention employed by Maryland Bridge, Moon and Hudgins et al of Virginia Commonwealth University School of Dentistry developed "Virginia Bridge" which had visible macroscopic mechanical undercuts on the inner surface of retainers. It is fabricated by "lost salt crystal" technique using 150-250 um sized salt crystals [7].

Because of the impracticality of the etching technique, airborne particle abrasion with 50 um aluminium oxide was proposed as a more practical alternative to increase surface roughness. The equipment required is inexpensive and the surface details can be appreciated without the use of microscope (required in electrochemical etching)[8].

The resin systems like Super-Bond and Panavia have also been developed to facilitate the direct bonding of metal.

So many modifications have been done and techniques have been introduced to the concept of RBB that sometimes it is perplexing to choose this restorative option even when the case selection is appropriate for the same. This article explains an ideal case choice for the RBB over implant and conventional FPD; and the method in detail along with the modifications in tooth preparations.

## **II. Case-Report**

A 17 year old male patient reported to the post-graduate department of Government Dental College, Indore with a chief complaint of missing right, maxillary central incisor and desired it to be replaced as soon as possible (Fig. 1). He gave a history of trauma (a blow to the tooth) as the cause of loss of tooth. His medical history was non-contributory.

After taking the relevant radiographs and the diagnostic models, patient's treatment plan was discussed.

### **1.1 Treatment-options-**

1.1.1 Removable partial denture- RPD was ruled out as neither the patient wanted a removable prosthesis nor was the Prosthodontist convinced to give an RPD for a single missing tooth. Moreover, the tooth of interest was aesthetically critical and a conventional RPD would not be a suitable treatment option.

1.1.2 Fixed Partial Denture- A conventional full-coverage FPD was out of the question as the IOPAR of the patient demonstrated large pulp cavity; so the FPD would not be feasible (Fig. 2).

1.1.3 Implant- Considering the age of the patient and the location of the edentulous space, an implant was a good option but the patient could not afford it. Hence, it was also ruled out.

1.1.4 Resin Bonded Bridge- This was the most suitable treatment option, by the point of views of both, the Prosthodontist and the patient. Economically sound and conservative of a vital tooth of a young patient, an RBB was the most feasible prosthesis for this case. Also, the patient had minor anterior open bite which is considered an ideal indication for RBB. There would be no anterior centric occlusal contacts which could otherwise create harmful forces at ceramo-metal junction. (Patient was unwilling for an orthodontic consultation as the open bite did not affect the facial aesthetics)

### **1.2 Cantilever or not?**

As the missing tooth was a maxillary central incisor, the root surface area of which is larger than the maxillary lateral incisor; the cantilever prosthesis supported by the lateral incisor would not be able to bear the moment of force generated when masticatory and parafunctional forces would have come into play. Hence a three unit RBB involving right, maxillary lateral incisor and left, maxillary central incisor was planned.

### **1.3 Abutment Preparation**

Because the dentition displayed an anterior open bite, there was no need to mark the centric occlusal contacts. An intra-enamel preparation was started on the lingual surface of the right, maxillary lateral incisor with small wheel bur and it was reduced by approximately 0.5 mm. A torpedo bur was used to make a chamfer gingival margin approximately 1 mm incisal to the cemento-enamel junction. The proximal contours were reduced to allow a path of insertion and increase the tooth surface area for bonding. The facial extension of the proximal tooth preparation was done just slightly lingual to the facial line angles. Bilaterally, proximal grooves were made. A notch was prepared in cingulum with a flat end tapered bur, which served as an occlusal step. The tooth preparation was stopped 2mm short of the incisal edge to avoid the visibility of unaesthetic metal.

The same preparation was repeated on the maxillary, left central incisor (Fig. 3).

Although a provisional restoration is not absolutely essential in RBB, a temporary restoration was fabricated as the patient requested for the same.

### **1.4 Framework design**

After properly isolating both the abutments with cotton rolls and suction-tip, impression was made (Fig. 4) using two-step putty wash technique with putty and light body addition silicone [Aquasil LV, Dentsply, Mumbai, India]. Impression was poured in type V Dental stone that is, die stone [Kalrock, Kalabhai, Mumbai, India]. The cast was retrieved and the wax pattern for the RBB was fabricated (Fig. 5) with crown wax [Kronenwachs, Bego, Germany] and modelling wax [Y-Dent, MDM Corporation, New Delhi, India].

Following investing, the wax pattern was cast in Ni-Cr alloy [NDN, Germany]. After finishing and polishing of the framework, its intra-oral trial was done (Fig. 6). Ceramic was applied on the pontic and subsequently, the sandblasting of the tissue-surface was done with 50um aluminium oxide. This facilitated the formation of micromechanical patterns which help in the subsequent resin tag formation.

### **1.5 Cementation**

A meticulous salivary control was achieved by using suction-tips and cotton-rolls. Rubber dam application is not always practically feasible as it may cover the margin or cause saliva pooling in the area. Following the manufacturer's instructions, first the enamel was conditioned using the resin cement [Panavia21, Kuraray, Japan] followed by the cementation of the framework (Fig. 7).

Patient was given post-op instructions and was asked to report for a follow-up appointment after 24 hours.

He was satisfied with the aesthetic results of the final restoration (Fig. 8).

### III. Discussion

Three fundamental principles should be followed to get optimum results with RBB- proper patient selection, correct enamel modification, and framework design [9]

The present case fulfilled all the three above requirements. It was an apt choice for RBB as the patient had open bite which is an ideal requirement for the same; the enamel modification had been done keeping in mind the required retention and resistance form and the framework had been designed after considering the possible undercuts and the path of insertion of the restoration.

According to author, a fourth fundamental principal should be the meticulous cementation. Due to frequent debonding in such cases, the cementation should be done carefully as this step is highly technique-sensitive.

RBB presents with many obvious pros like non-invasive preparation, no anesthesia needed, supragingival margins which are not deleterious for periodontium, less time-consuming, rebonding possible without any warpage or breakage, no need for provisional restorations in maximum cases; however, its longevity is still questionable as decementation is frequent and it does not correct alignment [10]

RBB has also come forward as a temporary restoration in cases of anterior implants [11].

However, RBB is still a wonderful treatment option in developing nations like India where a major part of the population consists of youngsters; and an average patient visiting a dentist is economically not well to-do to afford an elite restorative option like implant. In such a case-scenario, RBB should be the first frontier for an edentulous space that is also aesthetically critical.

Also, RBB fulfills the most fundamental principal of dentistry-MM Devan's dictum. "It is perpetual preservation of what already exists is important and not the meticulous replacement of what is missing" [12]

### IV. Conclusion

This article explains the need of realizing the importance of RBB in rehabilitation of missing anterior teeth when other prosthodontic options are either not cost effective or are radically invasive for the otherwise sound tooth structure.

### Acknowledgement

The authors are grateful to Mr. VK Tripathi for his contribution in the laboratory work.

### Figure Legends

**Fig. 1-**Missing maxillary right central incisor, an aesthetically critical edentulous space.

**Fig. 2-**Radiograph depicting a large pulpal cavity in a young patient, a contra-indication for complete coverage FPD.

**Fig. 3-**Intra-enamel preparation for RBD.

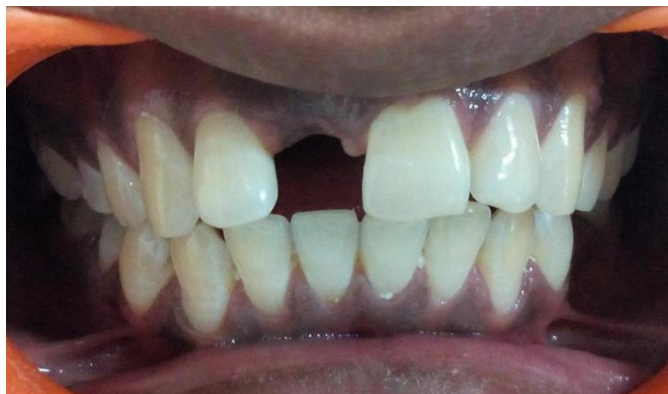**Fig. 4-**Silicon impression for better recording of detail.

**Fig. 5-**Wax pattern for the RBD.

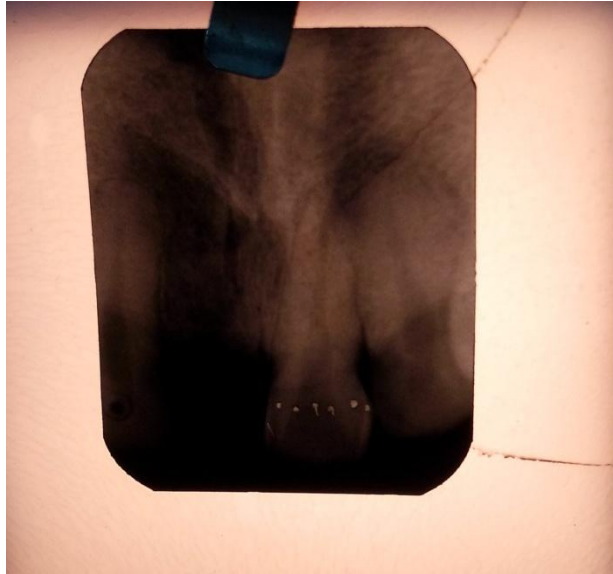**Fig. 6-** Framework trial.

**Fig. 7-**RBB cemented; Notice the anterior open bite in the patient.

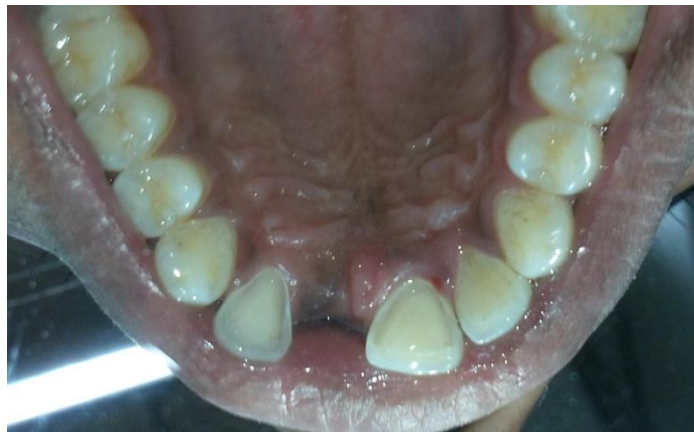**Fig. 8-**The patient satisfied with aesthetic results of the RBD.



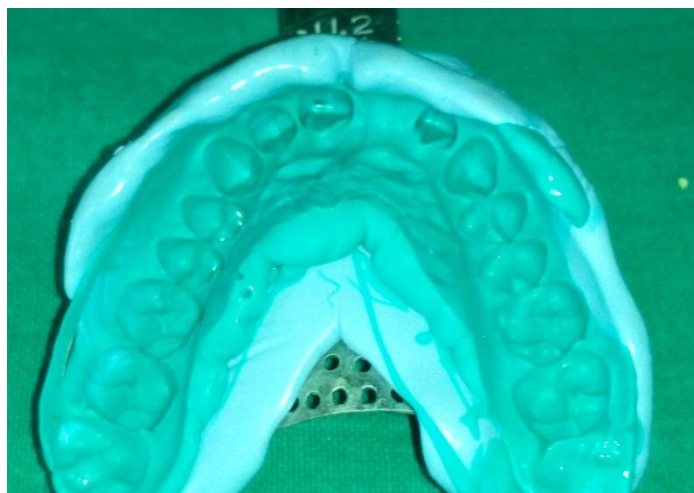
**Fig. 1-**Missing maxillary right central incisor, an aesthetically critical edentulous space.



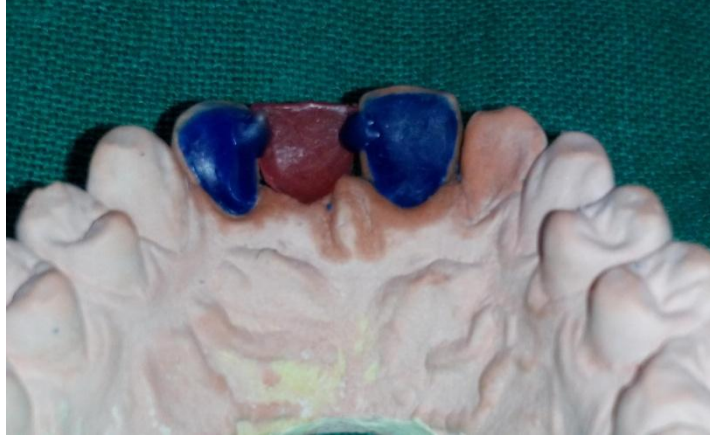**Fig. 2-**Radiograph depicting a large pulp cavity in a young patient, a contra-indication for complete coverage FPD.



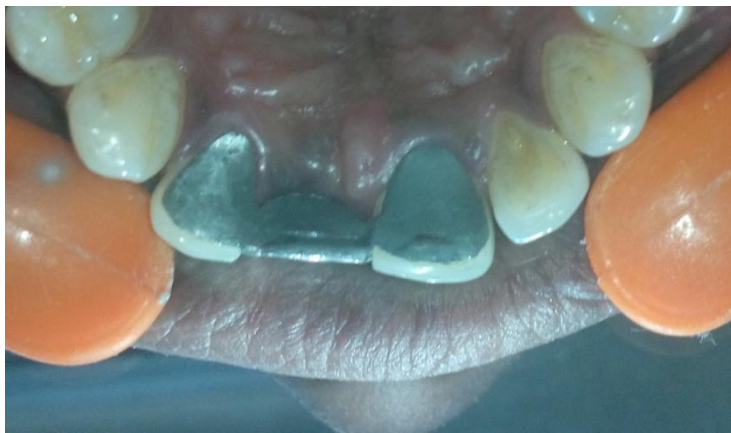**Fig. 3-**Intra-enamel preparation for RBD.



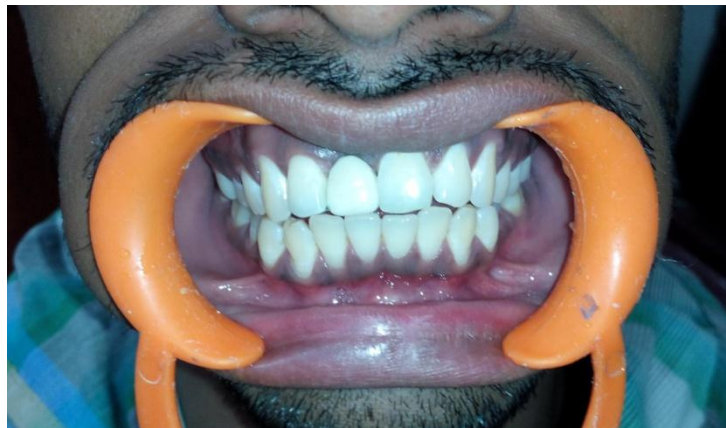**Fig. 4-**Silicon impression for better recording of detail.



**Fig. 5-**Wax pattern for the RBD.



**Fig. 6-** Framework trial.



**Fig. 7-**RBB cemented; Notice the anterior open bite in the patient.



**Fig. 8-**The patient satisfied with aesthetic results of the RBD.

### References

- [1]. K. A. Durey, P. J. Nixon, S. Robinson and M. F. W.-Y. Chan, Resin bonded bridges: techniques for success, *British Dental Journal* 211 (3), 2011, 113-118.
- [2]. Buonocore, M.G., A simple method of increasing the adhesion of acrylicfilling materials to enamel surfaces. *J Dent Res*, 34, 1955, 849-853.
- [3]. Rochette, A.L., Attachment of a splint to enamel of lower anterior teeth, *J Prosthet Dent*, 30,1973, 418-423.
- [4]. Howe, D.F., Denehy, G.E., Anterior fixed partial dentures utilising the acidetchtechnique and a cast metal framework, *J Prosthet Dent*, 37, 1977, 28-31.
- [5]. Livaditis, G.J., Cast metal resin-bonded retainers for posterior teeth, *J Am Dent Assoc*, 101, 1980, 926-929.
- [6]. Livaditis, G.J., Thompson, V.P., Etched castings: an improved retentive mechanism for resin-bonded retainers, *J Prosthet Dent*, 47, 1982, 52-58.
- [7]. Hudgins JL, Moon PC, Knap FJ, Particle-roughened resin-bonded retainers, *J Prosthet Dent*, 53, 1985, 471-476.
- [8]. Una Lally, Resin-bonded fixed partial dentures past and present – an overview, *Journal of the Irish Dental Association*, 58 (6), 2012-2013, 294 -300.
- [9]. Rosenstiel, Land, Fujimoto, *Contemporary Fixed Prosthodontics* (St Louis, Missouri, Mosby Inc, 2001).
- [10]. Shillingburg, Hobo, Whitsett, Jacobi, *Fundamentals of Fixed Prosthodontics* (Canada, Quintessence Publishing Co, 1997).
- [11]. Carl E. Misch, *Contemporary Implant Dentistry* (St. Louis, Mosby, 1993).
- [12]. M. M. Devan, Basic principles in impression making, *J Prosthet Dent*, 93(6), 2005, 503-508.