

Organophosphorus Insecticide induced Hemorrhagic Pancreatitis – A Case Report

Rajan S¹, Chidananda P S², Bhat V J³, Surangama Chakraborty⁴

^{1,4}Postgraduate, ²Assistant Professor, ³Professor & Head,
Department of Forensic Medicine and Toxicology
Shimoga Institute of Medical Sciences, Karnataka, India

Abstract: Acute pancreatitis is one of the complications of Organophosphorous insecticide (OP) poisoning. It is thought to occur from ductal hypertension and pancreatic parenchymal injury as a result of excessive pancreatic cholinergic stimulation. Pancreatic involvement in OP poisoning may range from enzyme elevation to necrotizing pancreatitis that necessitates surgery. Further OP induced acute pancreatitis is believed to follow a subclinical and uneventful course and the diagnosis of acute pancreatitis can be obscured by the systemic effects of OP toxicity. Hemorrhagic pancreatitis with bleeding within or around pancreas, a sequel of acute pancreatitis, is an uncommon, unusual complication of OP poisoning usually leading to a fatal outcome.

Key words: Organophosphate, Asymptomatic Pancreatitis, Hemorrhagic Pancreatitis, Pancreatic necrosis.

I. Introduction

Organophosphorous compounds are diverse group of chemicals used in domestic and industrial settings. These compounds are the most common mode of poisoning in developing countries due to its easy availability and it is associated with high mortality and morbidity. Organophosphates are powerful inhibitors of carboxylic esterase enzymes, including acetyl cholinesterase and pseudocholinesterase leading to a syndrome of cholinergic excess. OPs also inhibit another enzyme neuropathy target esterase which is an integral membrane protein present in all neurons. This result in Organophosphorous induced delayed neuropathy [1].

Organophosphorous affects all the organ systems in various ways. Some of the complications of OP poisoning are central failure of respiration, myocardial necrosis, risk of kidney cancer in children, delayed polyneuropathies and encephalopathy, fetal death, intrauterine growth restriction, congenital malformations etc [2]. Acute pancreatitis is one of the complications of this poisoning. It is thought to occur from ductal hypertension and pancreatic parenchymal injury as a result of excessive pancreatic cholinergic stimulation [3]. This potentially fatal complication can be overlooked in the absence of typical clinical features of acute pancreatitis. Pancreatic involvement may range from mere enzyme elevations to necrotizing pancreatitis that necessitates surgery. Pancreatitis in OP poisoning is generally benign, although necrosis, pseudo cyst and hemorrhage have been reported [4].

Hemorrhagic pancreatitis characterized by acute inflammation and necrosis of pancreas parenchyma, focal enzyme necrosis of pancreatic fat and vessels necrosis with bleeding within or around pancreas [5], a sequel of acute pancreatitis, is an uncommon complication of OP poisoning and rarely reported in literature. High index of suspicion should be there to diagnose these conditions and to treat them accordingly.

II. Case Report

An elderly male patient aged 45yrs was referred with history of consumption of unknown poison at 08:00pm at his residence. On arrival to hospital at 10:00pm he was afebrile; blood pressure was 130/80 mm Hg and respiratory rate of 17 per minute. As per history He was not a known diabetic, hypertensive, asthmatic or alcoholic.

Serum cholinesterase was 1567 IU at the time of admission and 1044 the following morning. Random blood sugar was 195mg/dl, blood urea - 44mg/dl and Serum creatinine - 2.30 mg/dl. Patient initially showed good clinical response to anti-cholinergic therapy and expired suddenly at 01:30pm the next day. At autopsy body was of an adult male with a body mass index of 20 and showed no demonstrable external injuries. On internal examination lungs were congested and edematous, on cut section frothy fluid exuded, other viscera showed generalized congestion. Gross hemorrhage within and around the pancreas was noted during autopsy (Fig -1 and Fig-2).

Routine Viscera and blood was subjected to toxicological analysis which revealed presence of organ phosphorous insecticide. On histopathology Pancreas showed hemorrhage, inflammatory cells and necrotic acinar cells (Fig-3 and Fig-4).

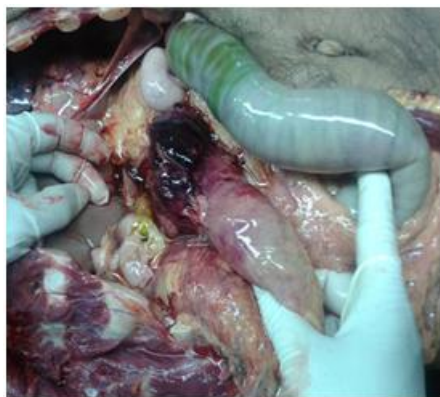

Fig-1

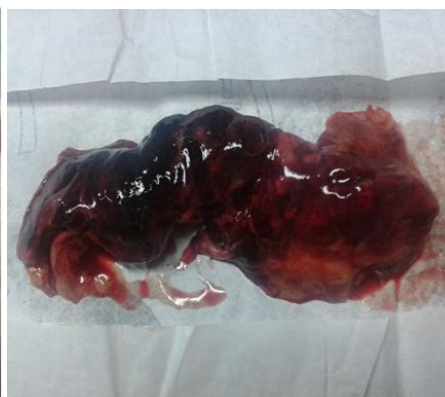

Fig-2

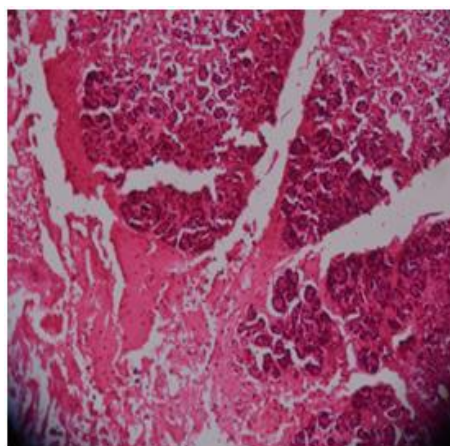


Fig-3

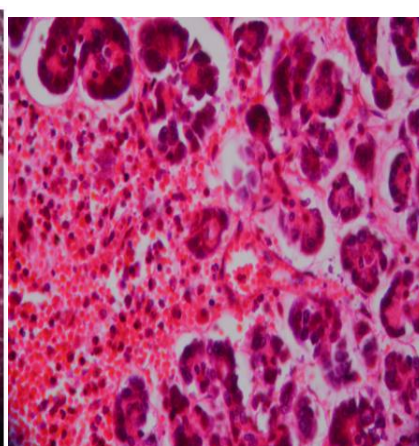


Fig-4

III. Discussion

Acute pancreatitis is comparatively a rare complication in acute OP poisoning; however its severities and clinical course are unclear. Cases with acute pancreatitis as a complication of organophosphate exposure have been reported in the literature.

Studies show the Prevalence of acute pancreatitis range from 0.5% to 62.5% and mortality rates have varied from 5 to 10% [6]. Dagli and shaikh suggested that acute OP could cause mild and transient pancreatitis because the elevated amylase levels return to normal within 3-4days [7]. Zamir DL [8] and panieri, reported severe necrotizing pancreatitis caused by acute OP poisoning.

Martin Rubi, have reported only three patients with pancreatitis in a total number of 506 cases of organophosphate intoxication. This indicates a percentage of 0.59% [9].

Singh. have reported 37 patients in whom serum amylase was found to be elevated out of 79 patients (46.95%). But only one patient was proved to have pancreatitis making a percentage of 1.2% [10]. Sahin, have reported acute pancreatitis in 6 patients among 47 making a percentage of 12.7% [11]. Krupesh, reported hemorrhagic pancreatitis in four patients among 62 making a percentage of 6.4%, two of them died due to pancreatitis [12].

OP induced acute pancreatitis is believed to follow a subclinical and uneventful course Moreover the diagnosis of acute pancreatitis can be obscured by the systemic effects of OP toxicity. Few studies showed that raised amylase level was frequently seen in OP poisoned patients due to cholinergic stimulation to pancreas, but it is the raised lipase level which leads to the suspicion of acute pancreatitis

Though there are few cases of acute pancreatitis as a complication of Organophosphorous poisoning reported in literature. However Hemorrhagic pancreatitis with bleeding within or around pancreas, a sequel of acute pancreatitis very rarely reported in literature. The mortality rate with hemorrhagic pancreatitis is up to 80%. So high index of suspicion should be there to diagnose these conditions and to treat them accordingly.

IV. Conclusion

Acute pancreatitis is a serious complication but rarely noticed, may be it is obscured by the systemic effects of OP Toxicity. Further hemorrhagic pancreatitis which is a fatal condition and an uncommon complication to be seen. Hence it is reported in this article.

References

- [1]. Eddleston M, Clark RF. Insecticides-Organic phosphorus compounds and Carbamates. In: Goldfrank's toxicologic emergencies 9thed. (New York: McGraw Hill; 2011) 1450-57.
- [2]. Kumar SV, Fareedullah M, Sudhakar Y, Venkateswarlu B, Ashok Kumar E. Current review on organophosphorus poisoning. Scholar Research Library, 2 (4), 2010, 199-215
- [3]. Hsiao CT, Yang CC, Deng JF, Bullard MJ, Liaw SJ. Acute pancreatitis following organophosphate intoxication. J Toxicol. 34, 1996, 334-337.
- [4]. E. Panieri, J. E. Krige, P. C. Bornman, D. M. Linton. Severe necrotizing pancreatitis caused by organophosphate poisoning. J Clin Gastroenterol, 25(2), 1997, 463-465.
- [5]. Norton J, Greenberger, Toskes PP. Acute and Chronic Pancreatitis. In: Harrison's Principles of Internal Medicine. 17thed. (New York: McGraw-Hill; 2012) 2005-2017
- [6]. Ahmed A, Begum I, Aquil N, Atif S, Hussain T, Vohra EA. Hyperamylasemia and acute pancreatitis following organophosphate poisoning. Pak J Med Sci. 25(6), 2009, 957-961.
- [7]. Dagli AJ, Shaik WA. Pancreatic involvement in malathion- Anticholinesterase insecticide intoxication- study of 75 cases. Br J. Clin. Prac. 37, 1983, 270-272
- [8]. Zamir DL, Novis BN. Organophosphate poisoning and necrotizing pancreatitis. Isreal. J. Med. Sci. 30, 1994, 855-856.
- [9]. Martin JC, Yelamos RF, Laynez BF. Poisoning caused by organophosphate insecticides. Study of 506 cases. Rev Clin Exp. 196, 1996, 145-49
- [10]. Singh S, Bhardwaj U, Verma SK, Bhalla A, Gill A. Hyperamylasia and acute pancreatitis following anticholinesterase poisoning. Hum Exp Toxicol. 21, 2007, 467-72.
- [11]. Şahin, K. Onbasi, H. Sahin, C. Karakaya, Y. Ustun, and T. Noyan. The prevalence of pancreatitis in organophosphate poisonings. Human and Experimental Toxicology, 21(4), 2002, 175-177.
- [12]. Krupesh N, Chandrashekar TR, Ashok AC. Organophosphate poisoning – Still a challenging preposition. Indian J Aneasth. 46, 2002, 40-43.