

## Management of Caesarean scar ectopic pregnancy via Hysterotomy- a Case Report

Bharti Soy<sup>1</sup>, Zeenie Sarda Girn<sup>2</sup>, Sandeep Singh Bakshi<sup>3</sup>

<sup>1</sup> Senior Resident-Department of Obstetrics and Gynaecology

<sup>2</sup> Senior Consultant and HOD-Department of Obstetrics and Gynaecology

<sup>3</sup> Senior Consultant and HOD-Department of Radiodiagnosis and Imaging  
SPS Apollo Hospitals, Ludhiana, India

---

**Abstract:** Caesarean scar ectopic pregnancy is an uncommon condition, however the incidence of the same is now on an increase. Due to severity of complications, it is important to diagnose scar pregnancy as early and as accurately as possible. There are no ideal management options available and management also depends upon various factors like severity of symptoms, medical condition of the patient, desire to preserve fertility, gestational age and surgical experience. Management of scar ectopic pregnancy is a true challenge for obstetricians and gynaecologists. We report a case of caesarean scar ectopic pregnancy diagnosed by ultrasound at 11 weeks gestation and managed successfully by conservative surgical treatment via hysterotomy and thus conserving fertility.

**Keywords:** Caesarean scar, Ectopic pregnancy, Hysterotomy, Myometrium

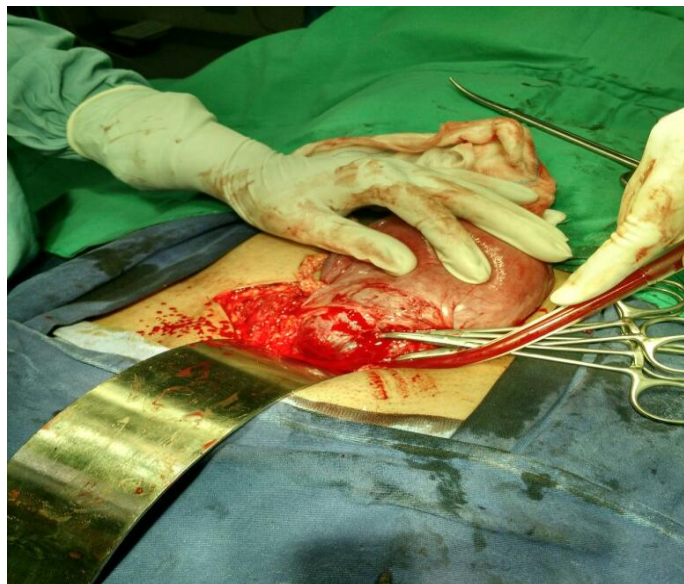
---

### I. Introduction

Caesarean scar ectopic pregnancy is rarest form of ectopic pregnancy where the gestational sac is implanted in myometrium at the site of previous caesarean section scar. Its incidence varies from 1:1800 to 1:2226 of all pregnancies, with increasing incidence due to increased number of caesarean section and newer advances of diagnostic technology [2]. Early diagnosis of caesarean scar pregnancy is essential to avoid serious complications such as severe haemorrhage which can be life threatening and may require hysterectomy.

### II. Case presentation

A 40 yrs old woman G<sub>3</sub>P<sub>1</sub>L<sub>1</sub>A<sub>1</sub> at 11 weeks gestation was referred to our tertiary care centre from a secondary care unit with the diagnosis of caesarean scar ectopic pregnancy. At the time of admission she had no complaints of vaginal bleeding or abdominal pain. Her previous obstetric history included 1 missed miscarriage 5 yrs back for which D&C was done and 1 caesarean section done for non progress of labour 3 yrs ago. On examination her vital parameters were stable. Her abdomen was soft, with no guarding, rigidity or tenderness on palpation. Ultrasound scan was done which showed 11 wks live pregnancy located in caesarean scar site. Her blood parameters including Hb were normal. MRI was done which showed gestational sac in the anterior lower uterine segment with a thin rim of myometrium completely surrounding it with no obvious communication with endometrial cavity. The sac measured 3cm×4.2cm and contained a single fetus within with a crown rump length of 3.9 cm. The placenta was in the infero-posterior aspect of sac abutting the superior portion of the urinary bladder, however no obvious luminal invasion seen with the bladder. No free fluid was seen in the pelvis. Patient and relatives were carefully counselled and termination of pregnancy was suggested. As gestational age was 11 wks surgical treatment was advised. After written and informed consent she was taken up for Hysterotomy. Consent for hysterectomy also taken for in case of uncontrolled haemorrhage. After opening the abdomen, on scar site loose fold of peritoneum was identified and bladder pushed down easily. Uterus was about 10 wk size. There was an ectopic pregnancy at previous LSCS scar site, of size about 4.5cm×3.5 cm. Hysterotomy was done. Incision given over the most prominent part of the mass and all products of conception evacuated completely. Uterine cavity inspected which was empty. Uterus was closed in double layers with vicryl no 1 taking deep sutures. Haemostasis was achieved. Estimated blood loss was around 800 ml. Bleeding from vagina also checked intraoperatively which was within normal limits. Postoperatively uterotonics were given in the form of methergin and rectal misoprostol. The patient had an uneventful postoperative period and was discharged after 4 days with Hb level of 11gm/dl.



**Figure.1-Caesarean scar ectopic pregnancy**

### **III. Discussion**

Ectopic pregnancy is an important cause of morbidity and mortality among fertile women. Among ectopic pregnancy caesarean scar ectopic pregnancy is the rarest form of ectopic pregnancy, the incidence of which is about 6.1% of all ectopic pregnancies[1]. Risk factor is of course previous caesarean section and compounding factors that causes endometrial damage like myomectomy, adenomyosis, IVF & embryo transfer, D&C and manual removal of placenta[3]. It has been proposed that pregnancy enters the caesarean scar via microscopic fistula[3]. Presence of microscopic tract from the scar site in the cavity to myometrium allows the blastocyst to implant wholly within the myometrium.

Patients of scar ectopic presents usually with vaginal bleeding, abdominal pain, but may be asymptomatic in one third of cases. Uterine tenderness may be elicited if the ectopic is in the process of rupture. USG is the first line imaging modality for evaluation of a potential caesarean scar pregnancy. Transvaginal ultrasound has a reported sensitivity of 84.6% and has become the examination of choice for diagnosis. Jurkovic has described a negative "sliding organ sign" as diagnostic of scar ectopic- the inability to displace the gestational sac from its position at the level of the internal os by gentle pressure applied by the transabdominal probe[3]. MRI scan is confirmatory now. MRI is to be done to confirm the diagnosis before any interventions. MRI is highlighted as a problem solving tool capable of more precisely identifying the relationship of a caesarean scar pregnancy to adjacent structures, thereby providing additional information critical to dissecting appropriate patient management. In our patient also MRI was done for confirmation of diagnosis and to decide mode of therapy which would be appropriate for patient. Early diagnosis is utmost importance and it is the cornerstone to reduce heavy complications like uterine rupture, severe haemorrhage and hypovolemic shock related to caesarean scar pregnancy.

As the caesarean scar pregnancy is very rare, there is no ideal management options available. The treatment options depend on severity of symptoms, medical condition of the patient, desire to preserve fertility, gestational age, and surgical experience[2]. Treatment options include medical and surgical management. If diagnosed early, conservative management with systemic or local methotextrate or uterine artery embolisation to prevent haemorrhage is possible if the patient is haemodynamically stable. Graesslin et al[5] and Marchiol et al reported the use of systemic methotextrate followed by dilatation and evacuation with success. Shen L et al[6] concluded that bilateral uterine artery embolisation with methotextrate is safe and effective treatment for caesarean scar pregnancy. The likelihood of treatment success with methotextrate is greatest when serum  $\beta$ -hCG level is less than 5,000 IU/ml, during 1<sup>st</sup> 6 week of pregnancy or when the embryo exhibit no cardiac activity[1].

Surgical treatment includes conservative and radical procedures. Conservative procedures includes excision and retrieval of scar ectopic mass and closure of the defect either by laparoscopy or laparotomy, bilateral ligation of anterior division of internal iliac artery and dilatation & curettage[4]. Lad N L et al[2] reported laparoscopic resection of a caesarean ectopic pregnancy. Gozdemir et al[7] described a case report of caesarean scar pregnancy which was managed by hysterotomy and excision of ectopic mass. Laparotomy followed by wedge resection of lesion i.e. Hysterotomy should be considered in women who doesn't respond to conservative medical treatment or who present late. This seems to be the best option because excision of old scar avoids the

possibility of leaving residual trophoblast thereby reducing recurrence as reported by Fylstra-DL et al[8].Huang et al[9] described new technique for managing Caesarean scar ectopic pregnancy with high intensity focused USG(HIFU) combined with dilatation and curettage .Radical procedure like hysterectomy is done in patient with uterine rupture not willing for conservation of uterus or having uncontrolled bleeding.In our case gestational age was more(11weeks) so surgical management was done.As the patient was haemodynamically stable,conservative approach was possible.Hysterotomy was performed and resection of gestational sac and closure of defect was done.

#### **IV. Conclusion**

Awareness of caesarean scar pregnancy and early and accurate diagnosis improves the outcome and future fertility.Accurate selection of patients,an informed consent to the conservative treatment and strict adherence to the follow up program are mandatory.

#### **References**

- [1]. Seow K M,Huang L W,Lin Y H,Yan-Sheng Lin M,Tsai Y L,Hwang J L.Cesarean scar pregnancy:Issues in management.Ultrasound Obstet Gynecol 2004;23:247-53
- [2]. Lad N L,Lad N N.Laparoscopic management of scar ectopic pregnancy.Fertil Sci Res 2014;1:54-5
- [3]. Jurkovic D,Hillaby K,Woelfer B,Lawrence A,Salim R,Elson C J.First trimester diagnosis and management of pregnancies implanted into the lower uterine caesarean section scar.Ultrasound Obstet Gynecol 2003;21:220-7
- [4]. Rotas M A ,Haberman S,Levgur M.Cesarean scar ectopic pregnancies:Etiology,diagnosis and management.Obstet Gynecol 2006;107: 1373-81
- [5]. O Graesslin,F Dedecker Jr,C Quereux,R Gabriel.Conservative treatment of ectopic pregnancy in a cesarean scar.Obstet and Gynecol 2005;vol.105,no.4:869-871
- [6]. Shen L,Tan A,Zhu H,Guo C,Liu D,Huang W.Bilateral uterine chemoembolisation with methotextrate for cesarean scar pregnancy.Am J Obstet Gynecol 2012 Nov;207(5):386
- [7]. E Gozdemir,H Yilmaz Dogrw,E Gokce,H Uslu Yuvaci.Rapid management with hysterotomy for caesarean scar pregnancy.J Obstet Gynaecol 2015 Feb 11:1-2
- [8]. Fylstra DL,Pound-Chang T,Miller MG,Cooper A,Miller KM.Ectopic pregnancy within a Cesarean delivery scar:A case report.Am J Obstet Gynaecol 2002;187:302-304
- [9]. Huang L,Du Y,Zhao C.High intensity focused Ultrasound combined with Dilatation and curettage for Cesarean scar pregnancy.Ultrasound Obstet and Gynaecol 2014;43:98-101