

Isolated Schwannoma Arising From One of the Peripheral Orbital Nerve-A Rare Clinical Entity

Dr. Padmini H R¹, Dr. Deepa C K², Dr. Dinesh P³

¹. Professor and HOD, Dept. Of Ophthalmology

². Junior Resident, Dept. of Ophthalmology

³. Assistant Professor, Dept. of Ophthalmology

Abstract: A rare case of orbital schwannoma arising from one of the inferior orbital peripheral nerve is presented. An excision biopsy after complete removal of the mass was performed. A definitive diagnosis of schwannoma of nerve was made on histopathological examination. Most schwannomas arise from branches of either the supraorbital or supratrochlear nerves. Here we present a rare case of orbital schwannoma arising one of the inferior orbital nerve.

Keywords: orbital, schwannoma, infraorbital,

I. Case Report

A 55-year-old male presented with a painless, slow growing mass in the left inferior orbit from past three years. On examination, best corrected vision in both eyes was 6/6. The left side demonstrated a solid, non-tender, freely mobile mass in the inferior orbit, totally reducible, no bruit was heard, posterior limit of the mass could not be reached. It was cystic in consistency, measuring approximately 30mm × 10mm. The mass was non-pulsatile and transillumination test was negative [figure.1]

There was no proptosis or globe displacement and ocular motility was normal. The pupillary reactions, colour vision and visual fields were normal. The neurological examinations were also normal. Slit-lamp and fundus examination of the left eye showed normal anterior and posterior segments. The right eye examination and general physical examination were unremarkable.

Computed tomography revealed a non-enhancing well-defined homogenous mass measuring 35mm × 15mm in the left inferior orbit [Figure 2].

A provisional diagnosis of orbital dermoid was made and the patient was taken up for an excision biopsy. A left anterior orbitotomy was performed through an eyelid crease incision, orbital part of the orbicularis oculi was incised and separated, inferior orbital margin was reached, the mass was reducible which was held by an Allis forceps, blunt dissection of periorbita was done; care was taken not to damage inferior rectus and inferior oblique muscles. Intraoperative findings were of a smooth, well-encapsulated mass [figure 3]. The mass was removed en bloc with intact capsule. Postoperatively, on day 1, wound was clean with very minimal swelling, conjunctival cul-de-sac was white and quiet and patient had an uneventful recovery. [figure-4]

On histopathological examination, the gross specimen consisted of a smooth well-encapsulated solid mass measuring 35mm in the greatest diameter. Microscopically, alternating cellular rich, spindle cells having fusiform nuclei and eosinophilic cytoplasm (Antoni-A) areas and less cellular (ovoid cells), myxoid (Antoni-B) areas of biphasic pattern of tumour cells was seen [figure 5a]. At places, these tumour cells arranged in palisades known as Verocay bodies were also seen [figure 5b]. A final histopathological diagnosis of schwannoma was made.

II. Discussion:

Schwannomas are benign encapsulated tumours, originating from Schwann cells of the peripheral nerves. Schwannomas constitute approximately 1% of all orbital tumours^[1].

Orbital Schwannomas usually present between 20 to 70 years of age. Schwannomas are usually asymptomatic when small and may produce progressive, painless proptosis on enlargement. A variable combination of signs and symptoms may be present due to the variable origin and location of tumour in the orbit^[2]. Displacement of the globe is related to the site of the tumour. The supraorbital and supratrochlear nerve are more commonly affected than the infraorbital nerve and hence produce downward displacement of the globe. Less commonly, the tumour may arise from the infraorbital nerve and produce upward displacement of globe.

Most Schwannomas are progressively growing tumours that eventually require treatment. The best treatment for orbital Schwannomas is total surgical excision without complication^[4]. And the tumor should be removed intact at the earliest to prevent compression of the optic nerve^[3]. Incomplete removal is associated with eventual recurrence and more aggressive behaviour^[5]. Highly cellular tumours have greater chance of recurrence and malignant transformation. Therefore an early treatment is indicated to avoid the complications

related to progressive growth of the tumor. While managing our patient, we successfully achieved the above objectives with complete excision of the tumor.

Extensive literature search revealed only a few case reports of orbital Schwannomas arising from the infraorbital nerve^[6-10]. Our patient presented with the tumor in this uncommon location.

III. Conclusion;

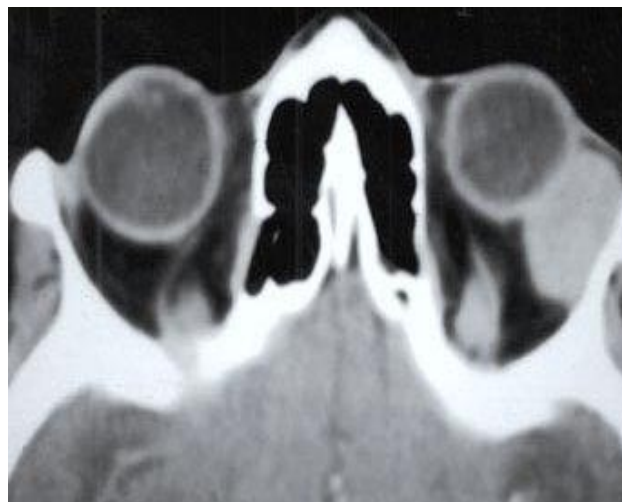
A solitary Schwannomas in the infraorbital region, though rare, should be considered as a differential diagnosis of a unilateral slow- growing orbital mass in an adult and prompt management is recommended to prevent complications.

References

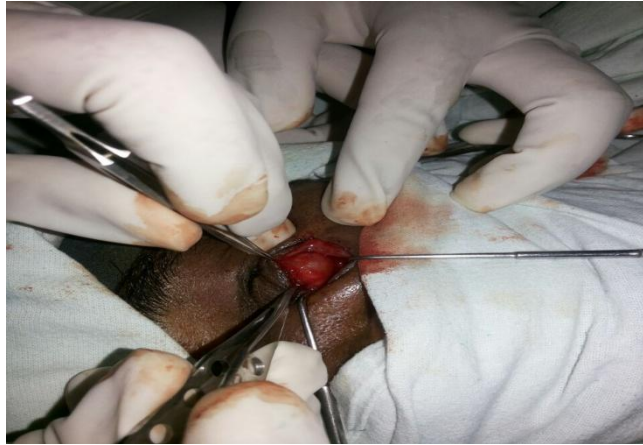
- [1]. M Brucoli, M. Giarda, F. Arcuri, A. Benech. A Benign isolated schwannoma of the orbit. 2011;22(6):2372-4. [PubMed]
- [2]. Rootman J, Goldberg C, Robertson W. Primary orbital schwannomas. Br J Ophthalmol. 1982;66:194-204. [PMC free article] [PubMed]
- [3]. Konrad EA, Thiel HJ. Ophthalmologica. Basel: 1988. Schwannoma of the Orbit; pp. 118-27. [PubMed]
- [4]. U. Schick, J. Bleyen, and W. Hassler, "Treatment of orbital schwannomas and neurofibromas," British Journal of Neurosurgery, vol. 17, no. 6, pp. 541-545, 2003. View at Publisher · View at Google Scholar · View at Scopus
- [5]. S. Sudhir, S. Subodh, G. Divyesh, S. Sumit. Case Report of Isolated Schwannoma— A Rare Eyelid Tumor, 2014;7(2):143-5
- [6]. Emerick CW. Neurilemmoma of the infraorbital nerve. Laryngoscope. 1965;75:820-2. [PubMed]
- [7]. Pereira LA, Choo YB. Schwannoma of the infraorbital nerve. Ear Nose Throat J. 1978;58:236-9. [PubMed]
- [8]. Artenie V, Muntenescu M. On a case of right infraorbital invading schwannoma. Rum Med Rev. 1961;5:84-6. [PubMed]
- [9]. Kahl RI. Neurinoma of the infraorbital nerve. Z Neurol. 1973;204:155-8. [PubMed]
- [10]. Batiunin IT. On neurinoma of the infraorbital nerve. Vest Otorinolaringol. 1962;24:99-101. [PubMed]



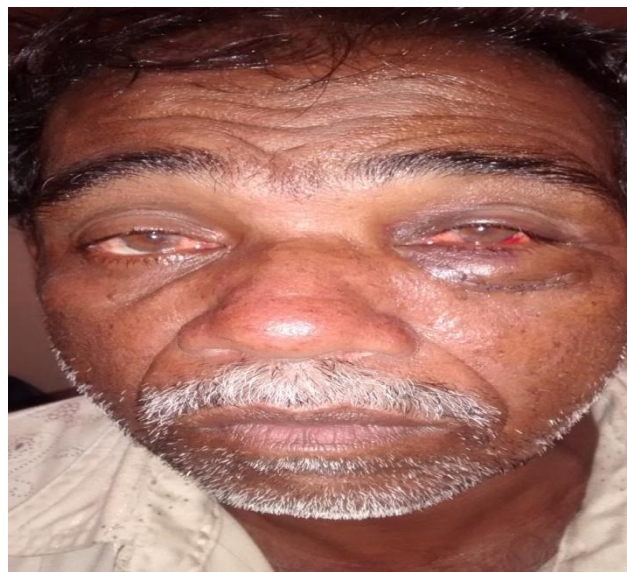[figure.1]



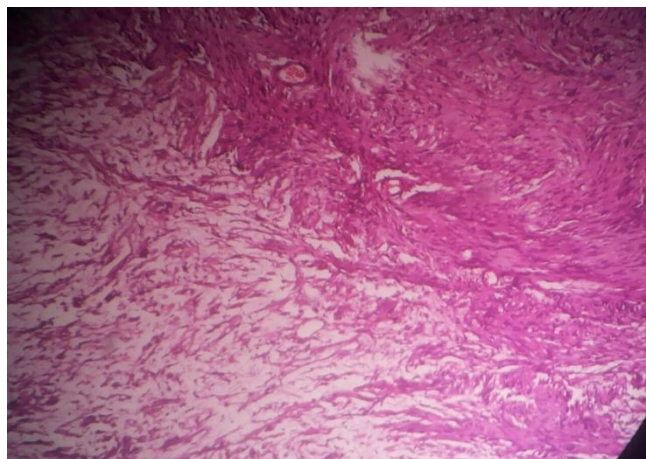
[Figure 2]



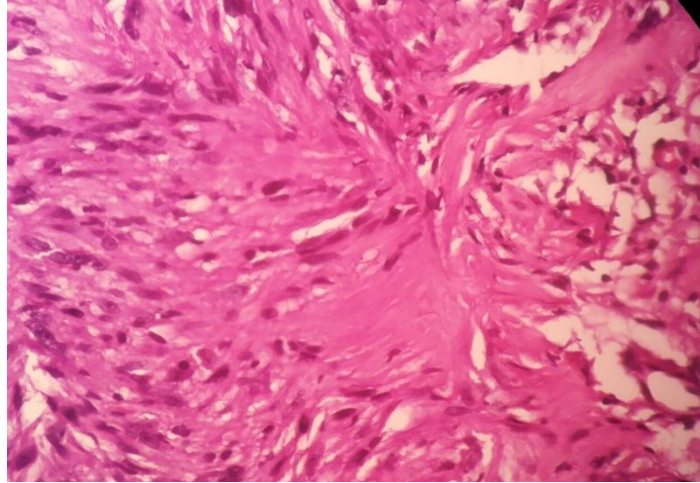
[figure.3]



[Figure 4]



[Figure-5a]



[Figure -5b]