

Concha Bullosa and Its Association with Chronic Sinusitis

Shyamkant Prasad¹, Babita Ahlawat², Ashok Kumar³, Sulabha M. Naik⁴,
Anil Agrawal⁵, Alka Nagvanshi⁶

¹Senior Resident, ³Associate Professor, ⁴Professor & Head Department of ENT, Shaheed Hasan Khan Mewati Government Medical College, Nalhar, Mewat, India

²Senior Resident, Department of Dentistry, Shaheed Hasan Khan Mewati Government Medical College, Nalhar, Mewat, India

⁵Consultant, Department of ENT, Shyam Shah Medical College Rewa, India

⁶Department of Dentistry, Sumitra Hospital, Delhi, India

Abstract:

Objective: To determine the proportion and the distribution of concha bullosa in patients with Chronic sinusitis and to determine the relationship between concha bullosa and age, sex, laterality, symptoms, mucosal changes and others.

Design: Retrospective study.

Setting: Otorhinolaryngology, head and neck surgery department.

Method: Computed Tomography Paranasal sinus done in 120 patients suffering from Chronic sinusitis between 2010 and 2013 were reviewed. Distribution of Concha Bullosa and its association with Chronic sinusitis was tested using chi-square tests.

Result: The incidence of Concha bullosa in Chronic sinusitis was 45%. Patient's age ranged from 16 to 54 years and mean age of patients with concha bullosa was 28.61 years. Out of 69 males, 43.47% had CB. Out of 51 female, 47.06% had concha bullosa. Most common symptom was nasal obstruction and seen in 72.22% of patient. There was no evidence of the predominance of concha bullosa on any one side. There was significant relation between concha bullosa & mucosal changes in maxillary sinus.

Conclusion: Concha bullosa is a common occurrence in the nasal cavity with no correlation between concha bullosa and age, sex and laterality. There is statistically significant relationship between the presence of concha bullosa and mucosal changes in maxillary sinus but no correlation with mucosal changes in anterior ethmoidal cells, posterior ethmoidal cells, frontal sinus and sphenoid sinus.

Keywords: concha bullosa, sinusitis, turbinate

I. Introduction

The cavities of the human body have always aroused human interest. Since time immemorial, the medical faculties have been devising the ways to look into the nooks and corners of these cavities for better understanding the anatomy, physiology and pathology of the area. The same is true for the nasal cavity also.

Chronic sinusitis is one of the most frequent otorhinolaryngologic diseases encountered. This disease accounts for an average of 11.6 million visits to primary care physicians annually¹. A general histopathological definition of sinusitis is inflammation of the nasal and paranasal sinus mucosa. Middle meatal obstruction and subsequent rhinosinusitis could be due to concha bullosa (CB), deviated nasal septum (DNS), Haller cells, paradoxical middle turbinates, agger nasi cells and many others. The most common anatomical variations after agger nasi cells are concha bullosa and deviated nasal septum². Concha bullosa is the pneumatization of the concha. It is most commonly encountered in the middle concha, though can also be seen in superior and inferior concha. It might present unilaterally or bilaterally, very small or may attain a considerable size²⁻⁴. Middle concha appears to arise from the medial part of the ethmoid bone. Pneumatization of the middle concha is an extension of the normal pneumatization of the ethmoid air cells. The origin of this extension forms the ostium of the cell. The cells continue to grow and enlarge. Their enlargement is limited by the adjacent cells and the presence of bone.

Bolger et al⁵ has divided the pneumatization of the middle concha into three groups. 1. Lamellar type - Pneumatization of the vertical lamella of middle turbinate[figure 1]. 2. Bulbous type - Pneumatization of the inferior part of middle turbinate[figure 2]. 3. Extensive type - Pneumatization of both the vertical lamella and the inferior part of middle turbinate[figure3]. The presence of CB alone is not necessarily a pathologic finding. However, if combined with other anatomic abnormalities, such as a medially bent uncinate process or an enlarged ethmoidal bulla, even a small CB may produce a significant narrowing of the anterior and middle portion of the middle meatus. Large contact surfaces may appear that predispose to repeated & later, persistent

local complaints that may spread to involve the adjacent areas. If pneumatization is extensive, a large CB may cause significant problems by its size alone, e.g., marked nasal obstruction.

The CB is a classic example of an anatomic variation that predispose to sinus disease. A CB by itself does not represent a disease state per se, but it predisposes the patient to develop Chronic sinusitis more readily & more frequently. The CB also illustrates the significant role that mucosal contact areas play in the formation of nasal polyps.⁶ Endoscopically, a CB usually presents as an enlarged head or body of the middle turbinate that is in contact medially with the nasal septum and bulges laterally into the lateral wall of the nose, thereby making inspection of the middle meatus impossible. Computed Tomography has brought revolutionary changes and is an excellent tool in giving information about the anatomical variants – Concha bullosa, deviated nasal septum, Onodi cell, Haller cell, paradoxical MT, medially bent uncinatate process. The slice thickness can be varied but should never be more than 5 mm and at the region of OMC it should be 2 mm. Computed Tomography (coronal view) is the best way for imaging concha bullosa.

The incidence of positive CT findings for concha bullosa is varied from 14-53%, and the relationship of CB to paranasal sinus disease continues to be debated⁷. Discussion continues regarding the relationships between concha bullosa and their link to sinus diseases. Some studies suggest significant relation between CB and sinus disease, while others have found little or no relation. The aim of the study is to determine the incidence and distribution of concha bullosa and its association with chronic sinusitis.

II. Materials And Methods

This study was carried out in ENT department of ST STEPHEN'S HOSPITAL, TIS HAZARI, DELHI - 1100054 between 2010 and 2013. The study period was of 3 years and the sample size of 120 Patients. CT paranasal sinus was done in patients with chronic sinusitis. Criteria for selecting chronic sinusitis was based on the Task Force on Rhinosinusitis³. Chronic sinusitis criteria was divided into major and minor factors. A Chronic sinusitis diagnosis requires the presence of at least two major factors or one major factor with two or more minor factors, or nasal purulence on examination. The signs and symptoms must persist for at least 12 weeks to qualify as Chronic sinusitis. MAJOR FACTORS include nasal obstruction/blockage, nasal discharge/purulence/discoLOURED/postnasal drainage, hyposmia/anosmia, Facial pain/pressure, facial congestion/fullness. MINOR FACTORS include headache, fever, halitosis, fatigue, dental pain, cough, ear pain / pressure / fullness.

Patients less than 12 years of age, complaining of facial pain or pressure not accompanied by any other major factors, nasal polyposis, history of previous nasal surgery, presence of comorbid conditions – bronchial asthma, chronic granulomatous disease, tumours, sexually transmitted disease, history of using snuff were excluded. 120 patients were randomly selected. All selected patients underwent detailed ear, nose and throat examination, Diagnostic nasal endoscopy was done by Messerklinger technique. Computed tomography of paranasal sinus was done in all patients. A concha bullosa was defined as being present when the turbinate was pneumatized. Any degree of pneumatization of the turbinate was considered significant and included in this study.

The collected data were evaluated, analysed and the statistical tests used were mean and chi-square test at a 5% level of significance. The 'p' value was calculated which denotes the probability that the difference between two samples occurred by chance. The 'p' value less than 0.05 is considered to be statistically significant. This indicate that the difference occurred by chance has a probability of 5% or in other words, the examiner can be 95% sure that the difference is not by chance. A 'p' value less than 0.01 is termed as highly significant.

III. Results

The study was conducted on 120 patients from 2010 to 2013. These observations were drawn from the findings of CT paranasal sinus.

Out of 120 patients, at least one CB were present in 54 patients (45%).

Out of 120 patients studied, 69 (57.5%) were male and 51 (42.5%) were female. 30 (43.47%) male had Concha bullosa and 24 (47.06%) female had CB. There was no significant difference in the prevalence of CB among the two sexes reporting to ENT OPD with chronic sinusitis. (Chi square value = 0.822, P < 0.05)

The age ranged from 16 years to 54 years. Mean age was 30.33 years. Mean age of patients with CB was 28.61 years. Most of the patients with symptoms of chronic sinusitis attending OPD were in the age group of 16-25 (42.5%) years. Our study gives an indirect evidence of higher prevalence of CB in 16-25 year age group. But there is no significant difference in the prevalence of CB among the four age groups. (Chi square value = 0.843, P < 0.05). There were many social and economic factors which influence the health care seeking behaviour of the individual. These factors had a variable influence on different age groups. A particular factor may hinder the patient from coming to the hospital. Loss of wages, cost of travel etc operate differently in different age and sex groups. Thus our study was subject to reporting bias because of these factors.

Of the 54 patients with CB, the most common symptom was nasal obstruction i.e. in 39 patients (72.22%), followed by nasal discharge in 30 patients (55.56%), headache in 24 patients (44.44%), Postnasal drip in 18 patients (33.33%), sneezing in 15 patients (27.78%), facial pain in 9 patients (16.67%), hyposmia/anosmia in 6 patients (11.11%) and other symptoms in 12 patients (22.22%). Except for a significant relationship between Concha Bullosa and nasal obstruction, all other relationship between CB and symptoms were weak.[table 1]

In 120 patients, there were 240 sides. CB were present on 87 sides (36.25%)

Out of 54 patients with CB, Rt side CB was present in 15 patients (27.78%), Lt side CB in 6 patients (11.11%), bilateral equal CB in 6 patients (11.11%), bilateral with predominant Rt sided CB in 12 patients (22.22%) and bilateral with predominant Lt sided CB in 15 patients (27.78%). Unilateral CB were in 21 patients (38.89%) and bilateral CB in 33 patients (61.11%). There was no evidence of the predominance of concha bullosa on any one side in the study.

“All the patients in the study had CB in their middle turbinate”.

Out of 87 sides with CB, 42 (48.27%) were lamellar type, 27 (31.03%) were bulbous type and 18 (20.69%) were extensive.

Out of 240 sides, mucosal changes in maxillary sinus were seen in 162 sides (67.5%). Out of 87 sides with CB, 72 sides (82.75%) had mucosal changes in maxillary sinus while 15 sides (17.24%) had normal sinus. Out of 153 sides without CB, 90 sides (58.8%) had mucosal changes and 63 sides (41.2%) had normal sinus. Since chi-square value is 0.028, there is significant relation between concha bullosa & mucosal changes in maxillary sinus.[table 2]

Out of 240 sides, mucosal changes in anterior ethmoidal cell were seen in 186 sides (77.5%). Out of 87 sides with CB, 72 sides (82.8%) had mucosal changes in anterior ethmoidal cells while 15 sides (17.2%) had normal cells. Out of 153 sides without CB, 114 sides (74.5%) had mucosal changes and 39 sides (25.5%) had normal cells. Since chi-square value was 0.396, there was no significant relation between concha bullosa & mucosal changes in anterior ethmoidal cells.

Out of 240 sides, mucosal changes in posterior ethmoidal cell were seen in 117 sides (48.75%). Out of 87 sides with CB, 39 sides (44.82%) had mucosal changes in posterior ethmoidal cells while 48 sides (55.17%) had normal cells. Out of 153 sides without CB, 96 sides (51%) had mucosal changes and 57 sides (49%) had normal cells. Since chi-square value was 0.120, so there was no significant relation between concha bullosa & mucosal changes in posterior ethmoidal cells.

Out of 240 sides, frontal sinus opacity seen in 150 sides (62.5%). Out of 87 sides with CB, 54 sides (62.1%) had mucosal changes in frontal sinus while 33 sides (37.25%) had normal sinus. Out of 153 sides without CB, 96 sides (62.75%) had mucosal changes and 57 sides (37.25%) had normal sinus. Since chi-square value was .952, so there was no significant relation between concha bullosa & mucosal changes in frontal sinus.

Out of 240 sides, sphenoid sinus opacity was seen in 66 sides (27.5%). Out of 87 sides with CB, 18 sides (20.7%) had mucosal changes in sphenoid sinus while 69 sides (79.3%) had normal sinus. Out of 153 sides without CB, 48 sides (31.37%) had mucosal changes and (68.63%) had normal sinus. Since chi-square value was 0.304, so there was no significant relation between concha bullosa & mucosal changes in sphenoid sinus.

IV. Discussion

Anatomical variants, especially Concha bullosa were noted, tabulated and statistically interpreted. The study revealed 57.5% were males and 42.5% were females Out of 69 males, 43.47% had CB. Out of 51 female, 47.06% had concha bullosa. No correlation was found between sex and CB. The age ranged from 16 years to 54 years. Mean age was 30.33 years. Mean age of patients with CB was 28.61%. There was no correlation between age and CB.

Of the 54 patients with CB, the most common symptom was nasal obstruction i.e. in 39 patients (72.22%), followed by nasal discharge in 30 patients (55.56%), headache in 24 patients (44.44%), Postnasal drip in 18 patients (33.33%), sneezing in 15 patients (27.78%), facial pain in 9 patients (16.67%), hyposmia/anosmia in 6 patients (11.11%) and other symptoms in 12 patients (22.22%)

Of the patients having concha bullosa, the most common symptom was nasal obstruction which could be because of the middle turbinate becoming bullous and blocking the nasal passage. Headache/facial pain which could be sinogenic or more probably contact headache.

The present study serves to find out the incidence of CB in cases of chronic sinusitis. Incidence of CB in the age group 16-54 yrs old was variable; different studies have shown varying incidence rates. In the present study the incidence of CB was 45%. Results of study done by Subramanian S et al⁸ were similar to this study and the incidence of CB in patients with age group ranged from 11yrs to 56 yrs was 49.5%. Mohammad-Reda et al⁹ found incidence of CB to be 64.9% patients. H. Halis Unlu et al¹⁰ found this in 53.06%, S. Nadas et al¹¹ found it at 53% and Lam WW et al⁴ put it at 47%. Contrary to these studies, a relatively low incidence was observed by Zinreich SJ et al¹² who found it to be 34%, V.J. Lund¹³ in 24% and William E. Bolger et al⁵ in 15.7% of patient.

This variable may be due to differences between the study groups, differences in pneumatization parameters and the analytical methods used.

Out of 240 sides, CB was present in 47% sides. In the present study, U/L CB is seen in 38.89% of patients and bilateral CB in 61.11%. Hatipoğlu HG¹⁴ et al found U/L CB in 29.42% and bilateral CB in 70.58%. H. Halis Unlu¹⁰ et al found these figures to be 38.5% and 61.5% respectively. S. Nadas et al¹¹ found unilateral type CB in 59.76% and bilateral in 40.24%. Mohammad-Reda et al⁹ found bilateral CB in 39.8% and unilateral in 60.2% patients. Overall this showed increased incidence of bilateral CB than U/L CB. In this study Rt side U/L CB were present in 27.78% patients, Lt side U/L CB in 11.11% patients. In case of bilateral CB, B/L equal CB in 18.18%, Rt side Predominant CB in 36.36% and Lt side Predominant CB in 45.45%.

Hatipoğlu HG et al¹⁴ had studied that in case of B/L CB, 47.05% of CB were Rt dominant, 44.11% were Lt dominant and 8% were co-dominant. A study done by Stallman et al¹⁵ showed that in case of B/L CB, 41% had equal size CB and 59% had dominant CB. No significant correlation was developed between the Rt side, Lt side with CB.

In the present study, all CB were seen in middle turbinate. Not a single pneumatization is seen in the inferior and superior turbinates. According to Stammberger⁶ pneumatization of superior turbinate is extremely rare. He never encountered a case of pneumatization of the inferior turbinate. A study by Kiroglu et al¹⁶ showed that Concha bullosa of the inferior turbinate is an extremely rare anatomic malformation with 11 reports of this condition in the literature.

In the present study, out of 29 CB, lamellar type were 48.27%, bulbous type were 31.03% and extensive were 20.69%. The study showed higher frequency of lamellar type CB followed by bulbous type CB and the least is extensive type CB. Number of studies were done on the incidence of type of CB. Results of study done by Bolger et al⁵ were similar to this study and he found lamellar type CB in 46.2% and bulbous type in 31.2%. extensive type in 15.7%. Uygur et al¹⁷ found this figure as 55.3%, 33.9% and 10.8% respectively. H. Halis Unlu et al¹⁰ found 45% lamellar type CB, 21% bulbous type CB and 34% extensive type CB. Contrary to these studies, a different frequency of the type of CB was observed by Hatipoğlu HG et al¹⁴ who found 20.86% lamellar type, 32.17% bulbous type and 46.95% extensive type CB. Tonai et al¹⁸ studied the frequency of CB types and found lamellar type in 2%, bulbous type in 19% and extensive type in 52%.

This study shows a significant relationship between CB & mucosal changes in maxillary sinus. In rest of the paranasal sinuses no significant relation was seen between mucosal changes and CB. Mohammad-Reda et al⁹ in his study showed inflammatory disease of the sinuses in 71.7% patients with concha bullosa and 57.7% patients without concha bullosa. The incidence of inflammatory disease of the sinuses was higher when there was coexistence of concha bullosa and deviation of the nasal septum. Thus he concluded that concha bullosa was associated with higher incidence of inflammatory sinus disease. With simultaneous concha bullosa and nasal septal deviation, the incidence of inflammatory disease increases. H. Halis Unlu et al¹⁰ in his study found that 38.1% had mucosal changes in maxillary sinus, 48.4% in anterior ethmoidal cells, 16.75% in posterior ethmoidal cells, 18.3% in frontal sinus and 5.6% in sphenoid sinus. Assessment of distribution of mucosal changes revealed that anterior ethmoidal cells were most commonly involved when cases with and without CB were considered separately, a significant difference was also recorded. However the presence of CB did not seem to affect the order of distribution of opacification to the sinuses with respect to frequency of involvement.

In the studies done by Hatipoğlu HG et al¹⁴, Zinreich SJ et al¹⁹, Lam WW et al⁴ the presence of concha bullosa showed no statistically significant association with different patterns of chronic sinusitis.

V. Conclusion

The purpose of this study was to find out the incidence of Concha bullosa in cases of chronic sinusitis. However, a review of literature reveals a lack of consensus with respect to the incidence of Concha bullosa and its association with chronic sinusitis. In this study it is concluded that the Concha bullosa is a common variant with incidence of 45% in chronic sinusitis. There is a strong association between the presence of a concha bullosa and mucosal changes in maxillary sinus. There is also statistically significant relationship between nasal obstruction and in patients of chronic sinusitis with concha bullosa.

Reference

- [1] Anand K. Devaiah. Adult chronic rhinosinusitis: diagnosis and dilemmas. *Otolaryngologic Clinics of North America* 2004; 37: 243
- [2] Mamatha H, Shamasundar NM, Bharathi, et al. Variations of Osteomeatal Complex and Its Applied Anatomy: A CT scan Study. *Indian J Sci Technol* 2010; 3(8): 904-7.
- [3] Vincent TE, Gendeh BS. The Association of Concha Bullosa and Deviated Nasal Septum with Chronic Rhinosinusitis in Functional Endoscopic Sinus Surgery Patients. *Med J Malaysia* 2010; 65(2): 108-11.
- [4] Lam WW, Liang EY, Woo JK, et al. The Etiological Role of Concha Bullosa in Chronic Sinusitis. *Eur Radiol* 1996; 6(4): 550-2.
- [5] Bolger WE, Butzin CA, Parsons DS. Paranasal sinus bony anatomic variations and mucosal abnormalities: CT analysis for endoscopic sinus surgery. *Laryngoscope* 1991; 101: 56-64.

- [6] Heinz Stammberger et al. Functional Endoscopic Sinus Surgery – The Messerklinger Technique; Endoscopic and radiologic diagnosis; Page 166-168
- [7] Wolf JS, Biedlingmaier JF. The Middle Turbinate in Endoscopic Sinus Surgery. *Curr Opin Otolaryngol Head Neck Surg* 2001; 9: 23-6.
- [8] Subramanian S et al. Concha bullosa in chronic sinusitis. *General Hospital Melaka*. 2005 Dec;60(5):535-9.
- [9] Mohammad-Reda et al. Concha bullosa and other sinonasal variants: clinical and CT correlation, *Iranian Journal of radiology*, 31-36 2004
- [10] Unlu HH, Akyar S, Caylan R, Nalca Y. Concha bullosa. *Journal of otolaryngology* November 1994; 23:23-27(16)
- [11] Nadas S. Concha bullosa: frequency and appearances on CT and correlations with sinus diseases with chronic sinusitis. *Neuroradiology* 1995 Apr;37(3):234-7(20)
- [12] Zinreich SJ, Mattox DE, Kennedy DW, Chisholm HL, Diffley DM, Rosenbaum AE, Russell H. Morgan Department of radiology and radiological science, Johns Hopkins medical institutions, Baltimore. Concha bullosa CT evaluation. 1988;12(5):778-784.(19)
- [13] V.J.Lund. Anatomy of the nose and paranasal sinuses. *Scott-Brown's Otolaryngology (Sixth Edition)* 1997; Vol. 1: 5/14-19.(26)
- [14] Hatipoglu HG,MA, Yuksel E. Concha bullosa types: their relationship with sinusitis and frontal recess disease. *Journal of diagnostic interventional radiology*; September 2005; 11:145-149 (15)
- [15] Stallman et al. The incidence of concha bullosa and its relationship with DNS and paranasal sinus disease, *American journal of otolaryngology*, 2004 Oct;25(9): 1613-8(17)
- [16] Kiroglu et al. Isolated turbinitis & pneumatization of concha inferior in a child, *American journal of otolaryngology*, 2007 Jan-Feb; 28 (1), 67-68
- [17] Uygur K, Tuz M, Dogru H. The correlation between septal deviation and CB. *Otolaryngology Head and neck surgery* 2003; 129: 33-36(29)
- [18] Tonai A, Baba S. Anatomic variation of the bone in sinonasal CT. *Acta otolaryngology* 1996; 535; 9-13.(27)

FIGURE

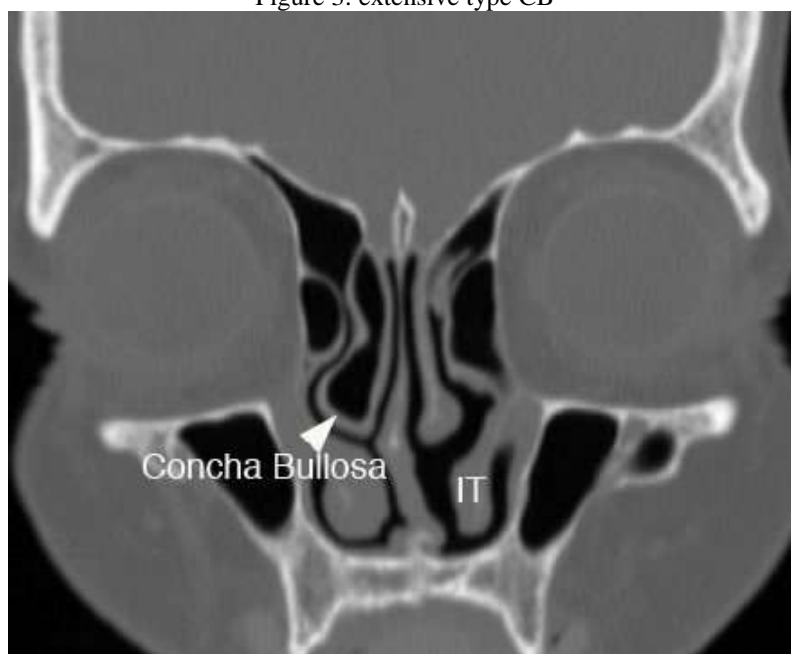
Figure 1: lamellar type CB

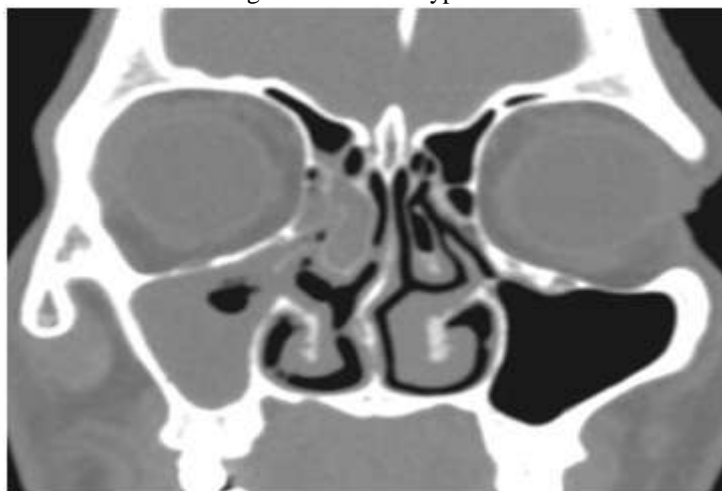

Figure 2: bulbous type CB

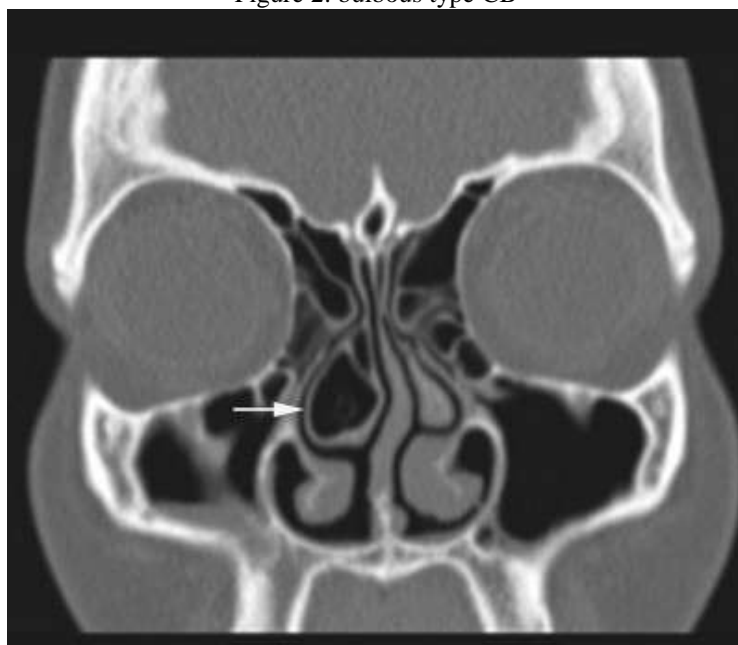

Figure 3: extensive type CB



TABLES

Table 1. Symptoms related to Concha bullosa

	Nasal obstruction	Nasal discharge	Post nasal drip	Sneezing	Hyposmia/ anosmia	Facial pain/ pressure	Headache	Others
CB(18)	39	30	18	15	6	9	24	12
No CB (22)	42	27	24	21	6	9	12	15
Chi square value	0.048	0.356	0.842	0.781	0.832	0.789	0.071	0.97

Table 2: Mucosal changes in maxillary sinus

Type		CB present	CB absent	Chi square test
Maxillary Sinus	normal	15	63	
	abnormal	72	90	0.028
Anterior Ethmoidal Cells	normal	15	39	
	abnormal	72	114	0.396
Posterior Ethmoidal Cells	normal	48	57	
	abnormal	39	96	0.120
Frontal Sinus	normal	33	57	
	abnormal	54	96	0.952
Sphenoid Sinus	normal	69	105	
	abnormal	18	48	0.304