

## A Clinical Study on “Role of Optical Coherence Tomography(Oct) in The Evaluation of Macular Edema in Retinal Vein Occlusions”.

\*Dr.P.Rajasekhar<sup>1</sup> M.S., Dr.M.Parnikumar<sup>2</sup> M.S.,Dr.Ishaq Mohammad<sup>3</sup> PG.

<sup>1</sup>Dr.P.Rajasekhar M.S., Assistant professor of ophthalmology, Guntur Medical College, Guntur, AP

<sup>2</sup>Dr.M.Parni Kumar M.S., Professor & HOD of ophthalmology, Guntur Medical College, Guntur, AP

<sup>3</sup>Dr. Ishaq Mohammad, Junior resident, Ophthalmology, Guntur Medical College, Guntur, AP

Presenting author-Dr. P.RAJASEKHAR MS,

Corresponding Author-Dr.M.PARNI KUMAR MS,

**Abstract:** Retinal vein occlusion remains the second most common cause of vision loss from retinal vascular disease, second to diabetic retinopathy. Retinal vein occlusions (RVO) are categorized into branch (BRVO), hemiretinal (HRVO) or central retinal vein occlusion (CRVO) depending on the location of the occlusion. Vision loss from retinal vein occlusions is secondary to macular edema. Macular oedema (ME) occurs in a wide variety of pathological conditions and accounts for different degrees of vision loss. Early detection of ME is therefore critical for diagnosis and therapeutic management. Optical coherence tomography (OCT) is a non-contact, diagnostic method that uses infrared light, which allows the analysis of the retinal structure by means of high-resolution tomographic cross sections. The identification, localisation, quantification and long-term follow-up of fluid collections are the most important capabilities of OCT. Since the introduction of OCT in clinical practice, it has become an invaluable diagnostic tool and different patterns of ME have been reported. Hence, the purpose of this study is to evaluate Macular oedema in Retinal Vein Occlusions on OCT.

**Keywords :** CRVO, BRVO, Macular oedema(ME), Macular thickness, OCT

Date of Submission: 22-11-2017

Date of acceptance: 05-12-2017

### I. Introduction

**Retinal vein occlusion (RVO)** is the second most common retinal vascular disease following diabetic retinopathy. It typically affects patients 50 years of age or older and may cause significant ocular morbidity. It usually affects men and women equally. Individuals with RVO suffer a significant decrease in vision-related quality of life.

Retinal vein occlusions can be classified according to the site of venous occlusion into:

- A. Central retinal vein occlusion (CRVO)
- B. Branch retinal vein occlusion (BRVO)
- C. Hemicentral retinal vein occlusion (HCRVO).

The overall incidence of RVO in population-based studies varies depending on age. In the Blue Mountains Eye Study (BMES) in Australia, the prevalence of retinal vein occlusion was 0.7% among persons aged 49–60 years, 1.2% for persons aged 60–69 years, 2.1% for those 70–79 years, and 4.6% for persons 80 years and older. The mean age of onset of vein occlusion was 63 years. Hayreh reported that after any variant of RVO in one eye, the incidence of developing a second vein occlusion in the next 4 years was 2.5% in the same eye and 11.9% in the fellow eye. Of all the RVO in the BMES, 69.5% were BRVO, 25% CRVO, 5.1% HRVO, and 5.1% were bilateral. Retinal venous occlusive disease typically occurs at an arteriovenous crossing in BRVO or at the lamina cribrosa in CRVO and HRVO. Retinal vein occlusions have a characteristic, although somewhat variable, appearance with intraretinal hemorrhages, cotton-wool spots, tortuous and dilated retinal veins, retinal edema and, occasionally, optic disk swelling. These findings are present segmentally in BRVO, in either the superior or inferior two quadrants in HRVO, and in all quadrants of the fundus in CRVO. Vision loss can vary from minimal or no vision loss to complete blindness, which is painless.

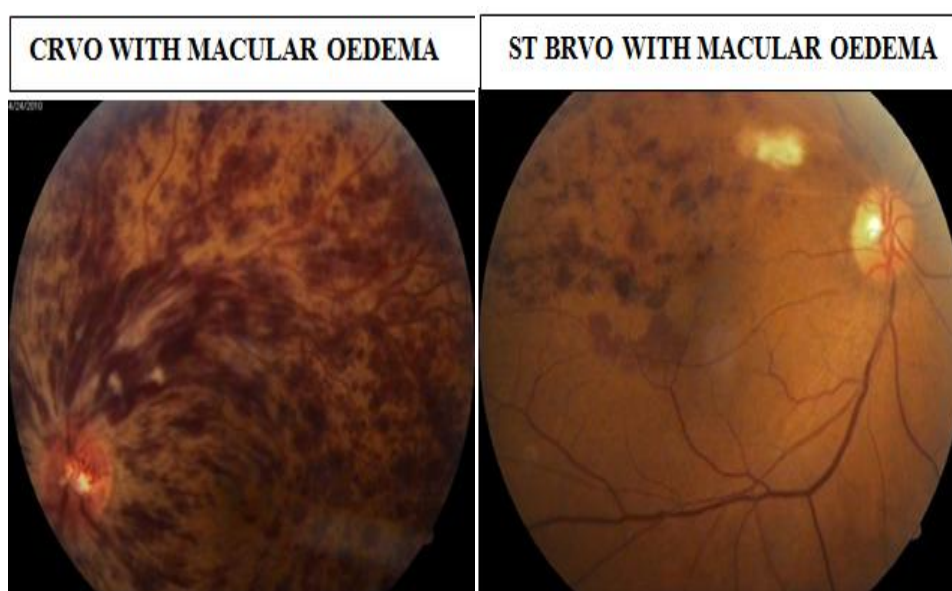
Causes of vision loss associated with RVO include macular edema, macular nonperfusion, epiretinal membrane, dense intraretinal hemorrhages, vitreous hemorrhage, neovascular glaucoma, or tractional retinal detachment (TRD). Recognition and treatment of the underlying systemic disease can benefit the patient visually and improve overall health.

Retinal edema becomes much more visually significant when it involves the fovea. Macular edema is the most common complication, and leading cause of vision loss, associated with RVO. In patients with perfused macular edema, approximately one-third will regain some vision spontaneously. However, this becomes less likely the longer the edema persists. Spontaneous visual improvement is less common in non-perfused macular edema. Interleukin-6 (IL-6) and vascular endothelial growth factor (VEGF) have been implicated in the development of macular edema following non-perfused RVO.

### 1.1 Macular oedema

Is considered to be present, when the foveal thickness is  $> 212 \pm 23 \mu$  and extra-foveal thickness  $> 212 \pm 20 \mu$ . Macular edema can be confirmed by slit lamp biomicroscopy with +78 D/+90D lens, Indirect ophthalmoscopy and stereo fundus photography. The Optical Coherence Tomography(OCT) provides qualitative assessment of the type of macular edema and also the quantitative measurement.

While slit lamp biomicroscopic fundus examination remains a useful tool for qualitative identification of macular edema, recent widespread availability of Optical coherence tomography imaging has made it possible to acquire a quantitative measure of macular edema and change in macular edema over time and after treatment. OCT images correlate well with fundus biomicroscopy.



## II. Optical Coherence Tomography (OCT)

OCT provides useful information for the characterization of ME of any origin, supplying quantitative and qualitative information. The determination of retinal thickness as well as the evaluation of the morphological changes associated to fluid accumulation and the vitreo macular interface are of the highest importance in the initial evaluation of MO secondary to RVO.

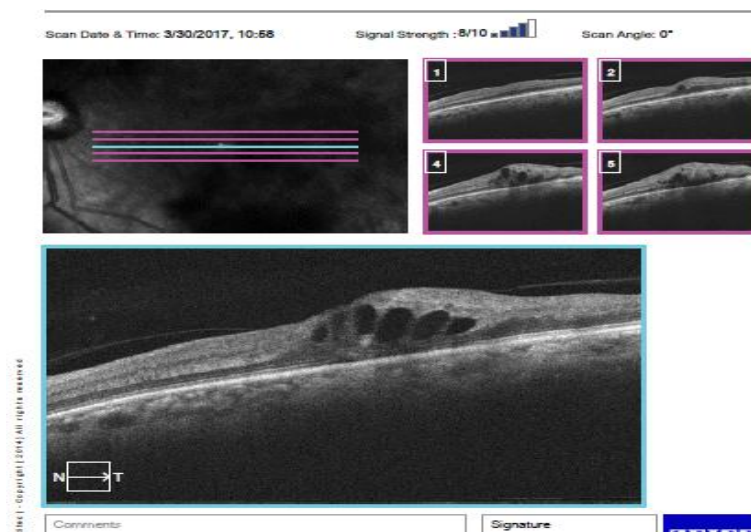
Macular thickness analysis permits a quantitative evaluation of retinal thickness and volume. OCT computer algorithms define the inner retina and outer retina boundaries and calculate retinal thickness and volume.

Traditional methods of assessing macular oedema (ME) include contact and non-contact slit lamp biomicroscopy, indirect ophthalmoscopy, fluorescein angiography and fundus stereo photography. However, since the introduction of optical coherence tomography (OCT) in 1991, it has become an invaluable tool in the diagnosis and management of different retinal disorders including ME<sup>1</sup>. OCT is a non-contact, micron-level, high-resolution diagnostic method that uses infrared light in the 800–840 nm wavelength range to provide real-time non-invasive imaging of the retina. OCT is based on the principal of Michelson interferometry. An interference pattern is produced by splitting a beam of light into two paths, bouncing the beams back (one from the targeted tissue, the other from a reference mirror) and recombining them by using semitransparent mirrors<sup>2</sup>. OCT measurements are similar to those of ultrasound B-mode examinations, but have much higher resolution since light is used instead of sound waves. Ultrasound B-mode examinations have a resolution of 150  $\mu$ , while current OCT scanners have less than 5  $\mu$  resolution. Spectral or Fourier domain OCT technology has replaced the older, and slower, time domain OCT. SD OCT could acquire images at higher rates up to 20 000 axial scans per second with almost 5  $\mu$ m resolution

At present OCT is considered essential in the management of RVO in order to evaluate the presence of ME and its complications as well as the response to treatment. Furthermore, it is the most useful procedure to establish the presence of a tractional component.

The OCT software measures retinal thickness automatically while it is evaluating variations and deviations from the normal values. The distance between the vitreoretinal interface and the anterior surface of the retinal pigment epithelium is generally 200–275  $\mu$ . The foveal depression ranges from 170 to 190  $\mu$ . The mean thickness measured by OCT in the peripheral retina is generally 220–280  $\mu$ . Using several mathematic algorithms, cube scans also allow measurement of the volume of the macula. Images acquired with OCT today have been found to correlate well with retinal histology as demonstrated with light microscopy<sup>3</sup>. Furthermore, topographical studies have shown that subclinical ME caused by different diseases may only be detected by OCT.

### III. OCT in patient with OS BRVO with macular edema



### IV. Patients And Methods

In this study, spectral domain OCT scan with PRIMUS-200(Zeiss) was performed in 50 patients with Central and Branch retinal vein occlusions to evaluate macular edema.

### V. Aims And Objectives

1. To correlate the Ophthalmoscopy findings with that of OCT findings.
2. To quantitate the macular thickening in cases of retinal vein occlusion with macular edema.

### VI. Inclusion Criteria

Patients who were diagnosed Ophthalmoscopically ,as having Central retinal vein occlusion, Branch retinal vein occlusion with or without macular edema .

### VII. Exclusion Criteria

Patients with significant media opacities that can cause poor OCT signal, patients with other pathologies that cause macular edema like diabetic retinopathy, ARMD, CSCR etc.

### VIII. Procedure

1. A complete ophthalmological examination was performed in all patients which includes BCVA, slit lamp biomicroscopy,+78 D/ +90 D fundus examination, indirect opthalmoscopy and stereophotography.
2. A spectral domain OCT scan was performed through a dilated pupil.
3. Macula was scanned in horizontal and vertical meridians.
4. Foveal thickness was assessed by automated method.
5. Macular edema is considered to be present, when the foveal thickness is more than  $212 \pm 23$  microns and extrafoveal thickness more than  $212 \pm 20$  microns.

### IX. Results

Out of 50 Patients, 44 patients were diagnosed to be BRVO & 6 Patients were diagnosed to be CRVO

Total no of patients	Patients with BRVO	Patients with CRVO
50	44(88%)	6(12%)

### X. Age Distribution

#### 9.1 BRVO(44 cases):

Out of 44 patients with BRVO, 32 were females and 12 were males. Age of the patients included in the study ranged between 44 and 70 years. Mean age of our study is 66.8yrs. Majority of the pts falling under the age group of 61-70(around 54.5%).Female population was more in the present study than male population.

Age group	Male	Female	Total cases
41-50 years	2	6	8
51-60 years	3	7	10
61-70 years	6	18	24
>70 years	1	1	2

#### 9.2 CRVO(6 CASES):

Out of 6 patients with CRVO, 4 were females and 2 were males

Age group	Male	Female	Total cases
41-50years	0	1	1
51-60 years	0	1	1
61-70 years	2	2	4
>70 years	0	0	0

### XI. Macular Edema on OCT

Out of 50 cases with Retinal vein Occlusions , 37 (74%) patients presented with macular edema clinically and confirmed on OCT.

Total no of RVO cases	Macular Edema	
50	CONFIRMED	NOT SIGNIFICANT
	37(74%)	13(26%)

All 6 cases of CRVO showing macular edema clinically was confirmed on OCT.

31 cases of BRVO, out of 44 patients showing Macular edema clinically was confirmed on OCT.

Retinal vein occlusion(50 cases)		
CRVO(6 cases)	BRVO(44 cases)	
MACULAR EDEMA		
	CONFIRMED ON OCT	NOT SIGNIFICANT
6(100%)	31(70.45%)	13(29.54%)

### XII. Macular Thickness On Oct:

1. Average macular thickness in 6 cases of CRVO is 501.6  $\mu$ .
2. Average macular thickness of 37 cases of BRVO with Macular Edema is 462.38 $\mu$ .
3. In the remaining 13 cases, Macular thickness was within normal limits.

### XIII. Summary

In the present study, out of 50 patients having retinal vein occlusions, 6 patients were diagnosed having CRVO & 44 patients were diagnosed having BRVO. 37 patients were diagnosed as having macular oedema clinically & confirmed on OCT and were managed accordingly.

### XIV. Discussion

In this current study, 50 patients with retinal vein occlusions were evaluated for the presence of Macular oedema clinically and confirmation of the same on OCT. Out of 50 patients, 44 patients were diagnosed to be BRVO and 6 patients were diagnosed to be CRVO. Out of 44 patients with BRVO, 32 were females and 12 were males. Age of the patients included in the study ranged between 44 and 70 years. Mean age of our study is 66.8yrs. Majority of the pts falling under the age group of 61-70(around 54.5%).Female

population was more in the present study than male population. Out of 6 patients with CRVO, 4 were females and 2 were males.

Out of 50 cases with Retinal vein Occlusions, 37 (74%) patients presented with macular edema clinically and confirmed on OCT. All 6 cases of CRVO showing macular edema clinically was confirmed on OCT. 31 cases of BRVO, out of 44 patients showing Macular edema clinically was confirmed on OCT.

### **XV. Conclusions**

OCT is a useful tool in the evaluation of the characteristics of Macular oedema and setting the indications of treatment. OCT has broadened our basic understanding and interpretation of ME and vitreo-retinal interface disorders. It allows early, accurate diagnosis and better follow-up. OCT is now being used routinely in common diseases like diabetic retinopathy, Vein Occlusions and age-related macular degeneration. In our daily practice, OCT has become today an invaluable tool in assessing the response to treatment and for the first time we have qualitative and quantitative data of the retinal thickness that we can correlate with visual acuity.

Regular OCT examinations can be useful in the early detection of an impending drop in BCVA and in the indication for repeated therapy. Central foveal point thickness determined by OCT represents a useful tool for the detection and monitoring of RVO but cannot reliably substitute for visual acuity measurement. In summary, this new non-invasive imaging method is essential in accurately evaluating ME and guide treatment.

### **References**

- [1]. Huang D, Swanson EA, Lin CP, *et al* Optical coherence tomography. *Science* 1991;**254**:1178–81.
- [2]. Puliafito CA, Hee MR, Lin CP, *et al* Imaging of macular diseases with optical coherence tomography. *Ophthalmology* 1995;**102**:217–29.
- [3]. Hee MR, Izatt JA, Swanson EA, *et al* Optical coherence tomography of the human retina. *Arch Ophthalmol* 1995;**113**:325–328.
- [4]. Abegg M, Tappeiner C, Wolf-Schnurrbusch U, Barthelmes D, Wolf S, Fleischhauer J (2008) Treatment of branch retinal vein occlusion induced macular edema with bevacizumab. *BMC Ophthalmol* 8:18.
- [5]. Ahmadi AA, Chuo JY, Banashkevich A, Ma PE, Maberley DA (2009) The effects of intravitreal bevacizumab on patients with macular edema secondary to branch retinal vein occlusion. *Can J Ophthalmol* 44:154-159.

\*Dr.P.Rajasekhar. “A Clinical Study on “Role of Optical Coherence Tomography(Oct) in The Evaluation of Macular Edema in Retinal Vein Occlusions”.” IOSR Journal of Dental and Medical Sciences (IOSR-JDMS), vol. 16, no. 12, 2017, pp. 58–62.