

Isolated Jejunal Diverticulosis an Incidental Finding: A Case Report

Dr Hitesh Kumar¹, Dr Satish Sheoran²

¹Senior resident, Department of General Surgery, NDMC Medical College & Hindu Rao Hospital, New Delhi, India

²Specialist, Department of General Surgery, NDMC Medical College & Hindu Rao Hospital, New Delhi, India
Corresponding author: Dr Hitesh Kumar

Abstract: Jejunal diverticulosis is a rare entity involving small bowel. The condition is usually asymptomatic and diagnosed incidentally, although it may cause chronic symptoms and acute complications. Because of the rarity of the condition, diagnosis is often delayed. The condition should be suspected in cases of unexplained chronic pain abdomen and malabsorption to avoid unnecessary mortality and morbidity. We are thereby reporting a 40 yr old male patient who presented to surgical emergency with acute abdomen. He used to take NSAIDS for chronic back pain. On exploration thin walled jejunal diverticulae of size 5x5 cm were observed along with a prepyloric gastric perforation. Modified graham's omental patch repair was done for the gastric perforation, decision for conservative approach was made for diverticulosis segment. During the followup OPD visits, patient underwent upper GI endoscopy, colonoscopy, Barium meal follow through and USG abdomen. Barium meal follow through showed multiple diverticulae, rest all investigations were normal. Patient was followed up for 10 months postoperatively and no complications were observed. Thus we concluded that incidentally diagnosed diverticulosis could be left alone without any intervention, managing chronic symptoms medically.

Keywords: Jejunal diverticulosis, gastric perforation, exploratory laparotomy, NSAIDS

Date of Submission: 15-01-2018

Date of acceptance: 03-02-2018

I. Introduction

Jejunal diverticulosis is a rare entity involving small bowel. The condition is usually asymptomatic, although it may cause chronic symptoms and acute complications. Because of the rarity of the entity, diagnosis is often delayed. The condition should be suspected in cases of unexplained chronic pain abdomen and malabsorption to avoid unnecessary mortality and morbidity. We are thereby reporting a 40 yr patient on chronic NSAID ingestion presenting to us with acute abdomen, on exploration of which there was prepyloric gastric perforation with isolated jejunal diverticulosis.

II. Case Report

A 40-year old male patient presented to surgical emergency with pain epigastric region for last 3 days. Pt complained of epigastric discomfort for the last 3-4 yrs. He was suffering from low back pain for which he used to take tablet Diclofenac sodium by himself which was previously prescribed by some local practitioner. On examination he was thinly built. His pulse was 108 beats per minute, BP 116/74mm of Hg and temperature was 101°F. Examination of the abdomen revealed abdominal distension, guarding and rigidity was positive, tenderness and rebound tenderness was present in all quadrants of the abdomen. Bowel sounds were absent. X-ray abdomen and chest revealed free gas under diaphragm bilaterally. His white blood cell count was 18000/mm³ and hemoglobin level was 15.0 gm/dL. Rest all biochemical parameters were normal. Per rectal examination was normal. The patient was optimized and planned for exploratory laparotomy.

On exploration of abdomen about 1500 ml of greenish fluid with pus flakes was drained from abdominal cavity. 0.5x 0.5 cm pre-pyloric gastric perforation was noted. Multiple thin walled jejunal diverticulae of size 5x5 cm were observed, starting from 30 cm from duodeno-jejunal junction till proximal ileum. About 90 cm of small bowel was involved in diverticulosis. Diverticulae were 9 in number, located on both mesenteric and antimesenteric border of the jejunum. A few of diverticulae were having budded appearance.

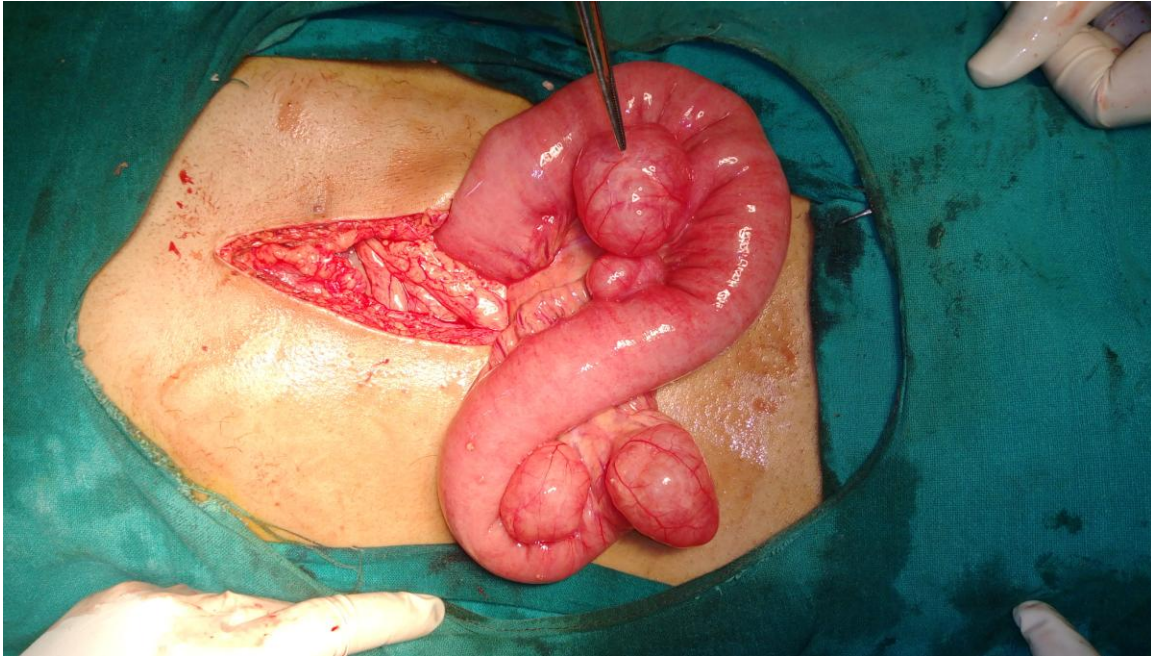


Figure 1

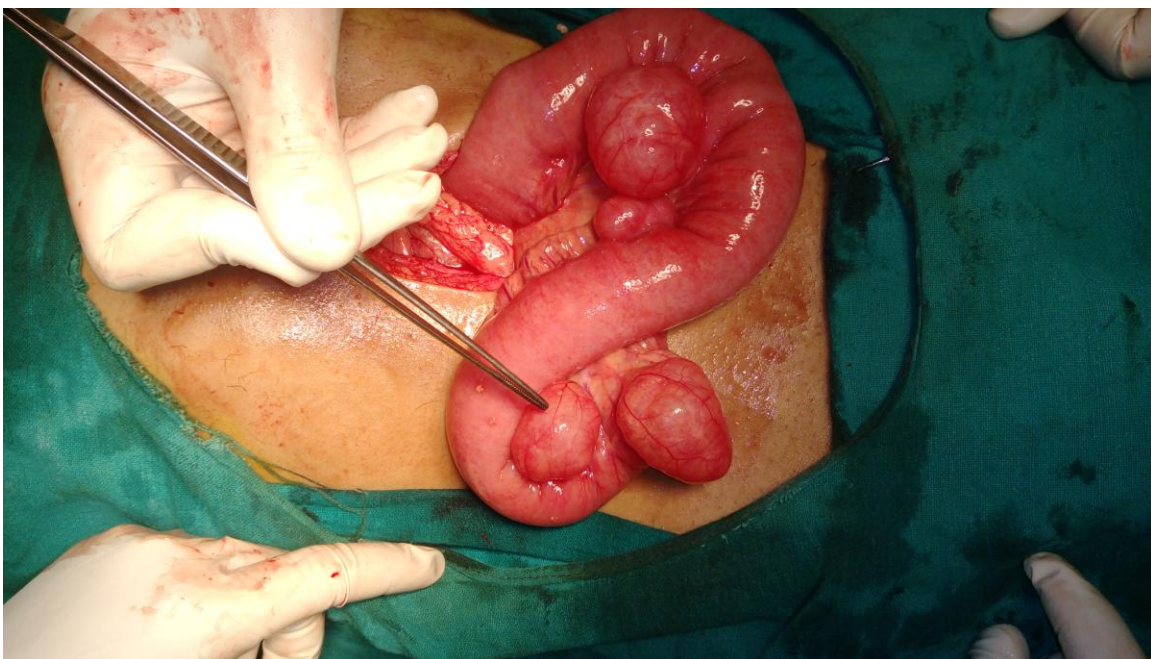

Figure 2

Modified graham's omental patch repair was done for the gastric perforation after freshening the margins. Although diverticulae were thin walled but bowel looked healthy, so decision for conservative approach was made. Rest all bowel and solid organs were grossly normal. Ryle's tube was inserted and abdominal drain was placed in pelvic cavity. Postoperative period was uneventful. He was orally allowed on 4th day. Drain was removed on 5th post-op day. He was discharged on 6th post-op day to be reviewed in OPD.

During the OPD visits, patient underwent upper GI endoscopy, colonoscopy, Barium meal follow through and USG abdomen. Barium meal follow through showed multiple diverticulae, rest all investigations were normal. Patient was followed up for 10 months postoperatively and no complications were observed. His chronic symptoms were successfully managed medically. Medical management includes low residue diets, antispasmodics, antacids, analgesics and vitamin B12 supplementation.

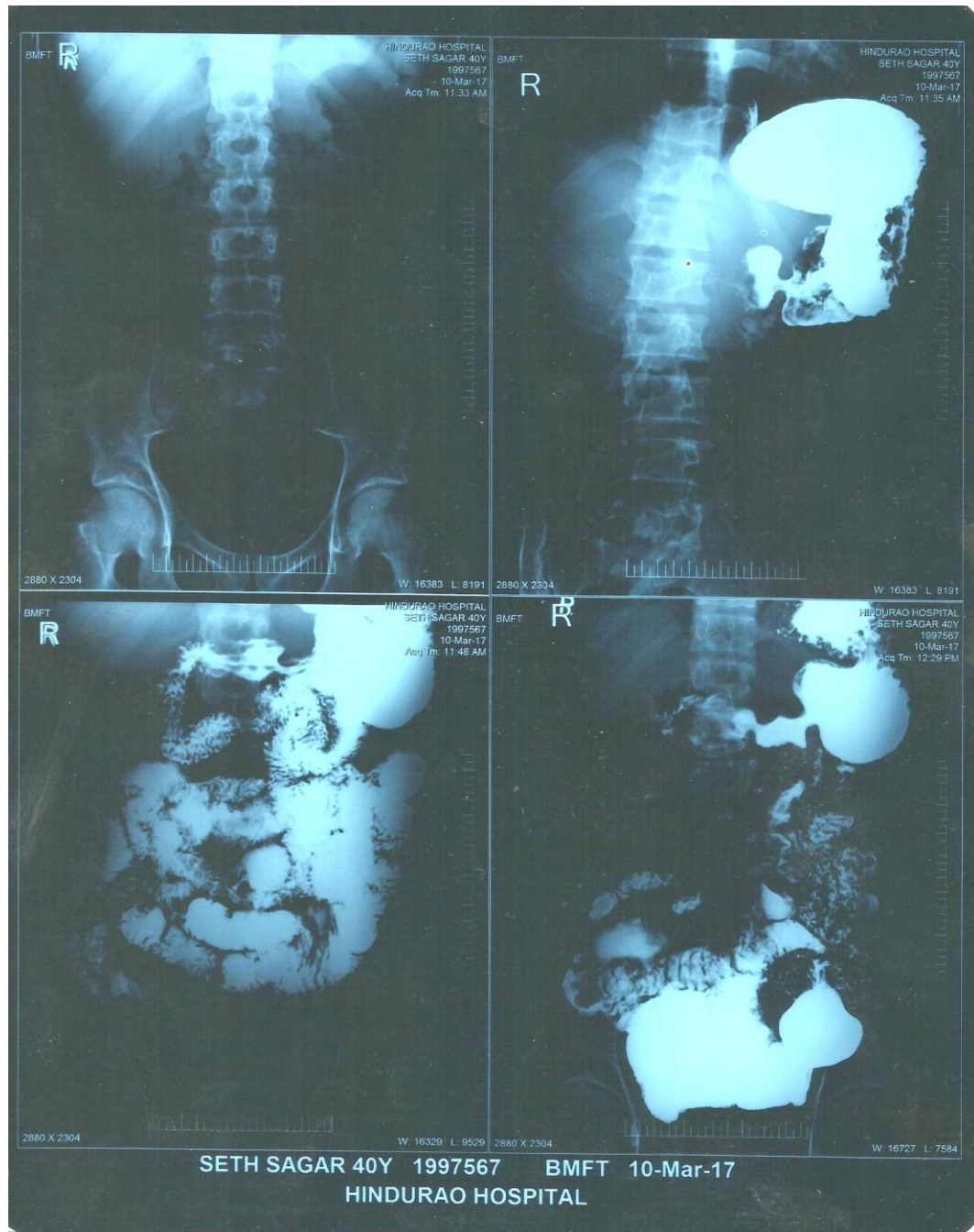


Figure 3

III. Discussion

History of jejunal diverticula dates back to 1794 when Somerling first time described the condition followed by Sir Astley Cooper in 1807.¹ Jejunal diverticula are the least common of all the small bowel diverticula having an incidence ranging from 0.002 -5% based on post mortem and enteroclysis studies.²

Over 80% of jejunal diverticula occur in patients 70 years and older,³ But in our case patient's age is 40 yrs. Jejunal diverticula are acquired pseudodiverticula believed to be caused by jejunoileal dyskinesia leading to increased intraluminal pressure and herniation of the mucosa and submucosa through the weakest point. Hence they are more commonly on the mesenteric border.² But in our case the jejunal diverticulatae were noted on both the mesenteric and antimesenteric borders of the jejunum. The diverticula can be single (33%) or multiple (66%) and located in the jejunum (55-88%), ileum (15-38%), or both (5-7%).⁴

Usually the patients with jejunal diverticula have other coexisting gastrointestinal diverticula including colon (20-70%), duodenum (10-40%), esophagus and stomach (2%) which highlights a common potential etiology.^{5,6} In our case no coexisting diverticula were noted anywhere else.

The diagnosis of jejunal diverticula is often challenging because most patients are asymptomatic (70%) or presents with vague abdominal pain and there is no gold standard investigation to diagnose the condition. The commonest GI diverticulum is sigmoid colon diverticulum.

The disease is often asymptomatic or present with vague abdominal symptoms like nausea, vomiting, post prandial bloating sensation, weight loss, fatigue and failure to thrive. These patients often go undiagnosed for quiet a long period.^{4,7} In our case patient was complaining of recurrent epigastric pain for last 3 yrs.

Frequently chronic symptoms of jejunal diverticula are successfully managed medically. Medical management includes low residue diets, antispasmodics, antacids, analgesics and vitamin B12 supplementation. If medical management fails, patient may be considered for resection of involved segment and end to end anastomosis.² About 10-19% cases of jejunal diverticula present as case of acute abdomen resulting from perforation, hemorrhage from diverticulum, obstruction, fistula formation and abscess formation.⁸

Many patients are diagnosed incidentally and there are no signs of inflammation or scarring and the diverticulum involves a long stretch of intestine hence a conservative approach is taken. In our case although the diverticulae were quiet thin walled but had no signs of inflammation so carefully repositioned back to the peritoneal cavity. Tsiotos et al. analysed a total of 112 cases of jejunoileal diverticulosis and of these, 42% of cases were asymptomatic. The remaining patients had symptoms of diarrhea (58%), chronic abdominal pain (51%) or bloating sensation (44%). Interestingly Tsiotos et al. found an association with Raynaud's phenomenon and systemic sclerosis.⁹

Complication rates as high as 46% for jejunoileal diverticulosis have been reported and are known to be fatal many times.¹⁰ Because of more acute complications such as perforation, peritonitis, bleeding, and fistula formation. Largest study till date was a review by Chendrasekhar et al.¹¹ in 1995, they provided individual patient data for all case reports that were previously published, a total of 22 patients between 1971 and 1994¹¹

In our case, based upon the clinical findings along with radiological findings and history of long term use of NSAIDS, patient was suspected of gastric perforation with peritonitis, on exploration isolated jejunal diverticulae were noted because of the non availability of other investigations in emergency department, patient was further evaluated with Barium meal follow through, upper GI endoscopy, colonoscopy and USG abdomen in post operative period. Barium meal follow through showed multiple diverticulae rest all investigations were normal. Patient was followed up for 10 months postoperatively and no complications were observed. HPE report stated non specific acute inflammation

IV. Conclusion

Jejunal diverticulosis is a relatively rare condition and when diagnosed incidentally on exploratory laparotomy for any other cause post operative morbidity and mortality can be reduced by leaving the condition undisturbed. The chronic nonspecific symptoms can be managed by medical treatment alone and keeping the patient under regular follow up.

Acknowledgement

Nil

References

- [1]. Williams R.A., Davidson D.D., Serota A.I., Wilson S.E. Surgical problems of diverticula of the small intestine. *Surg. Gynecol. Obstet.* 1981;152:621-626.
- [2]. Michael J Zinner, Stanley W Ashley, Jejunoileal diverticula. In; *Maingot's Abdominal Operations*: 12th edition: The McGraw Hill Companies, Inc. 2013. p. 642-643.
- [3]. Ross C.B., Richards W.O, Sharp K.W. Diverticular disease of the jejunum and its complications. *Am. Surg.* 1990; 56(5):319-324.
- [4]. Woods K, Williams E, Melvin W, Sharp K. Acquired jejunoileal diverticulosis and its complications: a review of literature. *Am Surg.* 2008;74:849-854.
- [5]. Kassahun WT, Fangmann J, Harms J, et al. Complicated small bowel diverticulosis: a case report and review of literature. *World J Gastroenterol.* 2007;13:2240-2242.
- [6]. Wilcox RD, Shatney CH. Surgical significance of acquired ileal diverticulosis. *Am Surg.* 1990;56:222-225.
- [7]. Makris K, Tsiotos GG, Stafyla V, et al. Small intestinal nonmeckelian diverticulosis. *J Clin Gastroenterol.* 2009;43:201-207.
- [8]. Akhrass R., Yaffe M.B., Fischer C., Ponsky J., Shuck J.M. Small bowel diverticulosis: perceptions and reality. *J. Am. Coll. Surg.* 1997;184:383-388.
- [9]. Tsiotos G.G., Farnell M.B., Ilstup D.M. Non-Meckelian jejunal or ileal diverticulosis: an analysis of 112 cases. *Surgery.* 1994;116:726-732.
- [10]. Davies N.M., Saleh J.Y., Skjodt N.M. Detection and prevention of NSAID-induced enteropathy. *J. Pharm. Pharmaceut. Sci.* 2000;3:137-155.
- [11]. Chendrasekhar A., Timberlake G.A. Perforated jejunal diverticula:an analysis of reported cases. *Am. Surg.* 1995;61:984-988.

Dr Hitesh Kumar "Isolated Jejunal Diverticulosis an Incidental Finding: A Case Report." IOSR Journal of Dental and Medical Sciences (IOSR-JDMS), vol. 17, no. 2, 2018, pp. 10-13.