

Unusual Complete Resolution of Mobile Left Ventricular Thrombus with Low Molecular Weight Parenteral Heparin

Dr. SANDHEEP GEORGE VILLOTH¹, DR.S. THANIKACHALAM²

¹Academic Degrees: Md (General Medicine), Senior Registrar Institution: Sri Ramachandra University, Sri Ramachandra Medical College & Research Institute, Porur, Chennai – 600 116.

²Academic Degrees: Md (General Medicine), Dm(Cardiology), Fiacs, Institution: Sri Ramachandra University, Sri Ramachandra Medical College & Research Institute, Porur, Chennai – 600 116.

Corresponding Author: Sandheep George Villoth

Abstract: Left ventricular thrombus (LVT) formation post myocardial infarction (MI) particularly after anterior wall MI is well known to occur. The incidence of LVT formation is still a frequent complication even today despite of the prevailing aggressive reperfusion therapy options available. Occurrence of LVT can be related to deterioration in left ventricular (LV) function, ventricular aneurysm or ventricular dyskinesia. Echocardiography still remains the most commonly used diagnostic methodology for detecting LVT but the current gold standard is contrast induced magnetic resonance imaging. Mural and mobile thrombi have an increased risk of systemic embolization. Current guidelines state patients with LVT or who are at high risk to develop the same are to be treated with oral anticoagulants for at least 3 months. Here we report a case of a young male, post MI status diagnosed to have LVT and subsequently developed lower limb arterial thrombosis which completely resolved with anticoagulation therapy in 2 weeks.

Keywords: LV THROMBUS; RESOLUTION; EARLY DISAPPEARANCE; LV CLOT; LOW MOLECULAR WEIGHT HEPARIN.

Date of Submission: 23-05-2018

Date of acceptance: 05-06-2018

I. Introduction

Left ventricular thrombus (LVT) formation post myocardial infarction (MI) particularly after anterior wall MI is well known to occur. The incidence of LVT formation is still a frequent complication even today despite of the prevailing aggressive reperfusion therapy options available. Occurrence of LVT can be related to deterioration in left ventricular (LV) function, ventricular aneurysm or ventricular dyskinesia. Echocardiography still remains the most commonly used diagnostic methodology for detecting LVT but the current gold standard is contrast induced magnetic resonance imaging. Mural and mobile thrombi have an increased risk of systemic embolization. Current guidelines state patients with LVT or who are at high risk to develop the same are to be treated with oral anticoagulants for at least 3 months. Here we report a case of a young male, post MI status diagnosed to have LVT and subsequently developed lower limb arterial cardio embolic thrombosis which completely resolved with anticoagulation therapy.

II. Case Report

25yr old male technology student without risk factors, had suffered anteroseptal myocardial infarction (MI) 4 yrs ago, underwent primary percutaneous coronary angioplasty (PCI) to mid left anterior descending artery with one drug eluting stent. 2 D echocardiography done at that point showed preserved left ventricular (LV) function with anteroseptal hypokinesia, no gross remodeling of LV and absence of LV clot. After 4 yrs of gap, he presented with a complaint of sudden leg pain due to bilateral embolization to anterior tibial and peroneal arteries. After continuing dual antiplatelets which he started 4 yrs ago, he had stopped them for the last 2 yrs. Repeat 2 D echocardiography revealed regional wall motion abnormality, LV ejection fraction of 40 % and a LV apical mobile clot of 0.7 x 0.7 cm with central clearance (Figure 1). CT lower limb peripheral angiogram revealed occlusion of left and right tibial and peroneal arteries. He was initiated with low molecular weight heparin 40mg twice a day along with dual antiplatelets in the hospital for a total duration of 5 days and he was discharged. Procoagulant workup revealed hyperhomocysteinemia with level above 50ng, for which he was started on vitamin B12 and folic acid supplementation. Follow up repeat 2D echocardiography after 2 weeks showed complete resolution of LV thrombus (Figure 2), with no more symptoms of peripheral embolization.

III. Discussion

The pathogenesis behind the formation of LVT pertains to the backdrop of either acute MI resulting in LV dysfunction associated with dyskinesia, aneurysmal deformation of the LV apex, or dilated cardiomyopathy. The incidence of LV thrombus among acute MI in the pre-reperfusion era was as high as 40%. [2,6] Recent studies on STEMI patients treated with various reperfusion modalities showed an incidence of LVT of 4 to 8%. [4,5,11] The majority of high risk category patients to develop LVT were found to have common clinical risk factors which includes extensive anterior wall ST elevation MI involving the LAD territory and a resultant moderate to severe LV dysfunction.

In patients with high suspicion but insufficient echocardiographic evidence of LVT must undergo cardiovascular magnetic resonance (CMR) with gadolinium contrast for confirmation.

The risk of systemic embolization in the form of cardio embolic stroke and acute limb ischemia is as high as 15% without anticoagulant therapy. The majority of the events were found to occur within the first three to four months of initial MI presentation. [3,7,8,9] A few case reports have postulated that hypercoagulable states can be identified as an independent risk factor for the formation of LVT and increased CAD risk in Asian Indians. [10]

American College of Cardiology/ American Heart Association and European Heart Journal guidelines state that patients with acute MI and LVT with increased risk of thromboembolism needs to be treated initially with parenteral anticoagulation, later with oral anticoagulants for 3 to 6 months duration to maintain a goal INR range of 2 to 3 along with single antiplatelet therapy in non PCI patients and dual antiplatelet therapy in PCI patients. Due to the risk of LVT reformation in patients with poor LV function, the continuation of anticoagulant therapy is highly recommended despite primary resolution provided benefit of prevention of thromboembolism exceeds that of bleeding.

In three of the follow up studies done previously with serial echocardiograms, resolution of thrombus was noted in 47% of patients at six months, 47% of patients at one year and 76% of patients at two years follow up. [1,2,3]

IV. Conclusion

In this report we present a patient with underlying hypercoagulable state (hyperhomocysteinemia) with a past history anterior wall STEMI treated with PCI, subsequently developed LVT and suffered acute limb thrombosis as a result of cardio embolic phenomenon; was successfully treated with anticoagulant therapy leading to complete resolution of LV clot.

In post ST elevation MI patients, the occurrence of LVT is still at large. Early detection and immediate treatment with anticoagulants is vital to prevent thromboembolic complications.

References

- [1]. Nesković AN, Marinković J, Bojić M, Popović AD. Predictors of left ventricular thrombus formation and disappearance after anterior wall myocardial infarction. *Eur Heart J* 1998; 19:908.
- [2]. Nihoyannopoulos P, Smith GC, Maseri A, Foale RA. The natural history of left ventricular thrombus in myocardial infarction: a rationale in support of masterly inactivity. *J Am Coll Cardiol* 1989; 14:903.
- [3]. Keren A, Goldberg S, Gottlieb S, et al. Natural history of left ventricular thrombi: their appearance and resolution in the posthospitalization period of acute myocardial infarction. *J Am Coll Cardiol* 1990; 15:790.
- [4]. Rehan A, Kanwar M, Rosman H, et al. Incidence of post myocardial infarction left ventricular thrombus formation in the era of primary percutaneous intervention and glycoprotein IIb/IIIa inhibitors. A prospective observational study. *Cardiovasc Ultrasound* 2006; 4:20.
- [5]. Gianstefani S, Douiri A, Delithanasis I, et al. Incidence and predictors of early left ventricular thrombus after ST-elevation myocardial infarction in the contemporary era of primary percutaneous coronary intervention. *Am J Cardiol* 2014; 113:1111.
- [6]. Weinreich DJ, Burke JF, Pauletto FJ. Left ventricular mural thrombi complicating acute myocardial infarction. Long-term follow-up with serial echocardiography. *Ann Intern Med* 1984; 100:789.
- [7]. Stratton JR, Resnick AD. Increased embolic risk in patients with left ventricular thrombi. *Circulation* 1987; 75:1004.
- [8]. Cregler LL. Antithrombotic therapy in left ventricular thrombosis and systemic embolism. *Am Heart J* 1992; 123:1110.
- [9]. Vaitkus PT, Barnathan ES. Embolic potential, prevention and management of mural thrombus complicating anterior myocardial infarction: a meta-analysis. *J Am Coll Cardiol* 1993; 22:1004.
- [10]. Boushey CJ, Beresford SA, Omenn GS. A quantitative assessment of Plasma homocysteine as a risk factor for cardiovascular disease: probable benefits of increasing folic acid intakes. *JAMA* 1995; 274, 1049-57.
- [11]. Weinsaft JW, Kim J, Medicherla CB, et al. Echocardiographic Algorithm for Post-Myocardial Infarction LV Thrombus: A Gatekeeper for Thrombus Evaluation by Delayed Enhancement CMR. *JACC Cardiovasc Imaging* 2016; 9:505.

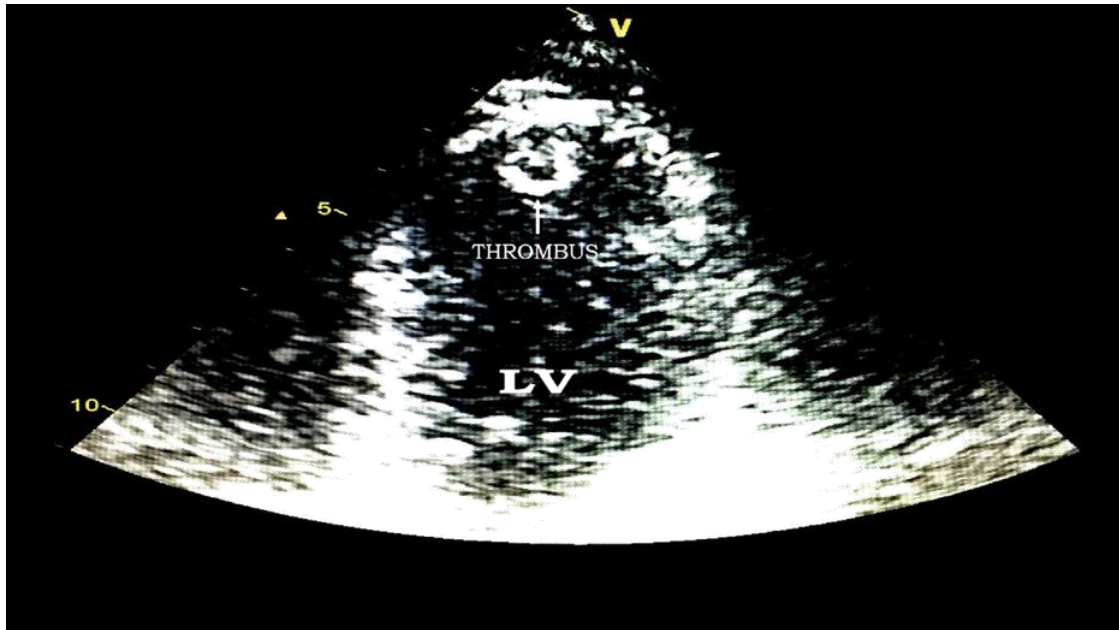


FIGURE 1: Echocardiographic 4 chamber view of the left ventricle during the initial presentation. Note the presence of the pedunculated LV apical thrombus protruding into the LV cavity.

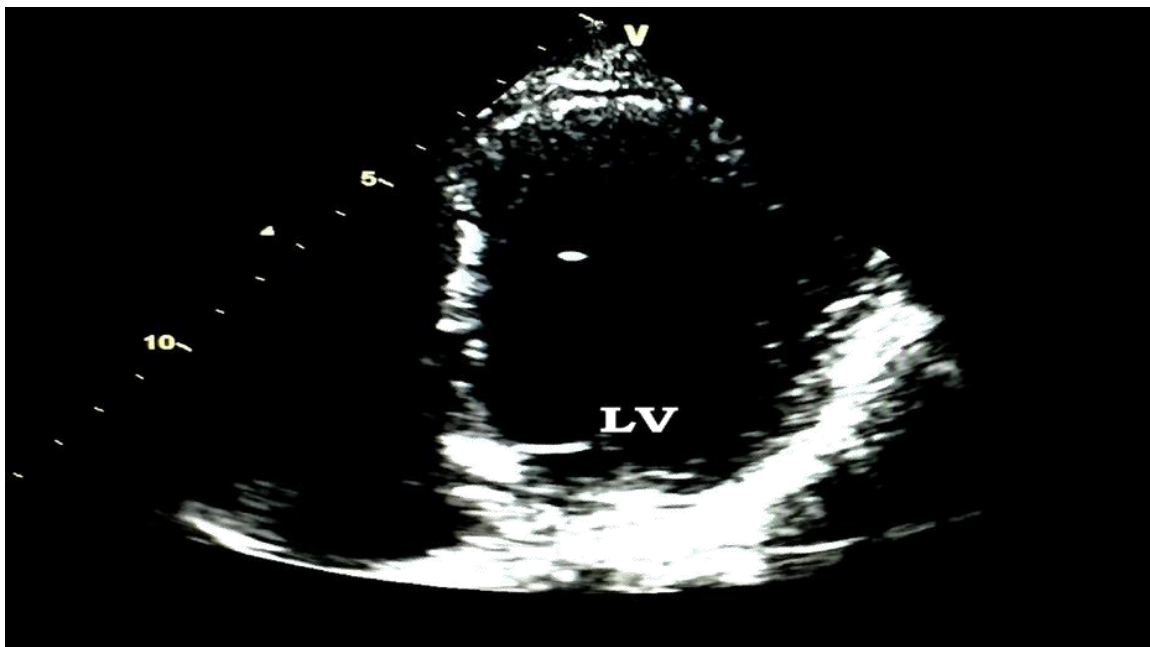


FIGURE 2: Echocardiographic 4 chamber view of the left ventricle during the follow up visit, 2 weeks later after being treated with low molecular weight heparin and dual antiplatelets. Note the complete resolution of the LV thrombus.

Sandheep George Villoth "Unusual Complete Resolution of Mobile Left Ventricular Thrombus with Low Molecular Weight Parenteral Heparin." "IOSR Journal of Dental and Medical Sciences (IOSR-JDMS), vol. 17, no. 6, 2018, pp 76-78.