

Imaging in Dental Implantology: A Review

Dr. Sourabh Sharma¹, Dr. Vivek Sharma², Dr. Meenakshi Khandelwal³,
Dr. Vikas Punia⁴, Dr. Saransh Malot⁵, Dr. Anand Porwal⁶.

¹ (Department of Prosthodontics, Darshan Dental College and Hospital, Udaipur, rajasthan, India)

² (Department of Prosthodontics, Darshan Dental College and Hospital, Udaipur, rajasthan, India)

³ (Department of Prosthodontics, Darshan Dental College and Hospital, Udaipur, rajasthan, India)

⁴ (Department of Prosthodontics, Darshan Dental College and Hospital, Udaipur, rajasthan, India)

⁵ (Department of Prosthodontics, Darshan Dental College and Hospital, Udaipur, rajasthan, India)

⁶ (Department of Prosthodontics, Darshan Dental College and Hospital, Udaipur, rajasthan, India)

Corresponding Author: Dr. Sourabh Sharma

Abstract: Dental radiology have completely revolutionized the field of dentistry. For successful implant treatment, a presurgical treatment planning is most important. For this, diagnostic imaging plays a vital role. There are various imaging modalities available to aid in placing the implant in an appropriate location with relative ease and also get a predictable outcome. The various modalities described are intraoral radiography, cephalometric radiography, panoramic radiography, conventional tomography, computed tomography, cone-beam CT and magnetic resonance imaging. The choice of which imaging modality to use along with when to image, is dependent on a number of factors including determination of quality and quantity of bone to establish the most favorable position of implant placement, detection of anomalies or pathological lesions if present and availability at a reasonable cost to patient. In addition, patients exposure to radiation dose as low as possible should always be in priority during radiographic examinations. This article reviews the various imaging modalities available currently and their clinical applications for successful implant placement.

Keywords: Computed Tomography, Cone Beam Computed Tomography, Digital Radiography, Lateral Cephalometric Radiographs, Magnetic Resonance imaging, Panoramic Radiography.

Date of Submission: 20-06-2018

Date Of Acceptance: 04-07-2018

I. Introduction

Dental implants provide completely and partially edentulous patients the function and esthetics they had with natural dentition. It enables patients to regain normal masticatory function, esthetics, speech, smile and deglutition.¹

Imaging objectives are to provide the clinician with cross-sectional views of the dental arch for accurate visualization of spatial relationship of internal structures of the maxilla and mandible. Imaging studies should help to determine the optimum position of implant placement relative to occlusal loads.² Various imaging techniques have been used to evaluate bone quality, quantity and anatomic structures in relation to proposed implant sites.

Until late 1980s, conventional radiographic techniques such as intraoral, cephalometric and panoramic views had been the accepted standard. Since then, developments in cross-sectional imaging techniques, such as spiral tomography and reformatted computerized tomograms, have become increasingly popular in preoperative assessment and planning of implant patients. The advent and acceptance of 3-dimensional computed tomography (CT) and newer-generation lower-dose cone beam CT scan devices (CBCT) in combination with interactive treatment planning software provides the clinicians with the ability to truly appreciate each patient's anatomic reality.

Imaging options currently available includes intra-oral radiography, conventional extra-oral radiography, tomography, computed tomography (CT), cone beam computed tomography (CBCT), cone beam volumetric tomography (CBVT) and magnetic resonance imaging (MRI).³

When planning for dental implants and especially when guided surgical applications are considered, it is essential that the true 3-dimensional anatomic presentation is understood and that all adjacent vital structures be accurately visualized.⁴ This article is a compilation of various imaging modalities that are used for dental implant assessment in different stages of implant treatment and their application as well as diagnostic contribution to presurgical evaluation, treatment planning and post-operative assessment of dental implants.

II. Various Imaging Modalities

Imaging techniques provides the most accurate means by which the clinician can assess the morphologic features of proposed fixture site and evaluate the fixture in time after implantation. Several imaging techniques are currently available for pre-surgical and post-surgical examinations. These include both intraoral and extra-oral plain film and digital radiography. ⁴

2.1 Role of imaging in site assessment and treatment planning:

Imaging studies can include basic plain radiography as well as advanced studies such as computed tomography (CT) and reformatted cross-sectional, panoramic and 3D imaging.⁵ The mandibular canal, mental foramen are readily identified on panoramic and cross-sectional images, while the incisive canal is usually identifiable on cross-sectional images distal to the level of the mental foramen.⁶ The mental foramen, mylohyoid ridge and genial tubercle are identifiable on 3D images, on panoramic and cross-sectional reformatted images and on direct axial CT sections.

Another important aspect of radiologic evaluation should be a qualitative description of bone in a given area. Although there is no universally accepted system for classifying bone quality in maxilla and mandible, we routinely use the Misch system in evaluating cross-sectional reformatted images. The Misch system is widely divides bone into four subdivisions (D-1 to D-4) based on observed density.⁷

1. D-1 bone - characterized by thick, dense cortices surrounding densely calcified spongy bone, with little or no porosity; normally found in atrophic anterior mandibles.
2. D-2 bone - characterized by dense cortical plates; thick, coarse trabeculae; and small areolar spaces; normally found in the anterior maxilla and mandible and in the posterior mandible.
3. D-3 bone has thin cortical bone and poorly mineralized or thin trabeculae; found in anterior and posterior maxilla, in posterior mandible, and after osteoplasty of D-2 bone.
4. D-4 bone is characterized by thin or absent cortical plates with a paucity of mineralized trabeculae; often found in posterior maxilla or in post-osteoplasty D-3 bone.

Implants placed in either D-1 or D-2 bone stand an excellent chance of undergoing osseointegration, while implants placed in D-3 or D-4 bone either undergo fibro integration or fail to integrate at all.⁸

2.2 2-Dimensional Imaging Modalities -

Many imaging modalities have been reported as useful for dental implant imaging. These modalities can be described as analog or digital and two or three dimensional imaging. Most dentists are more familiar with analog two dimensional imaging.⁹ Types of two dimensional imaging modalities are as follows:

2.2.1 Periapical Radiography

Periapical radiography describes intraoral techniques designed to show individual teeth, implants and the tissues around the apices. Each film usually shows two to four teeth and provides detailed information about the teeth and surrounding alveolar bone.

Radiographic techniques:-

Two techniques for periapical radiography have been developed:

(i) Paralleling technique

1. The film packet is placed in a holder and positioned in mouth parallel to the long axis of implant under investigation.
2. The X-ray tubehead is then aimed at right angles (vertically and horizontally) to both the implant and the film packet.
3. By using a film holder with fixed film packet and X-ray tubehead positions, the technique is reproducible.

This positioning has the potential to satisfy most of the ideal requirements. However, the anatomy of palate and the shape of arches mean that the implant and the film packet cannot be both parallel and in contact. So, to prevent the magnification and distortion of the image, a large focal spot to skin distance can be achieved, by having a long spacer cone or beam-indicating device (BID) on the X-ray set. When x-ray is perpendicular to film but not to object, foreshortening will occur.⁹

(ii) Bisected angle technique

1. The film packet is placed as close to object under investigation as possible without bending the packet.
2. The angle formed between the long axis of object and long axis of the film packet is assessed and mentally bisected.
3. The X-ray tubehead is positioned at right angles to this bisecting line with the central ray of the X-ray beam aimed through the tooth apex.
4. Using the geometrical principle of similar triangles, the actual length of the object in mouth will be equal to the length of the object's image on the film.¹⁰

In terms of the objectives of presurgical imaging, periapical radiography is:

1. A useful high yield modality for ruling out local bone disease.
2. For visualization that is limited to mesiodistal and apicocoronal directions, and does not depict the third dimension of bone width.
3. Of limited value in determining bone density or mineralization.
4. Value in identifying critical structures but of little use in depicting spatial relationship between the structures and the proposed implant site.

2.2.2 Digital radiography

Digital radiology is an imaging process wherein the film is replaced by a sensor that collects the data. The analog information received is then interpreted by specialized software and an image is formulated on a computer monitor (Fig. 1). The resultant image can be modified in various ways, such as gray scale, brightness, contrast, and inversion. Computerized software programs (i.e., Dexis Implant) are now available that allow for calibration of magnified images.

The most current digital systems have significantly less radiation with superior resolution. The most significant advantage of digital radiography is the instantaneous speed in which images are formed, which is highly useful during surgical placement of implants and the prosthetic verification of component placement. These images can be manipulated, enhanced, stored and exchanged for referral and other purposes.¹¹ The only disadvantage is size and thickness of sensor that makes positioning of sensor difficult in some sites.

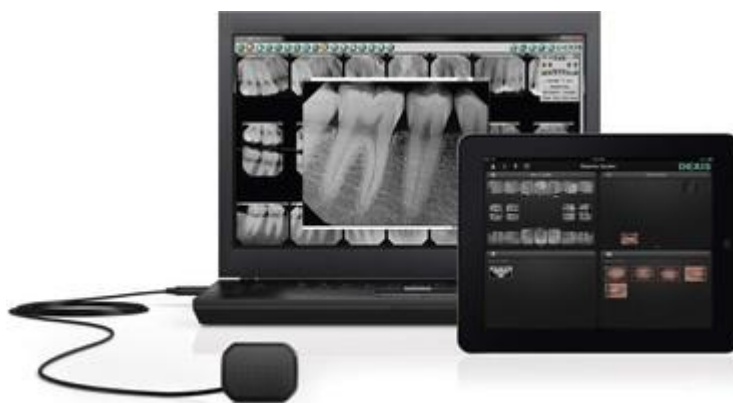

Fig. 1- Digital radiographic system includes digital sensor and computer.

1.2.3 Occlusal Radiography

Occlusal radiographs are planar radiographs produced by placing the film intra-orally parallel to the occlusal plane with central x-ray beam perpendicular to the film for mandibular image and oblique (usually 45°) to the film for maxillary image. Occlusal radiography produces high-resolution planar images of jaw bones.¹² Maxillary occlusal radiographs are inherently oblique and so distorted that they are of no quantitative use for implant dentistry for determining the geometry or the degree of mineralization of the implant site. In addition, critical structures such as the maxillary sinus, nasal cavity, and nasal palatine canal are demonstrated, but the spatial relationship to the implant site generally is lost with this projection.

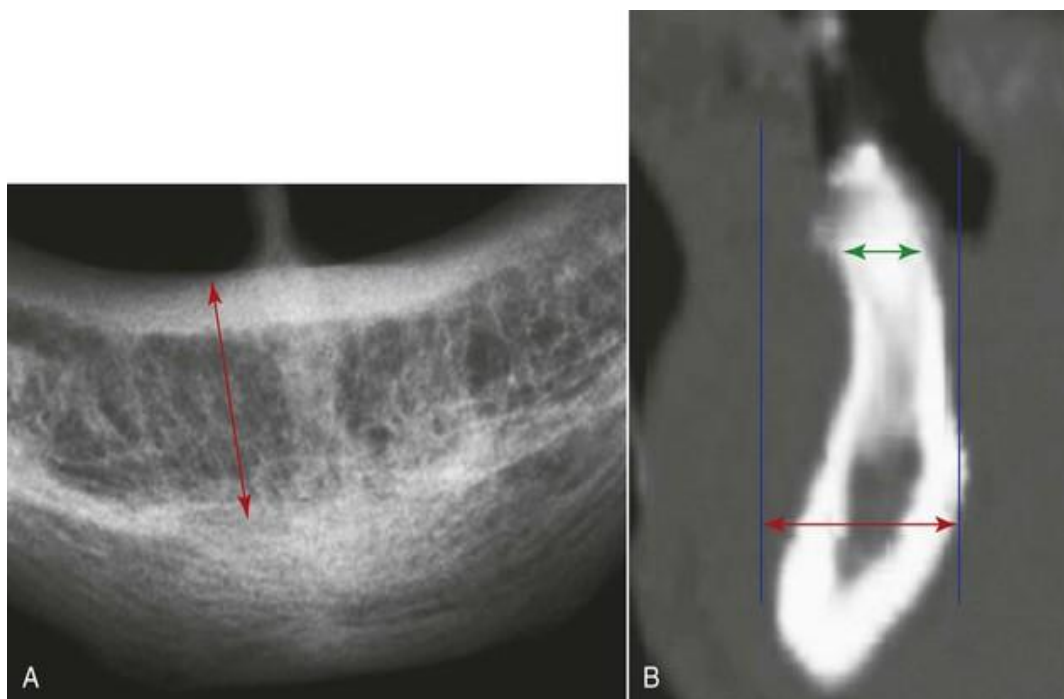


Fig. 2- (A) Occlusal radiographs showing the width of bone in the anterior region. (B) Occlusal radiographs actually showing the widest buccolingual distance (*red arrows*) not in the same plane. Actual width of bone (*green arrow*).

As the mandibular occlusal radiograph is an orthogonal projection, it is a less distorted projection than the maxillary occlusal radiograph. However, the mandibular alveolus generally flares anteriorly and demonstrates a lingual inclination posteriorly, producing an oblique and distorted image of the mandibular alveolus, which is of little use in implant dentistry. In addition, the mandibular occlusal radiograph shows the widest width of bone (i.e., the symphysis) versus the width at the crest, which is where diagnostic information is needed most (Fig. 2).¹³ The degree of mineralization of trabecular bone is not determined from this projection, and the spatial relationship between critical structures, such as the mandibular canal and the mental foramen, and the proposed implant site is lost with this projection. Therefore, occlusal radiographs rarely are indicated for diagnostic presurgical phases in implant dentistry.¹²

2.2.4Cephalometric Radiography

The skull is oriented to the x-ray device and the image receptor using a cephalometer, which physically fixes the position of skull with projections into the external auditory canal. The geometry of cephalometric imaging devices results in a 10% magnification of the image with a 60-inch focal object and a 6-inch object-to-film distance.¹¹

A lateral cephalometric radiograph is produced with the patient's midsagittal plane oriented parallel to the image receptor. The cross-sectional view of the alveolus demonstrates the spatial relationship between occlusion and esthetics with the length, width, angulation and geometry of alveolus and is more accurate for bone quantity determinations. The width of bone in the symphysis region and the relationship between the buccal cortex and the roots of anterior teeth also may be determined before this bone is harvested for ridge augmentation (Fig. 3).¹⁴ The lateral cephalometric view also can help evaluate a loss of vertical dimension, skeletal arch relationship, anterior crown-to-implant ratio, soft tissue profile, anterior tooth position in the prosthesis, and resultant moment of forces. However, this technique is not useful for demonstrating bone quality.

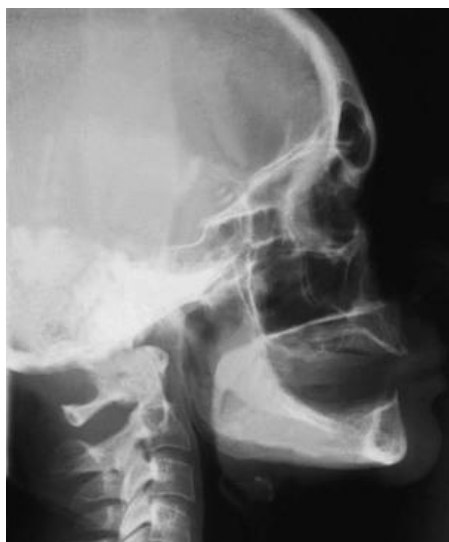

Fig. 3-A limited projection of mandibular symphysis region is useful for preoperative evaluation of the width of the bone in the midsymphysis.

2.2.5 Panoramic Radiography

Panoramic radiography is often the first choice method for the placement of implants because it provides information on the overall shape of the jaws, the position of maxillary sinus floor and the nasal cavity floor and the proximal distal as well as vertical position of mandibular canal and the mental foramen. It also provides information on the presence or absence of dental caries, tooth fractures, infections, residual dental roots or lesions in dental root apex or within the bone, the interval between remaining teeth, etc.¹⁵ Moreover, situations of bone resorption as well as radicular cysts, tumors, inflammation, post-accident fractures, temporomandibular joint disorders, and sinusitis can be identified. In addition, the patient is exposed to a low dose of radiation.

Panoramic radiography does not demonstrate bone quality or mineralization and is misleading quantitatively because of magnification. Because the third-dimension cross-sectional view is not demonstrated, the relationship between the vital structures and dimensional quantization of the implant site is not easily depicted.¹⁶

2.3 3-DIMENSIONAL IMAGING MODALITIES

Three dimensional imaging techniques are quantitatively accurate and three dimensional models of the patient's anatomy can be derived from the image data and used to produce stereotactic guides and prosthetic frameworks. 3D imaging techniques include:

2.3.1 Conventional Tomography

The basic principle of tomography is that when the system is energized, the x-ray tube moves in one direction with the film plane moving in the opposite direction and the system pivoting about the fulcrum. The fulcrum remains stationary and defines the section of interest, or the tomographic layer.¹⁷

Mainly, two types of tomographic movements are known: linear and multidirectional. The latter comprises four motions: Circular, spiral, elliptic and hypocycloidal are tube motions employed in complex tomography.¹⁸ In contrast to spiral and hypocycloid tomography, which have a constant magnification factor, linear tomography may have a non uniform magnification. Generally, the 3-dimensional dataset consists of 4 basic views: (1) the axial, (2) the cross-sections, (3) the panoramic reconstructed view and the 3-dimensional reconstructed volume. Each of these views is important, as no one view alone should determine the ultimate desired treatment.¹⁹

The cross-sectional view is important to help determine the quality of bone, the thickness of cortical plates, sinus pathology, periapical pathology, the trajectory of tooth within the alveolus and can aid clinicians in determining the topography of alveolus, root morphology and extent of any facial/buccal concavities (Fig. 4-A).²⁰

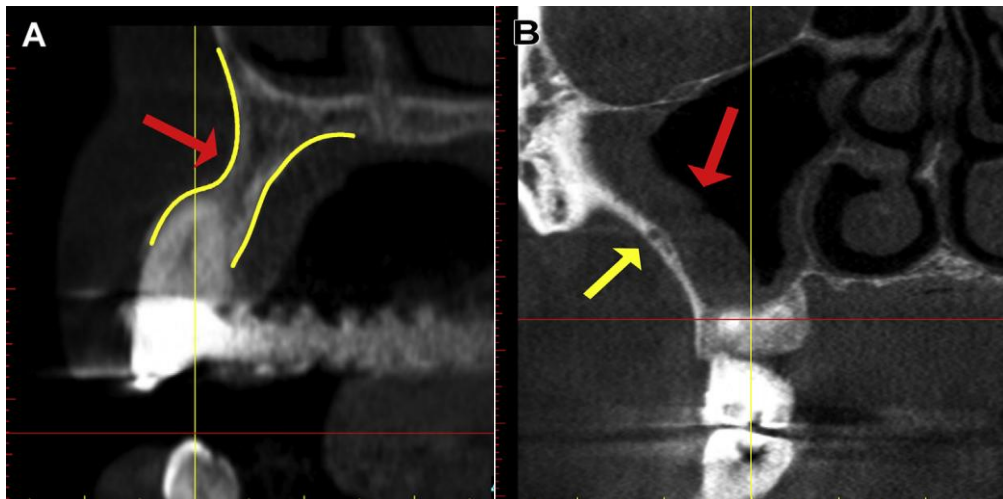


Fig. 4- (A) The cross-sectional image can aid clinicians in determining the topography of the alveolus, root morphology, and the extent of any facial/buccal concavities (red arrow).(B) In the posterior maxilla, the facial-palatal dimensions of the maxillary sinus can be fully appreciated as well as any sinus pathology or thickening of the Schneiderian membrane (red arrow) and the presence of intraosseous vessels (yellow arrow).

The posterior maxillary arch is another region in which cross-sectional imaging can provide anatomic details not visualized by any other means. The facial-palatal dimensions of the maxillary sinus can be fully appreciated as well (Fig. 4-B).Conventional tomography has certain limitations like overlapping of the shadows of tissues, less shades of gray and less resolution.

2.3.2 Computed Tomography

CT was invented by Housefield and the first CT scanners appeared in medical imaging departments during the mid 1970s and replaced complex tomography by the early 1980s.²¹CT is a digital medical technique, which can generate 3D images allowing the clinicians to visualize the bony architecture, nerves, joints, sinuses and other structures much more completely than traditional flat radiographs.²² The newer generation of CT scans provides images of a combination of soft-tissues, bone and blood vessels.²³

In dental implantology, computer programs are used to rearrange the data and reformat the series of axial images into oblique images along the curvature of bone of the alveolar ridges.²⁴ Used in critical anatomic situations and for placing the implant in an ideal position in bone, CT scanning software eliminates possible manual placement errors and matches planning to prosthetic requirements.²⁵The CAD/CAM techniques can be used for single tooth edentulous spaces, single tooth immediate extraction cases, partially edentulous spaces, fully edentulous maxillary and mandibular overdenture cases or fully edentulous maxillary or mandibular full arch permanent restorations.²⁶Dentascan is a computed tomography (CT) software program introduced in mid-1980s that allows imaging in three planes: axial, panoramic and cross-sectional.²⁷It has been widely used pre-operatively for implant surgery as it provides a comprehensive assessment of bone morphology and measurement of dental implant (Fig. 5-A,B).

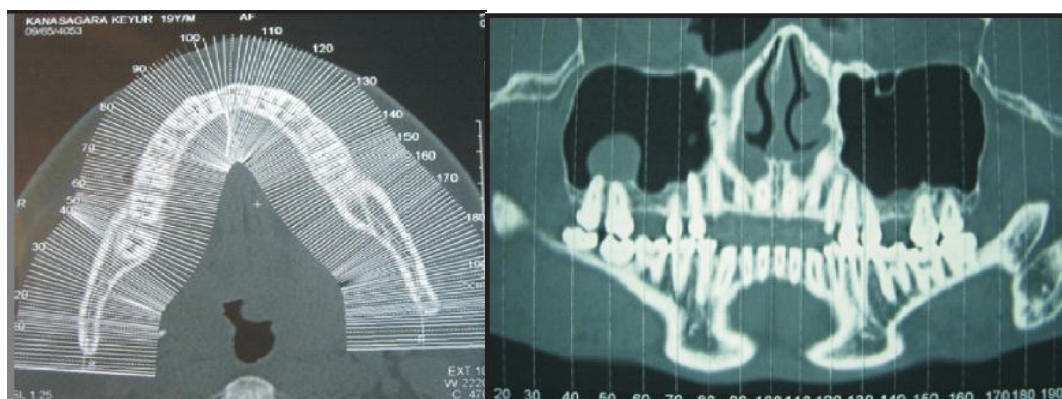


Fig. 5- (A) Panoramic section in dentascan locating position of inferior alveolar canal. (B) Panoramic view in dentascan demonstrating maxillary sinus.

Types of CT scanners

A. Cone Beam Computed Tomography

The Cone Beam CT Scan (CBCT) was introduced in 1998. CBCT provides 3-dimensional images of jawbones, teeth and surrounding vital structures that are important in planning the placement of dental implants. There are five major benefits of cone beam CT scan (CBCT) for dental implant planning and placement:

(i) Precision placement of implants in bone: CBCT along with 3-D software allows to accurately measure and localize the available bone. (Fig. 6).²⁸

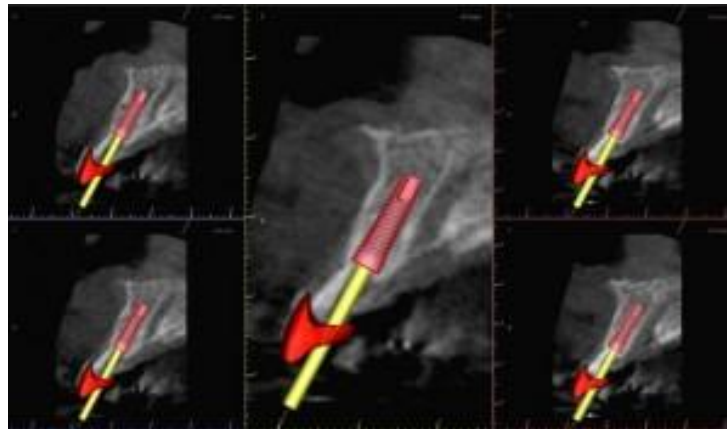


Fig. 6- Precision placement of implants in the bone using CBCT.

(ii) Proper orientation of implant with its overlying restoration: A CBCT is merged with an optical scan of the patient's teeth (digital impression) to create a complete bone, teeth and soft tissue virtual model. Then, dentist design the perfect bite and precise position of the implants to support the planned restorations.

(iii) Prevention of nerve injury: Using CBCT, the surgeon maps out the path of the sensory nerves in jawbone and selects the right implant length.²⁹

(iv) Prevent implant penetration into the sinus: CBCT provides an accurate picture of the maxillary sinus and its position in relation to available bone. The surgeon can make an accurate measurement and select the right implant length to avoid puncturing the maxillary sinus.

(v) Selection of right size implant for optimal support: CBCT allows the surgeon to measure the available bone and select the widest and tallest implant appropriate for the site. This, in turn, helps in implant selection based on precise measurements, biological requirements, bite scheme and individual patient needs.³⁰

B. Cone Beam Volumetric Imaging

Since its introduction in 2001, Cone Beam Volumetric Imaging (CBVI), sometimes called Cone Beam Volumetric Tomography (CBVT), has rapidly been adopted by dentists and dental radiology laboratory owners. Image acquisition using CBVI is much different than when a conventional medical Computed Axial Tomography (CAT) scan is used.³¹ Medical CT images of a proposed implant site show low image resolution and the clinician must use a ruler to "count" the millimeters of height and width (Fig 7). In contrast, the CBVI images show significant improvement in image resolution (Figures 8).

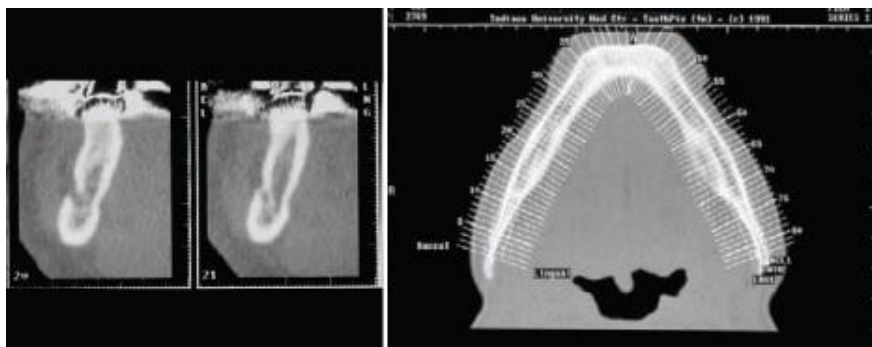


Fig. 7- Medical CT images of a proposed implant site.

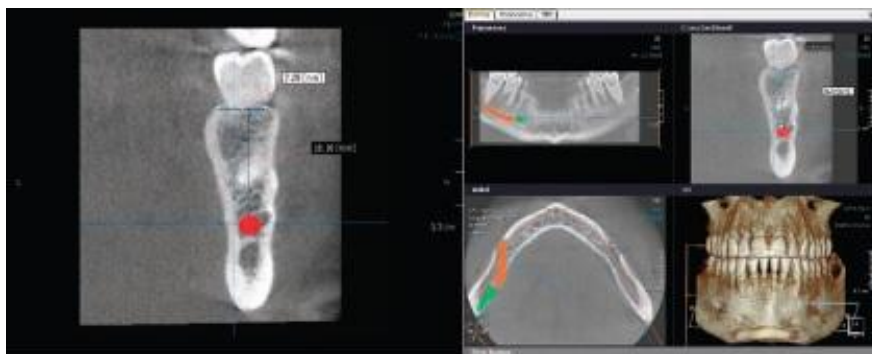

Fig. 8- CBVI images of a proposed implant site.

2.3.3 Magnetic Resonance Imaging

Magnetic resonance imaging (MRI) doesn't use ionising radiation. Instead, the patient is placed in a strong magnetic field and subjected to short pulses of radiowaves. MRI is based on the phenomenon of nuclear magnetic resonance (NMR).³²

For pre-implant assessment, the use of T1- weighted sequences is indicated. In T1-weighted images, the external cortical plate appears black, unlike the normal radio-opacity due to increased bone density seen on radiographs. In contrast, the more organic cancellous bone appears very bright in T1-weighted images.³³

For pre-implant imaging, Gray CF et al. (1996) suggested an initial triplanar pilotscan in sagittal, coronal and axial planes, with a low-resolution gradient echo sequence. The sagittal pilot is used to set up a series of high resolution, fast spin echo axial slices (Fig.9). From these slices, an appropriate slice showing the markers is selected and set up for a series of cross-sectional high resolution images at right angles to the region of interest may be made.²

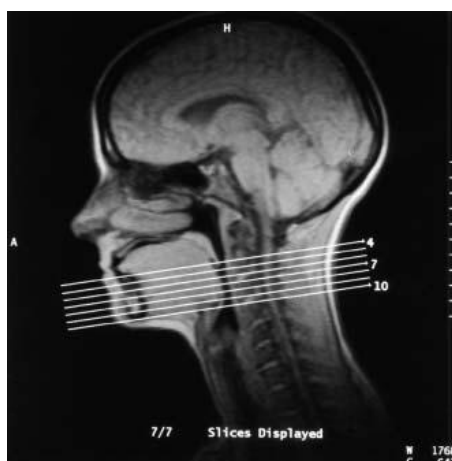

Fig.9- A low resolution gradient echo sagittal pilot scan used to set up the plane for the acquisition of high resolution axial slices.

2.4 HOW 3D SCAN CAN BECOME A HELP TO SURGERY –

Interactive Computed Tomography

One of the most significant advances in CT is Interactive Computed Tomography (ICT), which addresses many of the limitations of CT. This technique was developed to bridge the gap in information transfer between the radiologist and the practitioner. This technique enables the practitioner to view and interact with the imaging data provided from the radiologist in a DICOM format on a personal computer (Fig. 10).³⁴

A software is used for implant planification and navigation. Through these software dentist can perform electronic surgery by selecting and placing arbitrary sized cylinders that simulate root form implants in the images. Electronic implants can be placed at arbitrary positions with respect to each other, the alveolus, critical structures and the prospective occlusion and esthetics. ICT enables the determination of bone quality adjacent to the prospective implant sites (Fig. 11,12).³⁵

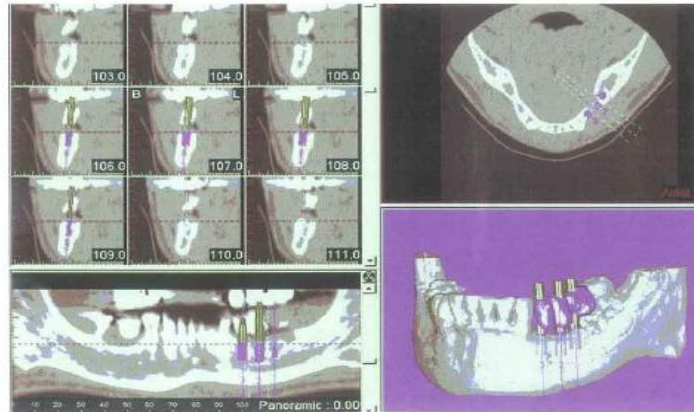


Fig. 10- Reformatted computed tomography scan showing the interactive placement of implants in relation to the diagnostic wax up fabricated radio opaque template.

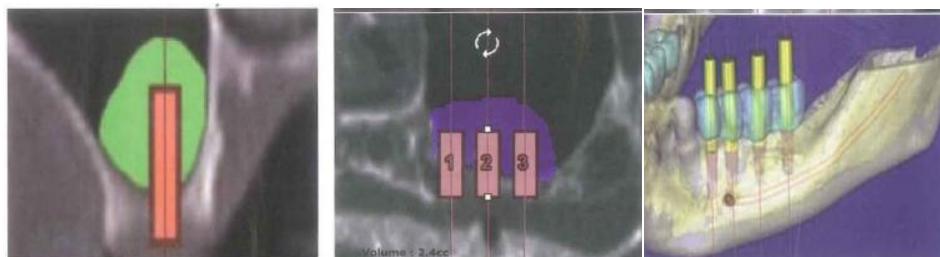


Figure 11 (A, B) - In areas where there is insufficient available bone such as the maxillary sinus, the amount of bone grafting needed may be determined. (C) Implant placement in relation to the mandibular canal and mental foramen; all images are cross referenced with each other. 3D analysis for the evaluation of proximity to vital structures may be generated from the same computed tomography images.

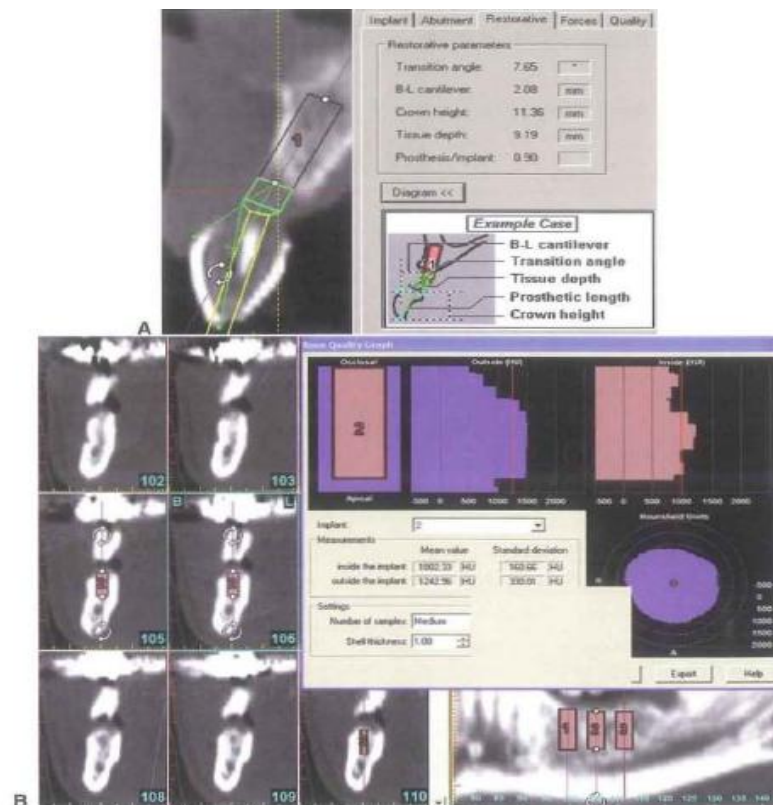


Fig. 12- (A) Valuable prosthetic information may be obtained from the positioning of the implants on the interactive computed tomography. (B) Determination of bone density values is calculated inside and outside of the implant and can be correlated to various densities of bone.

At present, there are numerous third-party implant planning software programs such as Simplant (Materialise Dental Inc, Glen Burnie, MD, USA), Invivo5 (Anatomage, San Jose, CA, USA), NobelClinician (Nobel Biocare, Goteborg, Sweden), OnDemand3D (Cybermed Inc, Seoul, Korea), Virtual Implant Placement software (BioHorizons, Inc, Birmingham, AL, USA), coDiagnostiX (Dental Wings Inc, Montreal, CA, USA), and Blue Sky Plan (BlueSkyBio, LLC, Grayslake, IL, USA) among others.³⁶ There are also a few companies that provide treatment planning in the proprietary software of the CBCT units such as Galileos system (Sirona Dental Systems, Inc, Charlotte, NC, USA), TxSTUDIO software (i-CAT, Imaging Sciences International LLC, Hatfield, PA) and NewTom implant planning software (NewTom, Verona, Italy). After the CBCT data are acquired, the images are exported into DICOM (Digital Imaging and Communications in Medicine) files, a standard for the distribution and viewing of medical images regardless of their origin. This format is compatible with all the third-party software packages listed above; however, an additional file conversion step may be required in some software packages.

All these dental implant computer guided softwares are similar with minor differences and convert DICOM data into a file that provides information for pre surgical planning. Meticulous protocol is needed to computered implant planning which ever software is chosen.

III. Summary & Conclusion

The use of endosteal implants in rehabilitation of dental patients represents one of the most technologically advanced forms of dentistry available today. For the successful implant placement, accurate and valid diagnosis is mandatory using various imaging techniques. The two-dimensional modalities are readily available, cost effective with least radiation exposure, but have limitations of magnifications and superimpositions and it is not possible for the clinician to develop a 3-dimensional perspective of patient's anatomy with a single image.

Treatment planning of implant placement often requires accurate cross sectional information that may be obtained by computerized tomography (CT). Dental imaging have noticeable precision and reliability in pre-implant planification and surgical help. These technologies supply very accurate and repeatable data in user friendly and intuitive environment. It enables instant prosthesis loading. These tools are essential in diagnostic stage as well as surgical act.

Today clinician has wide array of diagnostic tools at his disposal. The clinician has to carefully weight the pros and cons of each modality and choose particular technique accordingly. The excellent imaging modalities that exist today can enhance the success of and satisfaction with implant placement. Selection of projections should be made with consideration to the type and number of implants, location and surrounding anatomy.

References

- [1]. Beagle JR. The immediate placement of endosseous dental implants in fresh extraction sites. *Dent Clin N Am* 2006; 50:375-389.
- [2]. Monsour PA, Dudhia R. Implant radiography and radiology. *Aust Dent J* 2008; 53(1):S11-S25.
- [3]. Ganz SD. Three-dimensional imaging and guided surgery for dental implants. *Dent Clin N Am* 2015; 59:265-290.
- [4]. Gray CF, Redpath TW, Smith FW, Staff RT. Advanced imaging: magnetic resonance imaging in implant dentistry-a review. *Clin Oral Impl Res* 2003; 14:18-27.
- [5]. Delbalso AM, Greiner FG, Licata M. Role of diagnostic imaging in evaluation of dental implant patient. *Radiographics* 1994; 14(4):699-719.
- [6]. DelBalso AM, Hall RE. Advances in maxillofacial Imaging. *Curr Probl Diagn Radiol* 1993; 22(3):92-142.
- [7]. Misch CE. Dental implant prosthetics. 2nd edition. St. Louis: Mosby Elsevier; 2015.
- [8]. Floyd P, Palmer P, Palmer R. Radiographic technique. *Br Dent J* 1999; 187(7):359-365.
- [9]. Whaites E, Drage N. Essentials of dental radiography and radiology. 5th edition. Churchill Livingstone: Elsevier science; 2013.
- [10]. Karjodkar FR. Textbook of dental and maxillofacial radiology. 2nd edition. Jaypee Brothers Medical Publishers (Pvt) Ltd; 2011.
- [11]. White SC, Pharoah MJ. Oral radiology Principles and Interpretation. 5th Edition. St. Louis: Mosby Elsevier; 2004.
- [12]. Bhat S, Shetty S, Shenoy KK. Imaging in implantology. *J Indian Prosthodont Soc* 2005; 5(1):10-14.
- [13]. Misch CE. Contemporary implant dentistry. 3rd edition. St. Louis: Mosby Elsevier; 2007.
- [14]. Lingam AS, Reddy L, Nimma V, Pradeep K. Dental implant radiology – Emerging Concepts in planning implants. *J Orofac Sci* 2013; 5(2):88-94.
- [15]. Maloney PL, Lincoln RE, Coyne CP. A protocol for the management of compound mandibular fractures based on the time from injury to treatment. *J Oral Maxillofac Surg* 2001; 59(8): 879-884.
- [16]. Rondon RHN, Pereira YCL, Nascimento GC. Common positioning errors in panoramic radiography: A review. *Imaging Sci Dent* 2014; 44:1-6.
- [17]. Bagchi P, Joshi N. Role of Radiographic Evaluation in Treatment Planning For Dental Implants: A Review. *J Dent Allied Sci* 2012; 1(1):21-25.
- [18]. Lingeshwar D, Dhanasekar B, Aparna IN. Diagnostic Imaging in Implant Dentistry. *Int J Oral Implant Clin Research* 2010; 1(3):147-153.
- [19]. Parelli J, Abramowicz S. Immediate Placement and Immediate Loading Surgical Technique and Clinical Pearls. *Dent Clin N Am* 2015; 59(2):345-355.
- [20]. Dula K, Mini R, Buser D. The Radiographic Assessment of Implant Patients: Decision-making Criteria. *Int J Oral Maxillofac Implants* 2001; 16(1):80-89.

- [21]. Williams MYA, Mealey BL, Hallmon WW. The Role of Computerized Tomography in Dental Implantology. *Int J Oral Maxillofac Implants* 1992; 7(3):373–380.
- [22]. Worthington P, Rubenstein J, Hatcher DC. The role of cone-beam computed tomography in the planning and placement of implants. *J Am Dent Assoc* 2010; 141:19-24.
- [23]. Webber RL, Horton RA, Underhill TE, Ludlow JB, Tyndall DA, Salem W, Hill C. Comparison of film, direct digital, and tuned aperture CT images to identify the location of crestal defects around endosseous titanium implants. *Oral Surg Oral Med Oral Pathol Oral Radiol Endod* 1996; 81(4):480-490.
- [24]. Almog DM, Illig KA, Elad S, Romano PR, Carter LC. Supplementary role of panoramic radiographs in the medical surveillance of a patient at risk for stroke. *Compend Contin Educ Dent* 2005; 26(6):369-372.
- [25]. Surapaneni H, Yalamanchili PS, YalavarthyRS, Reshmarani AP. Role of computed tomography imaging in dental Implantology: An overview. *J Oral Maxillofac Radiol* 2013; 1(2):43-47.
- [26]. Kosinski T, Skowronski R. Utilizing CT Scanning Technology in the Placement of Dental Implants. *Oral Surg Oral Med Oral Pathol* 2008; 76:870-878.
- [27]. Abrahams JJ. Dental CT Imaging: A Look at the Jaw. *Radiology* 2001; 219:334-345.
- [28]. Mills EJ. CBCT and implants: Improving patient care, one implant at a time, Part I. (Internet) 2011 April. Available from : <http://www.dentaleconomics.com/articles/print/volume-101/issue-4/features/cbct-and-implants-improving-patient-care-one-implant-at-a-time-part-1.html>
- [29]. Tepper G, Hofschneider UB, Gahleitner A, Ulm C. Computed Tomographic Diagnosis and Localization of Bone Canals in the Mandibular Interforaminal Region for Prevention of Bleeding Complications During Implant Surgery. *Int J Oral Maxillofac Implants* 2001; 16:68-72.
- [30]. Kazemi HR. Five Benefits of Cone Beam CT Scan (CBCT) for Dental Implant Planning and Placement. (Internet). 2016. Available from : <https://www.facialart.com/2016/01/five-benefits-of-cone-beam-ct-scan-cbct-for-dental-implant-planning-and-placement/>
- [31]. Balshi SF, Wolfinger GJ, Balshi TJ. Surgical Planning and Prosthesis Construction Using Computed Tomography, CAD/CAM Technology, and the Internet for Immediate Loading of Dental Implants. *J Esthet Restor Dent* 2006; 18:312-325.
- [32]. Baker KB, Tkach JA, Nyenhuis JA et al. Evaluation of Specific Absorption Rate as a Dosimeter of MRI-Related Implant Heating. *J Magn Reson Imaging* 2004; 20:315-320.
- [33]. Abbaszadeh K, Heffez LB, Mafee MF. Effect of Interference of metallic objects on interpretation of T1-Weighted magnetic resonance images in the maxillofacial Region. *Oral Surg Oral Med Oral Pathol Oral Radiol Endod* 2000; 89:759–765.
- [34]. Norton MR, Gamble C. Bone classification: An objective scale of bone density using the computerized tomography scan. *Clin Oral Implants Res* 2001; 12(1):79-84.
- [35]. Tischler M. Interactive computerized tomography for dental implants. Treatment planning from the prosthetic end result. *Dent Today*. 2004; 23(3):92-93.
- [36]. Mora MA, Chenin DL, Arce RM. Software tools and surgical guides in dental implant guided surgery. *Dent Clin N Am* 2014; 58:597-62.

Dr. Sourabh Sharma "Imaging in Dental Implantology: A Review." *IOSR Journal of Dental and Medical Sciences (IOSR-JDMS)*, vol. 17, no. 7, 2018, pp 13-23.