

## Interpositional Bone Grafting With Autogenous Iliac Crest Bone For Bilateral Mandibular Angle Augmentation

Dr. Nithin kumar, MDS<sup>1</sup>, Dr. Manoj Kumar KP, MDS<sup>2</sup>,  
Dr. Suresh Vyloppilli, MDS<sup>3</sup>, Dr. Depesh Vijaykumar<sup>4</sup>

<sup>1</sup>Dept of Oral surgery, Dental faculty, Ishik University, Erbil, KRG, Iraq

<sup>3</sup>Malankara Orthodox Syrian Church Medical College & Hospital, Kolenchery, Ernakulam, Kerala

<sup>4</sup>Dept of OMFS, KMCT Dental College and hospital, Manassery, Kozhikode, Kerala

Corresponding Author: Dr. Nithin Kumar

**Abstract:** The bird-face deformity with high Frankfort–mandibular plane angle with significant retrogenia, often associated with diminutive condyles and reduced posterior face height, poses many challenges to the orthognathic surgeon. Several surgical procedures including bilateral sagittal split osteotomy(BSSO), vertical ramus osteotomy(VRO) and inverted L-osteotomy have been used to correct it. But when the patient is having a normal occlusion, these procedures alter this occlusion making a post surgical orthodontic treatment mandatory. This lengthens the total duration of treatment that the patient has to go through as well as unnecessary alteration in occlusion that may lead to other problems such as TMJ dysfunction. We propose a osteotomy technique and interpositional bone grafting for the augmentation of mandibular angle without any alteration of dental occlusion. Surgical procedure: This technique is simple and straight forward. The osteotomy can be performed either extraorally or transorally. Cutting of the pterygomasseteric sling is systematically done following osteotomy allowing for the lowering of the mandibular angle followed by interpositional bone graft placement and fixation. Disadvantage of this technique is scar formation if extra oral approach is used.

**Keywords:** retrogenia, ramus lengthening, interpositional bone graft, mandibular angle, augmentation.

Date of Submission: 17-09-2019

Date of Acceptance: 02-10-2019

### I. Introduction

Surgical management of hyperdivergent mandible with posterior vertical deficiency and normal occlusion raises many challenges for orthognathic surgeons [1,2]. Mandibular hypoplasia's often require augmentation procedures which include advancement orthognathic surgeries, distraction osteogenesis or by using different types of grafts.[3] Traditionally bilateral sagittal split osteotomies (BSSO),vertical ramus osteotomy (VRO) and inverted "L" osteotomy have been used for lengthening of the ascending ramus but these procedures also alters the occlusion. [1] These procedures are complex and cannot be used for ramus lengthening in a patient having normal occlusion. One must not overlook the risks to the inferior dental nerve as well with these procedures. The advent of distraction osteogenesis promised to be the answer for these cases, but with nearly 20 years of experience with these techniques, it is clear that it does not represent the panacea that was hoped for. Additionally, it requires surgery twice, to insert and then remove the distractor. Complications such as pressure sores and infection have also been reported in the literature.[4,5,6] We propose a new osteotomy and bone grafting technique that allows for lengthening of the vertical ramus without altering the occlusion.

### II. Case presentation

A 20 years old patient reported to our institution with the complaint of deficient chin and smaller lower jaw. Patient had noticed her complaint during her adolocence period which had remained the same since then. There was no history of trauma to the jaws as well as no other complaint related to mouth opening. Her family history was also negative for any obvious mandibular discrepencies. On clinical examination, she had a convex facial profile with retruded chin and deficient or absent mentolabialsulcus(Figure 1). She had a hyperdivergent mandibular plane angle with deficient or absent gonial angle prominence. She also had a decreased posterior vertical facial height with short ramus. On intraoral examination, she had a normal occlusion with class I molar relation and normal inter incisal relation. Orthopentomogram and lateral cephalomeric radiographs confirmed the clinical diagnosis. Mandibular vertical ramus lengthening and augmentation genioplasty was planned for this patient.

### **III. Surgical Procedure**

Access to the mandibular angle is performed via modified Risdon's incision about 2cm below the lower border of the mandibular (Figure 2). Incision and blunt dissection done through skin, subcutaneous layer, platysma muscle, superficial layer of deep cervical fascia and periosteum taking care not to damage the marginal mandibular branch of facial nerve. If facial vessels are encountered they are ligated. Subperiosteal dissection is continued to uncover the mandibular angle on only the lateral surface of the ramus.<sup>[7]</sup> The exact location of mandibular canal is ascertained by the orthopantomogram and the dentascans studies. These exact measurements are marked on the mandibular angle so as to make the osteotomy cuts just below the mandibular canal. Using micromotor and straight bur no. 702 or an oscillating saw osteotomy cuts are completed through both the buccal and the lingual cortex. Using the spreader the osteotomized segments are separated and the brisk bleeding from the medial pterygoid muscle is controlled. During this mandibular osteotomy, simultaneously another surgical team will be harvesting the required block of donor bone from the iliac crest graft. The osteotomized segment of the mandibular angle are separated in the posterior border of the ramus, all the while keeping the segments in contact along the lower border of the mandible (Figure 3). A measured wedge of donor bone is interpositioned in the gap between the osteotomized segments. Miniplate fixation is done along the posterior and lower border of the mandible (Figure 4). This procedure was repeated on the other side as well. This is followed by the layer wise closure of the submandibular incision. Augmentation genioplasty was also performed to increase the chin prominence. Post op follow up reveals good prominence of the mandibular angle and chin region (Figure 5). Post op OPG (Orthopantomogram) and lateral cephalogram on 4 weeks follow up showed good stability of fixation (Figure 6 & Figure 7).

### **IV. Discussion**

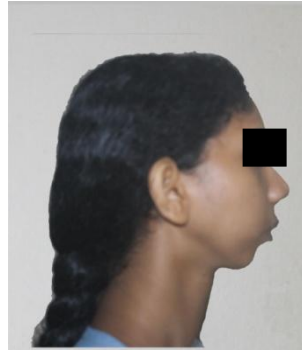We present a simple surgical alternative to conventional orthognathic techniques for surgical management of posterior vertical insufficiency and short mandibular body. Conventional orthognathic surgeries are associated with various intra operative and post operative complications. Intraoperative complications including inadequate osteotomy or bad split, bleeding due to vascular injuries, nerve exposure and damage, dental injuries, and soft tissue injuries among the patients, as well as postoperative complications including paresthesia due to nerve injuries, dyspnea, cervical pain, gastrointestinal diseases, infections, open bite, relapse, TMD, and malunion or nonunion of bone fractures.<sup>[4, 8]</sup> Our technique avoids most of these complications as well as allows for increase in length of the mandibular ramus without alteration of the dental occlusion. This avoids the need for post surgical orthodontic treatment when the occlusion is normal. Occlusal splint fabrication is also not required during this procedure thereby reducing the duration of presurgical planning.

The disadvantages of this technique is scar formation if the extraoral approach was used. This can be avoided by using an endoscopic approach with oscillating saw for osteotomy and transbuccal approach for fixation of the osteotomized segments. This technique cannot be used as single procedure when there is skeletal discrepancy associated with dental malocclusion. Also the requirement for bone grafting created an additional donor site morbidity. Different types of alloplastic materials can be used as an alternative for augmentation of mandibular angle and chin. But these techniques are having an higher rate of infection and are not cost effective.<sup>[9]</sup>

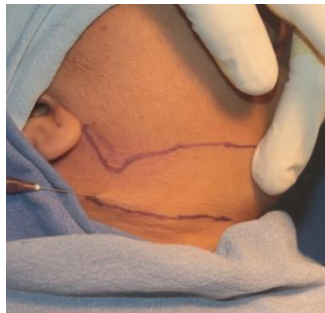### **V. Conclusion**

This surgical procedure is recommended for mandibular angle augmentation when the patient is having a normal occlusal relation without any other maxillofacial skeletal deficiencies. This procedure can be combined with chin augmentation if required.

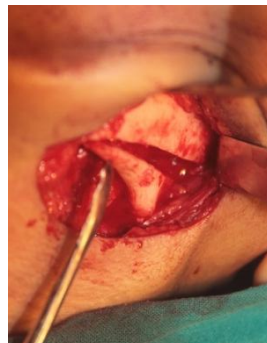Conflict of interest:  
None identified.



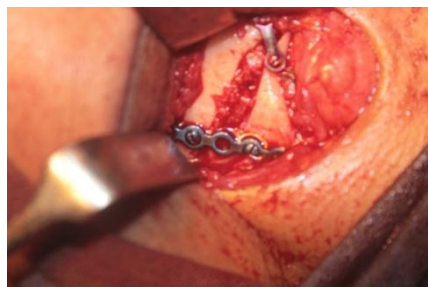**Figure 1:** Pre operative lateral profile view



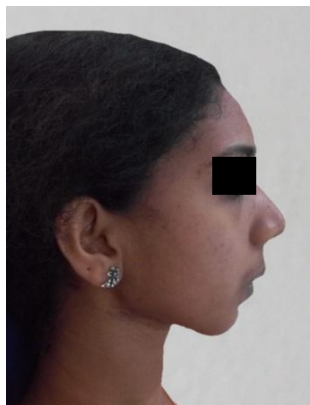**Figure 2:** Incision marking for Risdon's approach



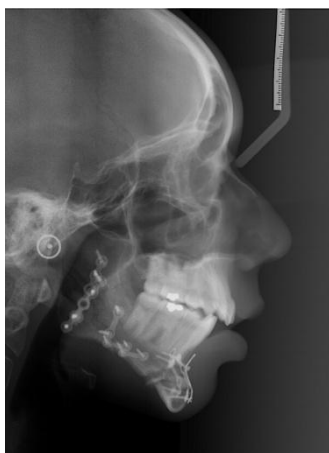
**Figure 3:** Mandibular angle osteotomy



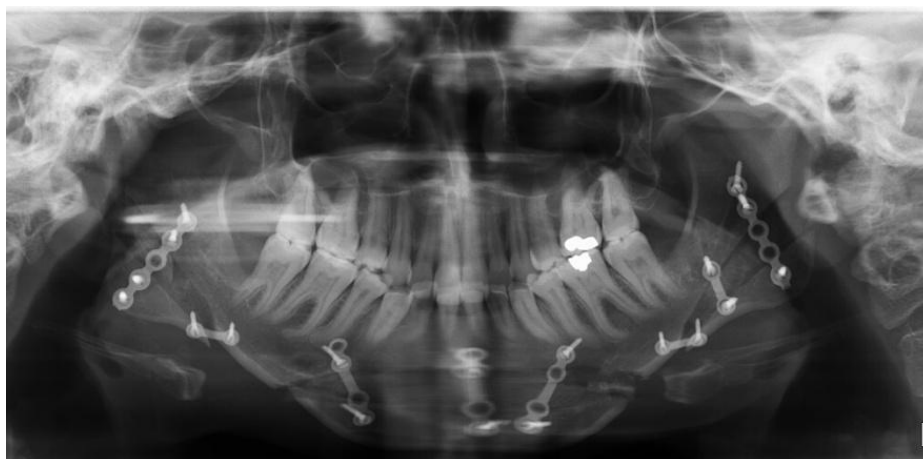**Figure 4:** Interpositional bone graft placement and miniplate fixation



**Figure 5:** Post operative lateral profile view



**Figure 6:** Post operative lateral cephalogram



**Figure 7:** Post operative OPG

### References

- [1]. Mercier J, Gordeeff A, Delaire J. Changes in the posterior vertical dimension of the face. Etiopathogenic factors, architectural criteria and therapeutic aspects. *Orthod Fr* 1989;60(Pt 2):575–82.
- [2]. Salagnac JM, Delaire J, Mercier J. Vertical development of the face and cervical spine. Diagnostic and therapeutic significance in orthodontics and maxillofacial surgery. *Rev StomatolChirMaxillofac* 1999;100(1):13–26.
- [3]. Proffit WR, White RP, Sarver DM. Contemporary treatment of dentofacial deformity: Mosby St Louis, Mo; 2003.
- [4]. L. Greaney, G. Bhamrah, K. Sneddon, J. Collyer. Reinventing the wheel: a modern perspective on the bilateral inverted ‘L’ osteotomy. *Int. J. Oral Maxillofac. Surg.* 2015; 44: 1325–1329
- [5]. Westermark A, Bystedt H, von Konow L. Inferior alveolar nerve function after sagittal split osteotomy of the mandible: correlation with degree of intraoperative nerve encounter and other variables in 496 operations. *Br J Oral Maxillofac Surg* 1998;36:429–33.
- [6]. Van Strijen PJ, Perdijk FB, Becking AG, Breuning KH. Distraction osteogenesis for mandibular advancement. *Int J Oral Maxillofac Surg* 2000;29:81–5.
- [7]. Živorad S. Nikolić , Drago B. Jelovac , MelvilŠabani, Jelena V. Jeremić. Modified Risdon approach using periangular incision in

- surgical treatment of subcondylar mandibular fractures. *SrpArhCelokLek*. 2016 Jul-Aug;144(7-8):391-396
- [8]. Young-Kyun Kim. Complications associated with orthognathic surgery. *J Korean Assoc Oral Maxillofac Surg*. 2017 Feb; 43(1): 3–15.
- [9]. Vylloppilli S, Joseph B, Kumar N, Anirudhan A. Correction of nonsyndromic facial asymmetry with pHDPE facial implant and sliding genioplasty. *International Journal of Dental Clinics*. 2014;6(2):27-28.

Dr. Nithin Kumar. “Interpositional Bone Grafting With Autogenous Iliac Crest Bone For Bilateral Mandibular Angle Augmentation.” *IOSR Journal of Dental and Medical Sciences (IOSR-JDMS)*, vol. 18, no. 10, 2019, pp 21-25.