

## Conservative Management of Recurrent Pseudo Meningocele after Previous Surgical Re-Exploration.

Dr. Michelle Siew<sup>1</sup>, Dr. Vinod K.S. Gautam<sup>2</sup>, Dr. Manish Kumar Goel<sup>2</sup>,  
Dr. Balaji Balasubramaniam<sup>3</sup>, Dr Bharti Sharma<sup>4</sup>.

<sup>1</sup>(MBBS Graduate, Lady Hardinge Medical College, India)

<sup>2</sup>(Assistant Professor, Department of Neurosurgery, IHBAS, India)

<sup>2</sup>(Professor, Department of Preventive and Social medicine, LHMC, India)

<sup>3</sup>(Senior Resident, Department of Neuroanaesthesiology, IHBAS, India)

<sup>4</sup>(Junior Resident, Department of Neurosurgery, IHBAS, India)

**Abstract:** Pseudo meningocele are common complications after posterior fossa cranial surgery. Management guidelines are lacking, and radically different suggested treatments varying from observation to immediate surgical intervention are encountered in literature. Its management can be challenging and treatment options vary in literature, and there is no consensus on the optimal management strategy.<sup>3, 4, 5</sup> and even rarer articles and study are available about management of recurrent pseudo meningocele. This case report emphasizes the significance of conservative management of pseudo meningocele even after previous re-exploration there by abating unnecessary procedures. The conservative management includes pressure dressing, bed rest and CSF lumbar drainage.

**Keywords:** Pseudo meningocele, CSF lumbar drainage, Re- exploration

Date of Submission: 17-09-2019

Date of Acceptance: 02-10-2019

### I. Background

Pseudo meningoceles are extradural collections of cerebrospinal fluid (CSF) with no dural covering resulting from a dura-arachnoid defect or improper closure during crania or spinal surgery.<sup>1</sup> There are three groups of pseudo meningocele: congenital, traumatic, and iatrogenic.

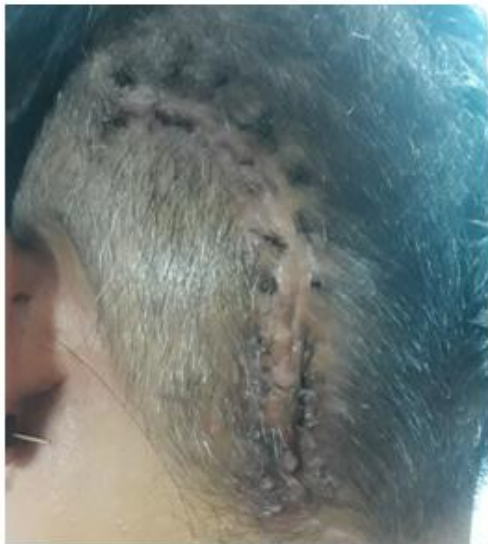Pseudo meningocele is a common complication after posterior fossa cranial surgery.<sup>6-9</sup> It may cause complications such as cosmetic deformities, positional headache, chronic meningitis, and/or impingement on vital structures resulting in neurological deficits.<sup>10,11</sup> The incidence of clinically relevant pseudo meningocele formation after posterior fossa cranial surgery ranges from 4 – 23% in literature.<sup>11-17</sup>

Management guidelines are lacking, and different suggested treatments varying from observation to immediate surgical intervention are encountered in literature.<sup>3, 4, 5</sup> The usual treatment algorithm consists of initially starting with nonoperative measures including pressure dressing, bed rest, and lumbar spinal drainage.<sup>10,18,19</sup> In case these conservative measures fail surgical intervention may be required.<sup>3,19,20</sup> Postoperative ventriculomegaly, however, portends failure of temporary cerebrospinal fluid diversion, and early consideration of shunting might be appropriate in such cases.<sup>3,4</sup> The purpose of our case report is to emphasize the significance of conservative management of pseudo meningocele there by abating unnecessary procedures. The conservative management includes pressure dressing, bed rest, cerebral decongestants and CSF lumbar drainage.

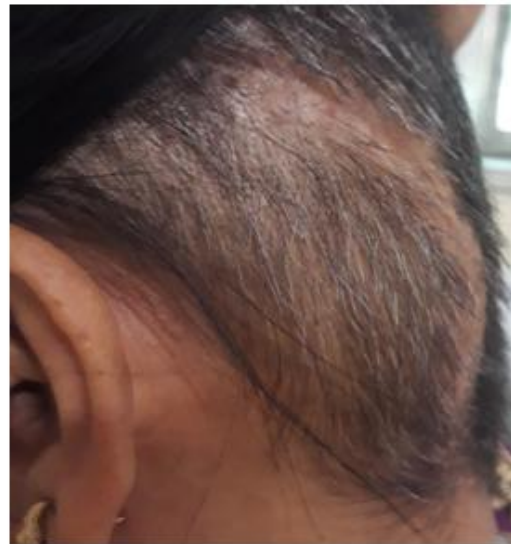### II. Case Presentation

45 year old female presented with swelling in the left occipital region. The patient underwent left paramedian suboccipital craniotomy and subtotal excision of posterior fossa under General Anaesthesia on 20.06.2019 for posterior fossa SOL(Meningioma) left cerebellar. Her intraoperative and Post operative periods were uneventful. During her course in the hospital, She developed pseudomeningocele and underwent re-exploration and repair under General Anaesthesia on 12.08.2019. Her intraoperative and post operative events were uneventful. The patient developed swelling in the left occipital region 1 week after the repair. She complaint of heaviness in the left occipital region. She denied any fever, weakness, numbness, parasthesia, ataxia, cognitive decline, focal, cranial nerve deficit, meningeal signs. Her vitals were stable. The CT scan of the patient showed pseudomeningocele with left occipital craniotomy status noted with overlying graft, Gliotic scarring was seen, no ventricle enlargement as shown in figure 1a and 1b. The patient was admitted in the neurosurgery ward and observed for symptoms and signs of increased intracranial tension and meningitis. An elective decision of conservative management was taken and the patient was managed with acetazolamide, bed

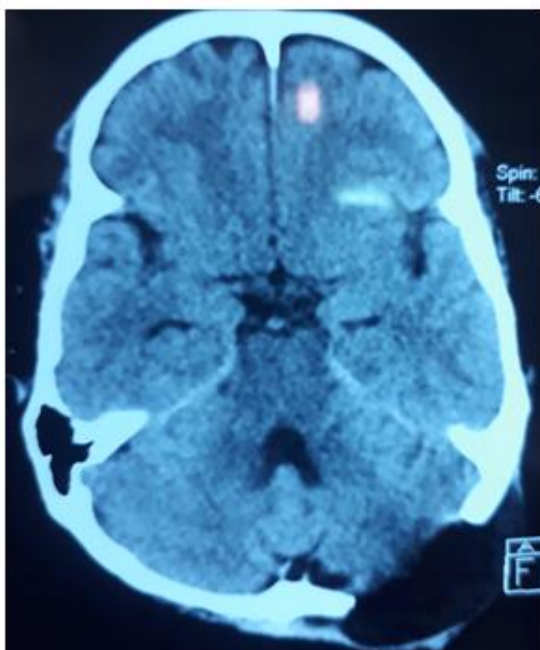
rest, pressure dressing. Within a course of 10-14 days the swelling subsided. The repeat CT showed reduction in size of pseudomeningocele as shown below in figure 2a and 2b.



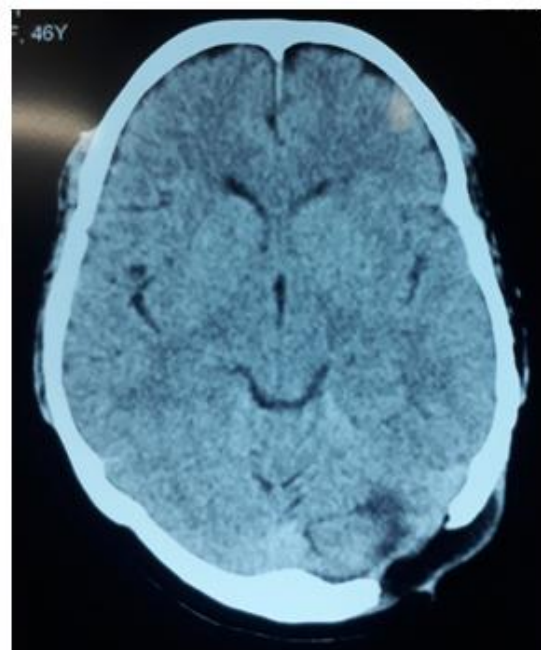
**Figure 1.a.**



**Figure 2.a.**



**Figure 2.a.**



**Figure 2.b.**

### **III. Conclusion**

Pseudomeningocele is a common complication after posterior fossa surgery.<sup>6-9</sup> Pseudomeningoceles may cause complications such as cosmetic deformities, debilitating symptoms such as positional headache, chronic meningitis, impingement on vital structures with neurological deficits,<sup>10,11</sup> and rarely reported complications such as spontaneous intracerebellar migration of a pseudomeningocele<sup>21</sup> and posterior fossa cyst formation with brain stem compression.<sup>10</sup>

Its management can be challenging and treatment options vary in literature, and there is no consensus on the optimal management strategy.<sup>3,4,5</sup> As management guidelines are lacking so an international survey was carried out and opinions from neurosurgeons throughout the world were sought on the topic of management of pseudomeningocele after posterior fossa surgery. It was found that pseudomeningoceles after posterior fossa tumor resection, in the absence of hydrocephalus, were typically managed nonoperatively for 7 to 14 days before re-exploration. Only 0.5% of the surgeons would offer upfront repair of the pseudomeningocele. In the presence of hydrocephalus, 48% of the neurosurgeons intervene initially with cerebrospinal fluid (CSF)

diversion and would change therapy if the lesion did not resolve in 2 to 4 days. It was concluded in this international survey that initial observation is appropriate for cranial pseudomeningoceles. Operative revision should be reserved for failure of conservative treatment.<sup>3</sup> This also is the usual treatment regimen followed and nonoperative measures like pressure dressing, bed rest and CSF lumbar drainage lead to the settlement of pseudomeningoceles in the majority of cases.<sup>18, 19</sup> In case of post operative ventriculomegaly CSF shunting may be required as ventriculomegaly portends failure of CSF lumbar drainage.<sup>3, 4</sup>

There are very few articles and study available about management of recurrent pseudomeningocele. In a study by Sarah E.Birkholz MBA, showed that treatment of cerebrospinal fluid (CSF) leak with pseudomeningocele formation can be challenging; especially when attempts to repair it fail. In this paper the authors report four cases with pseudo meningocele that had failed prior attempt at repairing the leak, in whom drainage of extradural space with indwelling catheter resulted in resolution of the pathology.

This case report emphasizes that despite the failure of previous repair of the dura the recurrence of pseudo meningocele can be managed by conservative management, thereby abating the need of invasive procedures. We encourage doctors to report more cases of conservative management of recurrent pseudo meningocele and that will lead to formation of better pseudo meningocele management guidelines.

## COMPETING INTEREST

None Declared.

## References

- [1]. M. Macki, S.-F. L. Lo, M. Bydon, P. Kaloostian, and A. Bydon, "Post-surgical thoracic pseudomeningocele causing spinal cord compression," *Journal of Clinical Neuroscience*, vol. 21, no. 3, pp. 367–372, 2014.
- [2]. Sarah E.BirkholzMBA<sup>a</sup>Arun A.PatilMD<sup>b</sup>Andrea J.ChamczukMD<sup>b</sup>, Volume 16, June 2019, Pages 25-28, <https://doi.org/10.1016/j.inat.2018.11.006>.
- [3]. Tu A, Tamburrini G, Steinbok P: Management of postoperative pseudomeningoceles: an international survey study. *Childs Nerv Syst*. 2014 Nov; 30 (11): 1791-801.
- [4]. 2. Smith GA, Strohl MP, Manjila S, Miller JP: Incidence, management, and outcome of symptomatic postoperative posterior fossa pseudomeningocele: A retrospective single-institution experience. *Operative Neurosurgery*, 2016 Jan. 1; 12 (3): 298-303.
- [5]. De Tommasi C, Bond AE: Complicated Pseudomeningocele Repair after Chiari Decompression: Case Report and Review of the Literature. *World Neurosurg*. 2016 Apr; 88: 688.e1-7.
- [6]. Tu A, Tamburrini G, Steinbok P: Management of postoperative pseudomeningoceles: an international survey study. *Childs Nerv Syst*. 2014 Nov; 30 (11): 1791-801
- [7]. Smith GA, Strohl MP, Manjila S, Miller JP: Incidence, management, and outcome of symptomatic postoperative posterior fossa pseudomeningocele: A retrospective single-institution experience. *Operative Neurosurgery*, 2016 Jan. 1; 12 (3): 298-303.
- [8]. Giacomo Esposito, Vito Andrea dell'Anna, Antonio Marrazzo, Andrea Carai, Raffaella Messina, Alessandro De Benedictis et al: NS-25. Impact of Medulloblastoma Molecular Subgroup on PostOperative Pseudomeningocele and Need for Ventricular Shunting. *Neuro-Oncology*, 2016; 18: 127-134. 4
- [9]. Parker SL, Godil SS, Zuckerman SL, Mendenhall SK, Tulipan NB, McGirt MJ: Effect of symptomatic pseudomeningocele on improvement in pain, disability, and quality of life following suboccipital decompression for adult Chiari malformation type I. *J Neurosurg*. 2013 Nov; 119 (5): 1159-65.
- [10]. Jung-Ying Chiang, Hung-Lin Lin: Life-threatening posterior fossa cyst induced by pseudomeningocele after operation for acoustic neuroma. *Surg Neurol Int*. 2015; 6 (Suppl. 2): 101–103.
- [11]. Varun R. Kshetry, Bjorn Lobo, Joshua Lim, Burak Sade, Soichi Oya, Joung H. Lee: Evaluation of NonWatertight Dural Reconstruction with Collagen Matrix Management of Postoperative Pseudomeningocele following Posterior Cranial Fossa Surgery Pak. J. of Neurol. Surg. – Vol. 21, No. 1, Jan. – Mar., 2017 -12- Onlay Graft in Posterior Fossa Surgery. *J Korean Neurosurg. Soc*. 2016 Jan; 59 (1): 52–57
- [12]. Legnani FG, Saladino A, Casali C, Vetrano IG, Varisco M, Mattei L et al: Craniotomy vs. craniectomy for posterior fossa tumors: A prospective study to evaluate complications after surgery. *Acta Neurochirurgica*. 2013; 155 (12): 2281-2286.
- [13]. Ali Abou-Madawi: VP-Shunt Requirement in Patients with Posterior Fossa Tumors. *Suez Canal Univ Med J*. 2007; 10: 121-128.
- [14]. Parížek J, Mericka P, Nemecek S, Nemecková J, Spacek J, Suba P et al: Posterior cranial fossa surgery in 454 children. Comparison of results obtained in pre-CT and CT era and after various types of management of dura mater. *Childs Nerv Syst*. 1998; 14 (9): 426-38.
- [15]. Santamarta D, Blázquez JA, Maíllo A, Muñoz A, Caballero M, Morales F: Analysis of cerebrospinal fluid related complications (hydrocephalus, fistula, pseudomeningocele and infection) following surgery for posterior fossa tumors. *Neurocirugia (Astur)*. 2003 Apr; 14 (2): 117-26.
- [16]. Danish SF, Samdani A, Hanna A, Storm P, Sutton L: Experience with acellular human dura and bovine collagen matrix for duraplasty after posterior fossa decompression for Chiari malformations. *J Neurosurg*. 2006 Jan; 104 (1 Suppl.): 16-20.
- [17]. Hadanny A, Rozovski U, Nossek E, Shapira Y, Strauss I, Kanner AA et al: Craniectomy Versus Craniotomy for Posterior Fossa Metastases: Complication Profile. *World Neurosurg*. 2016 May; 89: 193-8.
- [18]. Mehendale NH, Samy RN, Roland PS: Management of pseudomeningocele following neurotologic procedures. *Otolaryngol Head Neck Surg*. 2004 Sep; 131 (3): 253- 62.
- [19]. Menger R, Connor DE Jr, Hefner M, Caldito G, Nanda A: Pseudomeningocele formation following chiari decompression: 19-year retrospective review of predisposing and prognostic factors. *Surg Neurol Int*. 2015 May 7; 6: 70.
- [20]. Jito J, Nitta N, Nozaki K: Delayed cerebrospinal fluid leak after watertight dural closure with a polyethylene glycol hydrogel dural sealant in posterior fossa surgery: Case report. *Neurol Med Chir (Tokyo)*, 2014; 54 (8): 634-9. Doi: 10.2176/nmc.cr.2013-0010
- [21]. de Jong L, Engelborghs K, Vandevenne J, Weyns F: Migrating pseudomeningocele causing posterior fossa syndrome. *Br J Neurosurg*. 2012 Aug; 26 (4): 537-9.