

## Castleman's Disease: A Rare Case Report

<sup>1</sup>Dr.Ramesh Kumar Korumilli,<sup>2</sup>Dr.Amulya Kanmathareddy,<sup>3</sup>Dr.Muvva Sri Harsha,<sup>4</sup>Dr.Sameer Kumar Reddy

<sup>1</sup>(Professor and HOD, General surgery, SVS Medical college, KNR university of Health sciences, INDIA)

<sup>2,3,4</sup>(Post-Graduates of General Surgery, SVS Medical college, KNR University of Health sciences, INDIA)

---

**Abstract-**Castleman Disease (CD) is a rare, heterogeneous group of hyperimmune lymphoproliferative disorders, not very familiar to surgeons. It is characterized by non-neoplastic lymph node hypertrophy. Its incidence and etiology are not known, but has been found in association with Kaposi's Sarcoma. Unicentric Castleman Disease (UCCD) at one end of the spectrum is a localized disease, with little or no systemic symptoms. It may be an incidental radiological finding or detected while investigating for a symptomatic lymph node mass. Multicentric Castleman Disease (MCCD) is a more serious systemic condition, often associated with constitutional symptoms. Human Herpes Simplex Virus 8 (HHV8) associated MCCD is a major subgroup occurring in immunocompromised individuals due to the viral trigger.

We report a case of a 21 year old male presenting with a history of swelling in the right side of the neck at level 2 since 7 months and another lymph node since 2 months at level 3 station for which he was on Anti-tubercular therapy based on initial FNAC report. There was no decrease in the size of the swellings and a repeat FNAC showed a suspicion of Hodgkin's disease from level 2 station lymph node. Subsequently, excision and biopsy was done and Histopathological examination revealed Castleman's Disease. Usg abdomen and Chest x ray were normal. Surgery is the primary treatment and has good long term prognosis. Awareness among surgeons and diligent work-up is a must for early diagnosis and best outcome.

**Keywords:** Castleman's Disease, Cervical Lymphadenopathy, Good Prognosis

---

Date of Submission: 04-10-2019

Date of Acceptance: 21-10-2019

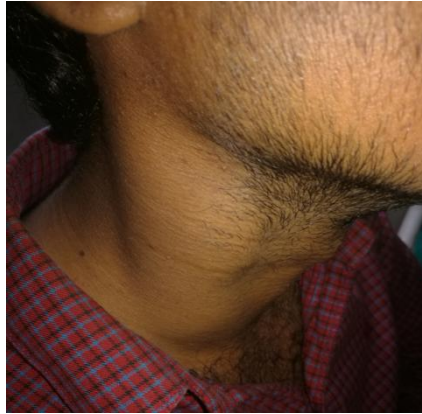---

### I. Introduction

Castleman Disease (CD) is a rare, heterogeneous group of hyperimmune lymphoproliferative disorders described by Benjamin Castleman in 1956 [1]. It is also known as giant lymph node hyperplasia or angiofollicular lymph node hyperplasia. Castleman's disease is clinically classified into 2 distinct presentations, unicentric (localized) and multicentric (systemic) [2]. The unicentric form disease is usually asymptomatic whereas the multicentric form is associated with generalized symptoms and commonly seen in association with syndromes like AIDS, POEMS, Kaposi's sarcoma, lymphomas, paraneoplastic pemphigus and plasma cell dyscrasias [3]. There is no sex predilection and mostly occurs in adult age group. Surgery is the primary treatment and has good long term prognosis [4].

### II. Case Report

A 21 year old male complains of swelling since 7 months and another swelling since 2 months in the right side of the neck. Initial FNAC done revealed features suggestive of chronic tuberculous disease for which he is on ATT since 6 months. There was no response with ATT and a repeat FNAC revealed features suggestive of a lymphoproliferative disorder (? Hodgkin's disease). On clinical examination, it was a swelling of 3x3 cms in the right side of the neck at level 2 station which was non-tender, firm, showing restricted mobility and was medial to sternocleidomastoid. Other swelling was of size 2x1 cms at level 3 station which was non-tender, firm, showing restricted mobility. All lab investigations were within normal limits. Usg abdomen and Chest x-ray were normal. Usg neck revealed cervical lymphadenopathy (level II). Excision and biopsy was done under general anesthesia and HPE confirmed it to be Castleman's disease of hyaline vascular variant. IHC was advised subsequently.



**Fig 1-**Pre-Op picture showing lymph node enlargement at level 2 station on the right side of the neck.

### III. Discussion-

Castleman disease is a rare clinicopathological disease characterized by hyperplasia of lymph nodes and capillary proliferation. Both genders are equally affected.

Clinically CD is classified into: <sup>[5,6]</sup>

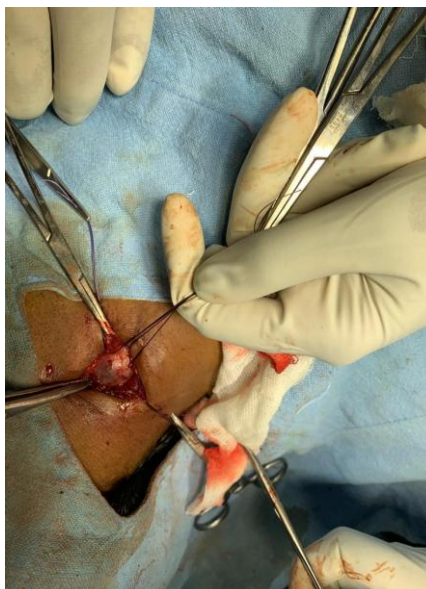
- A. Unicentric Castleman Disease (UCCD)
- B. HHV8 associated Multicentric Castleman Disease (MCCD-H)
- C. Idiopathic Multicentric Castleman Disease (IMCCD)

**UCCD:** It accounts for 70% of cases of CD. The most common site of involvement of unicentric Castleman's disease is the mediastinum, but it may occur anywhere in the lymphoid chain. Alternate sites include intra-abdominal masses or involvement of cervical, axillary, and inguinal nodes. A localized disease with involvement of a single group of lymph nodes. Systemic manifestations are absent or minimal. The patients are usually asymptomatic unless a compression on neurovascular site or other organs cause symptoms.

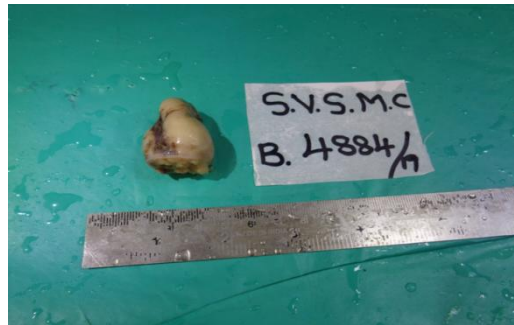**MCCD-H:** Human Herpes Simplex Virus 8 (HHV8) associated MCCD is a very aggressive disease [8] occurring in immunocompromised individuals due to the viral trigger and constitutes 65% of MCCD.

**MCCD:** It is a serious systemic disease often presenting with involvement of multiple lymph node stations. Constitutional symptoms like fever, weight loss and debility often occur. It can progress and become lethal due to: exaggerated systemic inflammatory response and multi-organ dysfunction caused by "Cytokine storm" often involving IL-6<sup>[5]</sup>. Hepatomegaly and/or splenomegaly occur in 90% of patients<sup>[9]</sup>.

**TREATMENT:** Complete surgical excision provides cure of the disease with no reported cases of recurrence in solitary mass form (UCCD). In IMCCD corticosteroids have been used to palliate symptoms before starting aggressive systemic chemotherapy. Monoclonal antibodies targeting CD-20 on B-cells (Rituximab) have been tried as a single agent as well as in combination with chemotherapy<sup>[6]</sup>. Highly active antiretroviral therapy (HAART) improves survival in HSSV-8 associated MCCD with HIV co-infection<sup>[6]</sup>.



**Fig 2-**Intra Op picture of the lymph node.



**Fig 3-**Specimen picture.

CD is classified into 4 recognizable histopathological variants:<sup>[6,10]</sup>

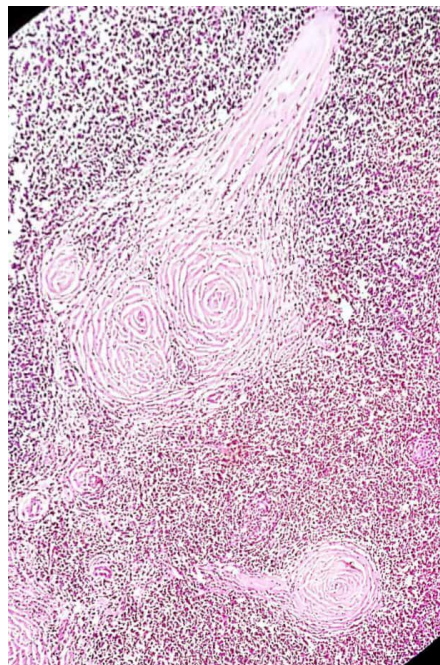
I) Hyaline vascular variant: Shows hyalinized vessels penetrating atrophic germinal centres with concentric rings of small lymphocytes widening the mantle zone (onion skin appearance).Germinal centres may have dysplastic follicular dendritic cells.

II) Plasma cell variant: Shows hyperplastic germinal centres with interfollicular polyclonal plasmacytosis.

III) Mixed variant.

IV) Plasmablastic- Exclusively seen in HSSV-8 associated MCCD.

Differential Diagnosis includes:Follicular Lymphoma,Angioimmunoblastic Lymphadenopathy and NHL in transition.



**Fig-4-**Hyaline vascular variant of Castleman's disease.

#### **IV. Conclusion**

Excisional biopsy must be performed for any atypical neck or head mass without systemic symptoms unresponsive to conservative management.Though clinically synonymous with lymphoma, it is an entity that is distinct from malignant lymphoproliferative disorders histologically and prognostically.Long term follow up is to rule any chance of recurrence as there is no significant treatment after excision in UCCD.

### References

- [1]. B. Castleman, L. Iverson, V.P. Menendez, Localized mediastinal lymph-node hyperplasia resembling thymoma, *Cancer* 9 (4) (1956) 822–830, [http://dx.doi.org/10.1002/1097-0142\(195607/08\)9:4<822::AID-CNCR2820090430>3.0.CO;2-4](http://dx.doi.org/10.1002/1097-0142(195607/08)9:4<822::AID-CNCR2820090430>3.0.CO;2-4).
- [2]. Olak, "Benign lymph node disease involving the mediastinum," in *General Thoracic Surgery*, T. W. Shields, J. LoCicero, C. E. Reed, and R. H. Feins, Eds., vol. 2, pp. 2366–2367, Lippincott Williams & Wilkins, Philadelphia, Pa, USA, 7th edition, 2009.
- [3]. Keller AR, Hochholzer L, Castleman B. Hyaline – vascular and plasma-cell types of giant lymph node hyperplasia of the mediastinum and other locations. *Cancer* 1972;29(3):670-683.[Medline].
- [4]. W.B. Bowne, J.J. Lewis, D.A. Filippa, et al., The management of unicentric and multicentric Castleman's disease, *Cancer* 85 (3) (1999) 706–717, [http://dx.doi.org/10.1002/\(SICI\)1097-0142\(19990201\)85:3<706::AID-CNCR21>3.0.CO;2-7](http://dx.doi.org/10.1002/(SICI)1097-0142(19990201)85:3<706::AID-CNCR21>3.0.CO;2-7).
- [5]. D.C. Fajgenbaum, T.S. Uldrick, A. Bagg, et al., International, evidence-based consensus diagnostic criteria for HHV-8-negative/idiopathic, Multicentric Castleman Dis. 129 (2017), <http://dx.doi.org/10.1182/blood-2016-10-746933>.
- [6]. H.E. El-Osta, R. Kurzrock, Castleman's disease: from basic mechanisms to molecular therapeutics, *Oncologist* 16 (4) (2011) 497–511, <http://dx.doi.org/10.1634/theoncologist.2010-0212>.
- [7]. Frizzera G, Massarelli G, Banks PM, Rosai J. A systemic lymphoproliferative disorder with morphological features of Castleman's Disease; Pathological findings in 15 patients. *Am J Surg Pathol* 1983; 7: 212–31.
- [8]. Dispenzieri A, Gertz MA. Treatment of Castleman's disease. *Curr Treat Options Oncol*. 2005;6:255–266.
- [9]. A.L. Melikyan, E.K. Egorova, H.L. Julhakyian, A.L. Kovrigina, V.G. Savchenko, Human herpesvirus type 8-positive multicentric Castleman disease, *Clin Lymphoma Myeloma Leuk*. 16 (2016) S159–S165, <http://dx.doi.org/10.1016/j.clml.2016.03.009>.
- [10]. R.A. Agha, A.J. Fowler, S. Rajmohan, et al., Preferred reporting of case series in surgery; the PROCESS guidelines, *Int. J. Surg*. 36 (2016) 319–323, <http://dx.doi.org/10.1016/j.ijso.2016.10.025>.

Dr. Ramesh Kumar Korumilli. "Castleman's Disease: A Rare Case Report." *IOSR Journal of Dental and Medical Sciences (IOSR-JDMS)*, vol. 18, no. 10, 2019, pp 27-30.