

## Liver abscess caused by *Acinetobacter lwoffii*

Dr. Dipti Gaikwad<sup>1</sup>, Dr. Vijay Pawar<sup>2</sup>, Ganesh Kadam<sup>3</sup>

<sup>1</sup>(Consultant microbiologist, Vishwaraj Hospital, Pune, India)

<sup>2</sup>(Consultant Surgeon, Vishwaraj Hospital, Pune, India)

<sup>3</sup>(Lab technician, Vishwaraj Hospital, Pune, India)

### Abstract:

We report a case of pyogenic liver abscess who presented with fever generalised body weakness, and pain in the abdomen. On examination patient had tenderness in right hypochondriac region. Ultrasonography of the abdomen showed enlargement of the liver with features suggestive of abscess in the right lobe and left lobe. Ultrasound guided liver aspiration was done. Gram stain from the pus sample showed presence of Gram negative coccobacilli. Pan sensitive *Acinetobacter lwoffii* grew in culture. Patient recovered well after intravenous antimicrobial therapy. *Acinetobacter lwoffii* is emerging as a pathogen in both hospital and community settings.

**Key Word:** *Acinetobacter lwoffii*, pyogenic liver abscess

Date of Submission: 20-11-2020

Date of Acceptance: 06-12-2020

### I. Introduction

*Acinetobacter lwoffii*, a nonfermentative gram-negative aerobic bacillus, which presents in the normal flora of the oropharynx and skin, has recently been reported as a cause of human infection in patients with impaired immune system.<sup>[1]</sup> Herein, the authors present a case report of pyogenic liver abscess in an otherwise healthy adult. There are very few cases of liver abscess due to *Acinetobacter lwoffii*, hence this case is reported due to its rarity.

### II. Case Report

A 66-year-old man, presented to the casualty of our hospital with the complaint of high grade fever, generalised weakness since last one week. Patient also gave history of pain in abdomen which was usually located in the right hypochondrium since last one week. There was no history of diabetes or any other co morbidity. No history of tuberculosis or similar episode in the past. No relevant family history was present.

On examination he was conscious, febrile (Temperature-100.4 °F), pulse rate 90/min and blood pressure were 90/60 mmHg. He had pallor and mild icterus. On per abdominal examination there was tenderness in right hypochondriac region. Rest of systemic examination was within normal limit. Laboratory investigation revealed hemoglobin 10.2 gm/dl, total leukocytes count 12000/cumm, (polymorphs 82 %, lymphocytes 10%, eosinophil 1%), Platelet count of 3.79 lacs/cumm, liver enzymes (SGOT/SGPT-80/101), coagulation profile (PT/INR-13.10/1.09) and Alkaline phosphatase was 187 IU. Renal function and serum electrolytes were within references range. Serology for Hepatitis B surface antigen, HIV and other hepatitis markers (HCV) were non-reactive. Ultrasonography of the abdomen showed enlargement of the liver with features suggestive of abscess measuring 9.0cm×7.0cm×6.1cm and volume 200CC in the right lobe and a similar lesion measuring 6.6.cm x 3.4 cm x 5.8 cm was seen in left lobe. The findings were confirmed on CT scan.

Ultrasound guided liver aspiration was done. About 30ml of pus was sent for microbiological investigations, for culture and sensitivity. The pus sample received was processed as per standard microbiological protocol. A wet mount of pus was negative for Trophozoites of *Entamoeba histolytica*. Ziehl-Nelsen was negative for acid fast bacilli. Direct Gram's stain showed Gram negative cocci and pus cells [Fig-1]. Smooth opaque colonies of around 2–3mm diameter grew on blood agar and non-lactose fermenting colonies on Mac-Conkey agar. The isolate was identified as *A.lwoffii* on the basis of biochemical reactions with cytochrome oxidase (negative), oxidative/fermentative glucose (negative), nitrate reduction (negative). It was confirmed by automated technique with Vitek-2 system. It was found to be susceptible for Amikacin, tobramycin, gentamicin, cefotaxime, cefepime, piperacillin tazobactam, carbapenems, quinolones and colistin. The patient was given injectable ceftriaxone, Amikacin and Metronidazole. Patient recovered well and was discharged on sixth day.

### III. Discussion

The most common pathogens associated with Pyogenic liver abscess are *Escherichia coli*, *Klebsiella pneumoniae*, *Bacteroides*, *Enterococci*, *Streptococci*, and *Staphylococci*.<sup>[2]</sup> *Acinetobacter lwoffii* was first reported to be causing pyogenic liver abscess in 2016 by Singh et al [1]. The patient was a diabetic and was on irregular anti hyperglycaemic drugs. In 2018 Mohanty et al presented a case of liver abscess by *A. lwoffii* in an immunocompetent patient, however the patient was an alcoholic which could have contributed to lowering his immune status.<sup>[3]</sup> *Acinetobacter* species infections tend to occur in patients with chronic diseases as diabetes mellitus, chronic obstructive pulmonary disease, renal disease, heavy smoking, and excess alcohol consumption.<sup>[4]</sup> Here we have presented a rare case of pyogenic liver abscess caused by *A. lwoffii* in an adult with no obvious co morbidities.

*Acinetobacter* species were considered as low pathogenic during 1960s but with the introduction of powerful new antibiotics in clinical practice and agriculture and the use of invasive procedures in hospital intensive care units (ICUs), drug resistant-related community and hospital-acquired *Acinetobacter* infections have emerged with increasing frequency.<sup>[5]</sup> Among its species, *A. baumannii* has emerged as a greatest clinical importance and is associated with hospital outbreaks. But infections due to other species like *A. lwoffii* have also been reported in hospitals and community settings.<sup>[6,7]</sup> Due to its ubiquitous nature, it is a potential opportunistic pathogen in individuals with impaired immune system, and it has been identified as a cause of nosocomial and community acquired infections like septicaemia, bacteraemia, bacteriuria, pneumonia and endocarditis.<sup>[1]</sup> However our patient had no history for previous hospitalisation, intake of higher antibiotics or co morbidities

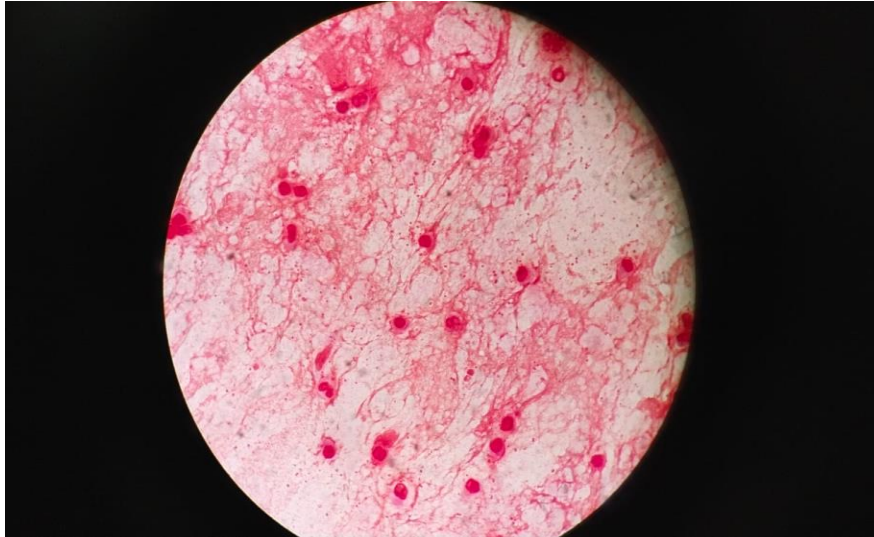
Our strain was found to be pan sensitive but many studies have reported the high rates of antibiotic resistance in *Acinetobacter* species. Mittal et al., reported high resistant to imipenem (57%), cotrimoxazole (57%), gentamicin (82%), piperacillin + tazobactam (61%) in *A. lwoffii* as compared to other non-baumannii *Acinetobacter* spp in nosocomial infections.<sup>[6]</sup> *Acinetobacter* species has been known to produce variety of beta – lactamases which confer resistance to aminopenicillins, ureidopenicillins, narrow-spectrum and expanded-spectrum cephalosporin, cephamycins. Partial susceptibility is retained for some relatively new antibiotics such as broad-spectrum cephalosporin (cefotaxime, ceftazidime, and cefepime), tobramycin, imipenem, amikacin, and fluoroquinolones.<sup>[8]</sup> Since our patient did not recall any previous history of hospital stay or prolonged antibiotic intake and our strain was pan sensitive, we presumed it to be community acquired infection.

### IV. Conclusion

This is the rare case report of community acquired liver abscess caused by *A. lwoffii*. Apart from *A. baumannii* other species are also emerging as pathogens in both hospital and community settings. Preventive measures need to be taken to halt the emergence of new drug resistant species.

### References

- [1]. N Singh, T Sagar, K Nirmal, P Kuar, Pyogenic Liver Abscess Caused by *Acinetobacter lwoffii*: A Case Report, *Journal of Clinical and Diagnostic Research*, 10(6), 2016, 1-2.
- [2]. L Meddings, R Myers, J Hubbard, A Shaheen, K Laupland, E Dixon, et al. A population-based study of pyogenic liver Abscess in the United States: Incidence, mortality, and temporal trends, *American Journal of Gastroenterology*, 105, 2010, 117- 24
- [3]. A Mohanty, A Kabi, A Mohanty, *Acinetobacter lwoffii* - Emerging pathogen causing liver abscess: A Case Report, *National Journal of Integrated Research in Medicine*, 9(5), 2018, 53-54
- [4]. M Tas, M Oguz, M Ceri, *Acinetobacter lwoffii* Peritonitis in a Patient on Automated Peritoneal Dialysis: A Case Report and Review of the Literature, *Case Reports in Nephrology* 2017, 1-2
- [5]. L Guardabassi, A Dalsgaard, J Olsen. Phenotypic characterization and antibiotic resistance of *Acinetobacter* spp. isolated from aquatic sources. *Journal of applied Microbiology*, 87(5), 1999, 659-67.
- [6]. S Mittal, M Sharma, A Yadav, K Bala, U Chaudhary. *Acinetobacter lwoffii* An emerging pathogen in neonatal ICU, *Infectious Disorders – Drug Targets*, 15 (3), 2015, 184-188.
- [7]. G Silva, L Morais, L Marques, V Senra. *Acinetobacter* community-acquired pneumonia in a healthy child, *Revista Portuguesa de Pneumologia*, 18(2), 2012, 96-98.
- [8]. L Tega, K Raieta, D Ottaviani, G Russo, G Blanco, A Carraturo. Catheter-related Bacteraemia and Multidrug-resistant *Acinetobacter lwoffii*, *Emerging Infectious Disease*, 13(2), 2007, 355-356.



**Fig.1 : Gram stain showing pus cells and Gram negative cocci.**

Dr.Dipti Gaikwad, et. al. "Liver abscess caused by *Acinetobacter lwoffii*." *IOSR Journal of Dental and Medical Sciences (IOSR-JDMS)*, 19(12), 2020, pp. 58-60.