

Periodontal esthetics: Gingival veneers – A Case Report

Dr. Maya Sanjiv Indurkar¹, Dr. Jui Sarfare²

1. Head of Department And Professor Department of Periodontology and Implantology
Government Dental College and Hospital, Aurangabad, India

2. Post graduate 2nd year student Department of Periodontology and Implantology
Government Dental College and Hospital, Aurangabad, India

Abstract: Development of gingival marginal and papillary recession is common sequelae of periodontal disease impairing the esthetic and functional activity making surgical management at times difficult. A non-surgical conservative approach was carried out in this case report to tackle the recession in a novel way using pink coloured composites/ gingival composites to achieve good pink and white appearance and maintain oral hygiene. Gingival composites are available in various shades to allow matching with the tissue and can be used to restore cervical abrasions due to traumatic tooth brushing, gingival recession, papillary deficiency.

Key-words: gingival veneers, esthetics, pink composite, recession

Date of Submission: 26-05-2020

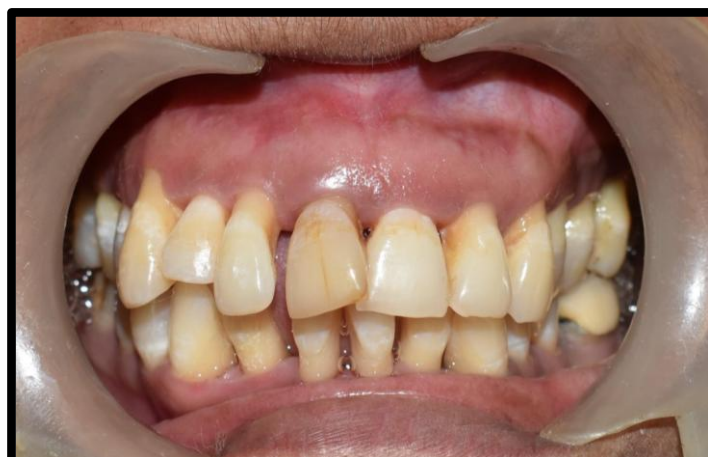Date of Acceptance: 13-06-2020

I. Introduction

Chronic periodontal disease results in destruction and degeneration of the supporting bone and the periodontium. Consequently, it may lead to increased bone loss, attachment loss, gingival recession, mobility, and drifting of teeth.¹ Gingival recession and loss of the interdental papilla (also known as open gingival embrasures or black triangles) impairs oral hygiene maintenance, contributes to retention of food debris adversely affecting the health of the periodontium, impairs the esthetics, exposed root causes dentinal hypersensitivity and is susceptible to root caries.² Reconstruction of this lost interdental papilla is difficult surgically, according to Tarnow et al., the distance between the contact point and alveolar crest should be at least 5 mm for the formation of the interdental papilla.³ Also, treatment of gingival recession depends on type of recession, Class I and II can be managed surgically whereas severe and extensive recession involving multiple teeth can be managed non-surgically with a gingival prosthesis after control of periodontal disease, as surgical reconstruction becomes difficult due to inadequate bone support.⁴ With the advent of gingival composites, it is possible to provide esthetic, comfortable and accurately fitting gingival veneers, that will restore the interdental papilla and gingival recession. This method is an innovative treatment option for dealing with esthetic challenges which cannot be managed surgically.²

II. Case Report

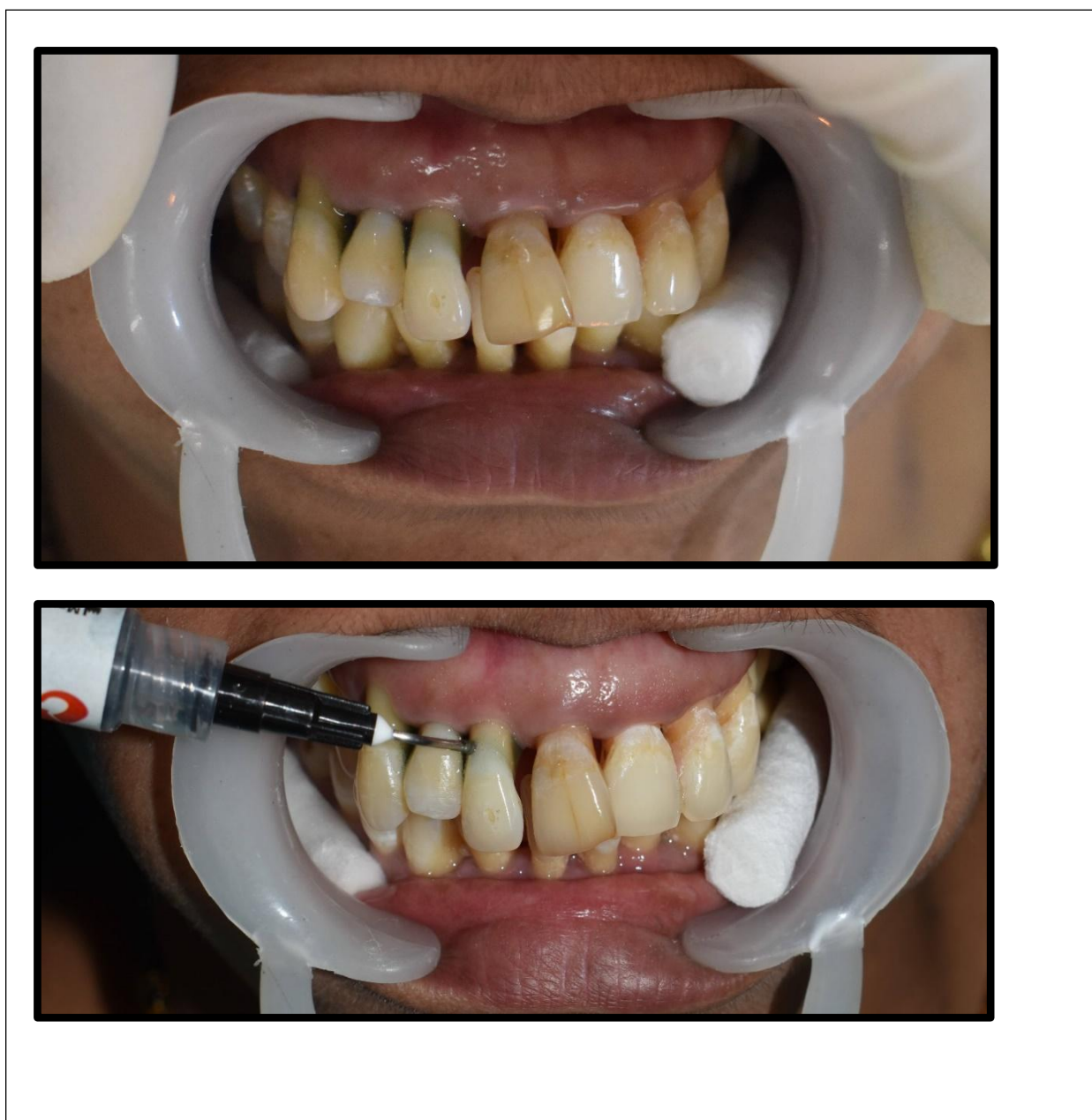A 38-year-old female patient reported to the Department of Periodontics, Aurangabad with the chief complaint of bleeding, receding gums and open spaces between teeth causing food accumulation. Also the patient was dissatisfied with the appearance of her existing dentition [Figure 1].

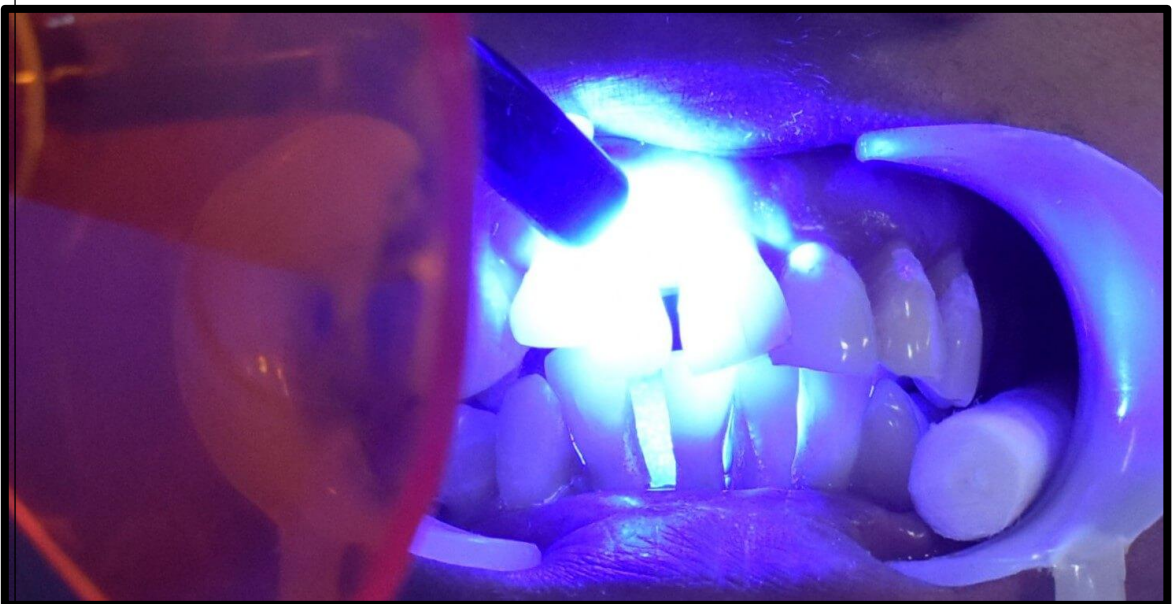
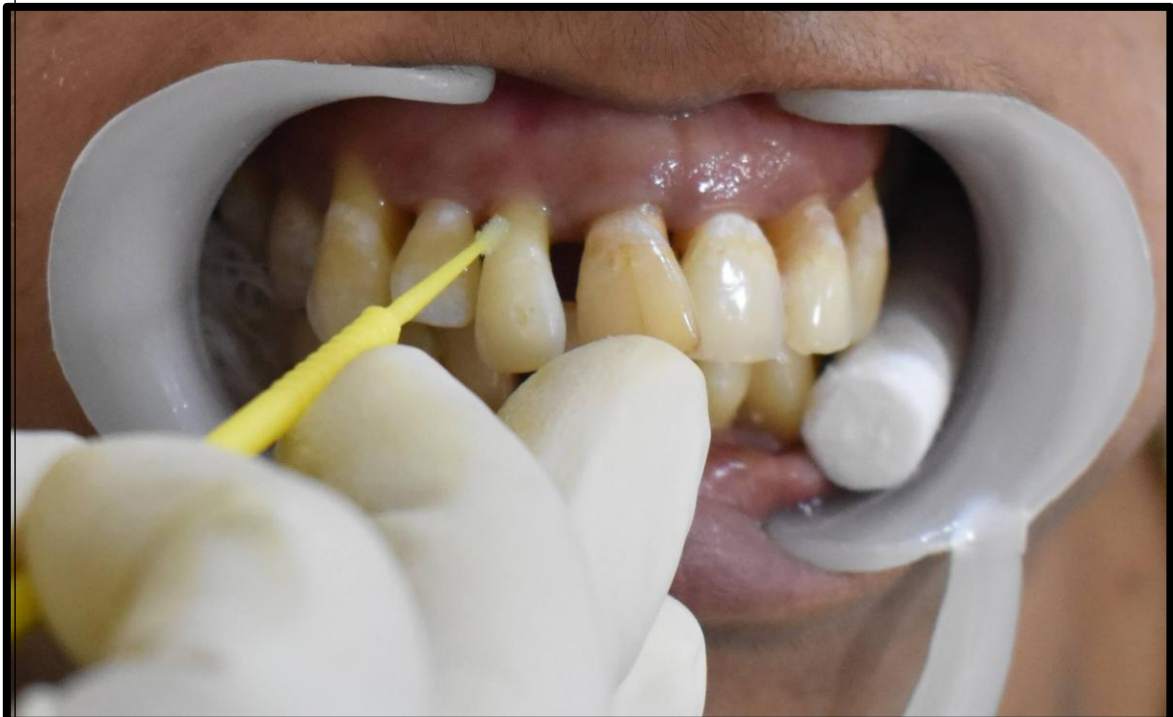

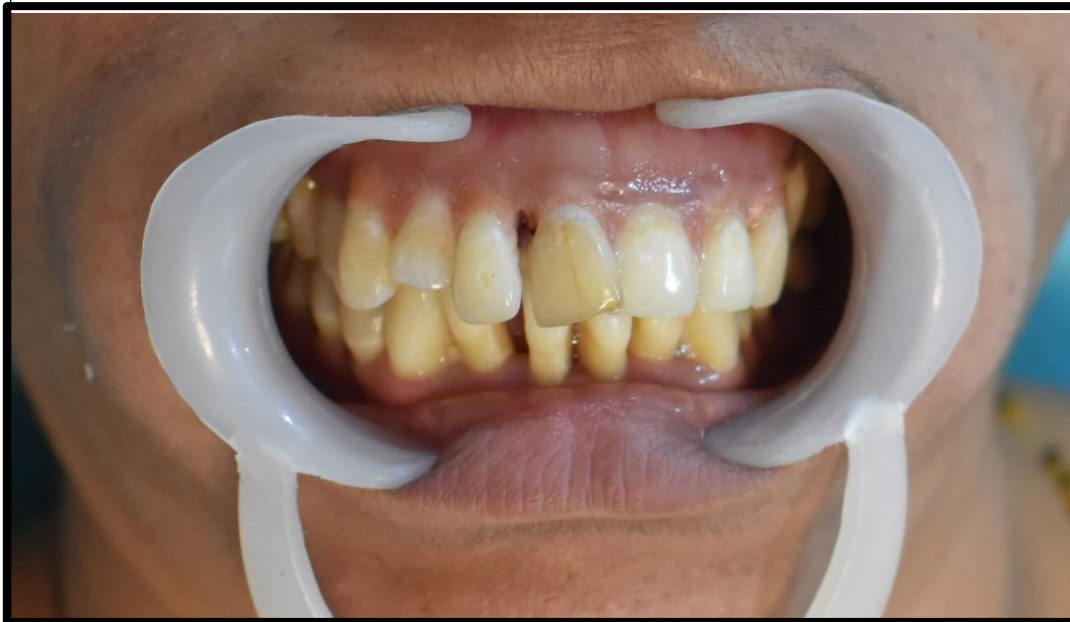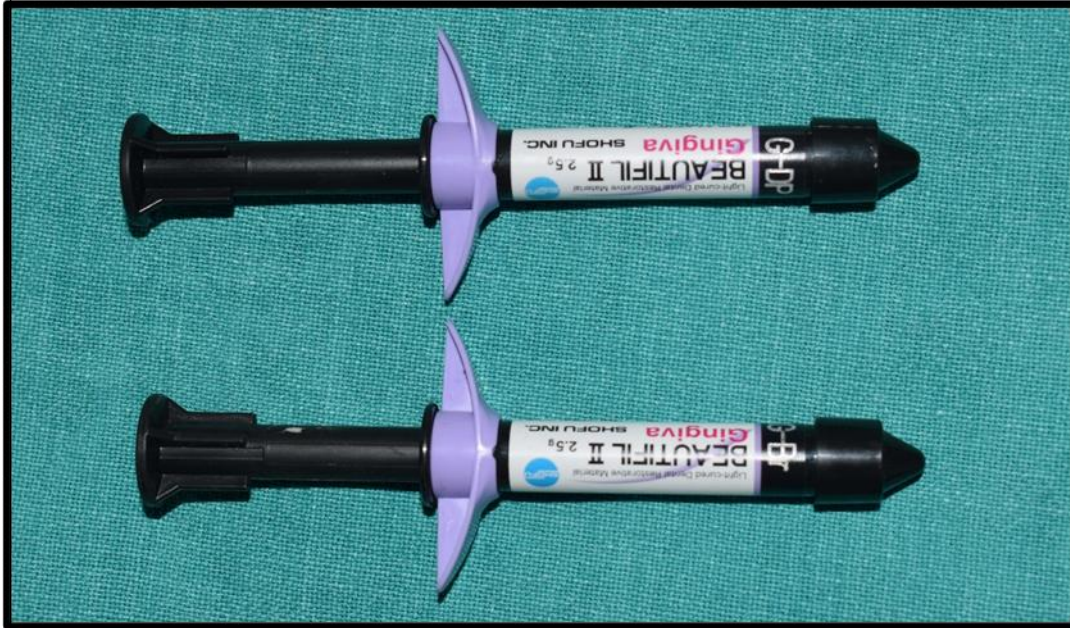On clinical examination, patient had no relevant medical history, had gingival recession with loss of the interdental papilla involving maxillary (13, 12, 11, 21, 22, 23) with no contact point between 11 and 12, pinkish brown pigmentation of the marginal and attached gingiva and the pockets measured in the range of 3-4mm. The treatment plan was to first eliminate the periodontal inflammation, followed by rehabilitation using gingival composite (pink coloured composite) for the maxillary anteriors as the bone loss between the maxillary anteriors was extensive to obtain complete reconstruction of the gingival tissues by surgical technique.

Procedure:

Prior to beginning the procedure shade matching was done. The teeth were isolated and etched using 37% phosphoric acid for 30 seconds [Figure 2]. Teeth were then blotted dry and dental adhesive bonding agent (Ivoclar bonding agent) was applied and light cured according to manufacturers' instructions [Figure 3]. The lost tissues were constructed using pink colored composite (SHOFU Beautiful ii Composite – Dark pink / Brown) in layered pattern. The interproximal areas were built-up first followed by the marginal area [Figure 4]. Final contouring was performed using a composite finishing and polishing system. Patient was given post-operative oral hygiene instructions and kept on follow up.







III. Discussion

Patients with advanced periodontitis are at high risk for gingival recession and open gingival embrasures (“black triangles”). Surgical treatment for the aesthetic and functional problems caused by open gingival embrasures are often insufficient to re-establish ideal aesthetics.

Gingival restoration with gingival coloured “pink” composite resin materials can overcome the limitations of grafting and can be a good alternative for reconstructing tissue lost due to extensive alveolar bone loss.⁵

In this case report, gingival composite material has been tried for restoration. This is an easy technique to achieve esthetics and is less time consuming.

Important points to be considered for this technique are:

1. It is anesthetic chairside composite restorative procedure which can be adapted to manage cases of papillary deficiency and gingival recession non-surgically after control of periodontal inflammation.

2. The patient should be advised for good plaque control and maintenance of the prosthesis. A disadvantage of this technique is that it may require a change of restoration due to color instability after a period of time.

IV. Conclusion

Use of pink coloured composites is a novel way to manage non-surgically the recession and papillary deficiency in individuals to satisfy the esthetic needs and maintain oral hygiene.

References

- [1]. Newman MG, Takei H, Klokkevold PR, Carranza FA. Carranza's Clinical Periodontology. 10 th ed. St. Louis, Missouri, United States: Saunders Elseviers; 2007. p. 494-500.
- [2]. Wahbi MA, Al Sharief HS, Tayeb H, Bokhari A. Minimally invasive use of coloured composite resin in aesthetic restoration of periodontially involved teeth: Case report. The Saudi dental journal. 2013 Apr 1;25(2):83-9.
- [3]. Tarnow DP, Magner AW, Fletcher P. The effect of the distance from the contact point to the crest of bone on the presence or absence of the interproximal dental papilla. Journal of periodontology. 1992 Dec;63(12):995-6.
- [4]. Patel M, Nixon PJ, Chan MY. Gingival recession: Part 1. Aetiology and non-surgical management. British dental journal. 2011 Sep;211(6):251-4.
- [5]. Coachman C, Salama M, Garber D, Calamita M, Salama H, Cabral G. Prosthetic gingival reconstruction in a fixed partial restoration. Part 1: introduction to artificial gingiva as an alternative therapy. International Journal of Periodontics & Restorative Dentistry. 2009 Sep 1;29(5).

Dr. Maya Sanjiv Indurkar, et. al. "Periodontal esthetics: Gingival veneers – A Case Report." IOSR Journal of Dental and Medical Sciences (IOSR-JDMS), 19(6), 2020, pp. 39-43.