

## Minimal invasive spine surgery for long segment fixation in Symptomatic Andersons lesion in Ankylosing Spondylitis in a young male with Brugada Syndrome

Shrinivas P Prabhu<sup>1</sup>, Kumar Shetty<sup>2</sup>, Vikas Gupte<sup>3</sup>

<sup>1</sup> Clinical Fellow in Minimal invasive spine surgery, Fortis Hospital, Mumbai

<sup>2</sup> Consultant spine surgeon, Fortis Hospital, Mumbai

<sup>3</sup> Senior Consultant spine surgeon and Head, Fortis Hospital, Mumbai

---

### Abstract

**Introduction:** The Brugada syndrome (BrS) is an inherited cardiac arrhythmia syndrome associated with a high risk for sudden cardiac death in young adults. An implantable cardioverter defibrillator (ICD) is the most widely accepted approach to therapy. The aims of treating symptomatic Andersons lesion in AS are to stabilize the ankylosed spine, relieve symptoms, decrease functional limitations, and reduce complications.

Minimal invasive spine surgery enables us to achieve stable fixation while reducing intraoperative stress and blood loss in these patients.

**Case report:** The aims of treating AS are to stabilize the ankylosed spine, relieve symptoms, decrease functional limitations, and reduce complications.

Minimal invasive spine surgery enables us to achieve stable fixation while reducing intraoperative stress and blood loss in these patients.

**Discussion :** Posterior Long segment stabilisation D11 to L5 by minimal invasive technique with multiple paraspinous stab incisions. In this way we were able to overcome the primary limitation of not using cauterization for hemostasis owing to ICD implantation for Brugada syndrome.

**Conclusion:** Posterior Long segment stabilisation D11 to L5 by minimal invasive technique with multiple paraspinous stab incisions.

In this way we were able to overcome the primary limitation of not using cauterization for hemostasis owing to ICD implantation for Brugada syndrome.

**Keywords:** Ankylosing spondylitis, Andersons lesion, Brugada syndrome, Minimal invasive spine surgery

---

Date of Submission: 18-07-2020

Date of Acceptance: 02-08-2020

---

### I. Introduction

The Brugada syndrome (BrS) is an inherited cardiac arrhythmia syndrome electrocardiographically characterized by distinct coved type ST segment elevation in the right precordial leads, the syndrome is associated with a high risk for sudden cardiac death in young adults. An implantable cardioverter defibrillator (ICD) is the most widely accepted approach to therapy.<sup>1</sup>

Anderson's lesion may result from inflammation or stress fractures of the complete ankylosed spine.<sup>10</sup> The aims of treating AS are to stabilize the ankylosed spine, relieve symptoms, decrease functional limitations, and reduce complications.

Minimal invasive spine surgery enables us to achieve stable fixation while reducing intraoperative stress and blood loss in these patients thus improving surgical outcome.

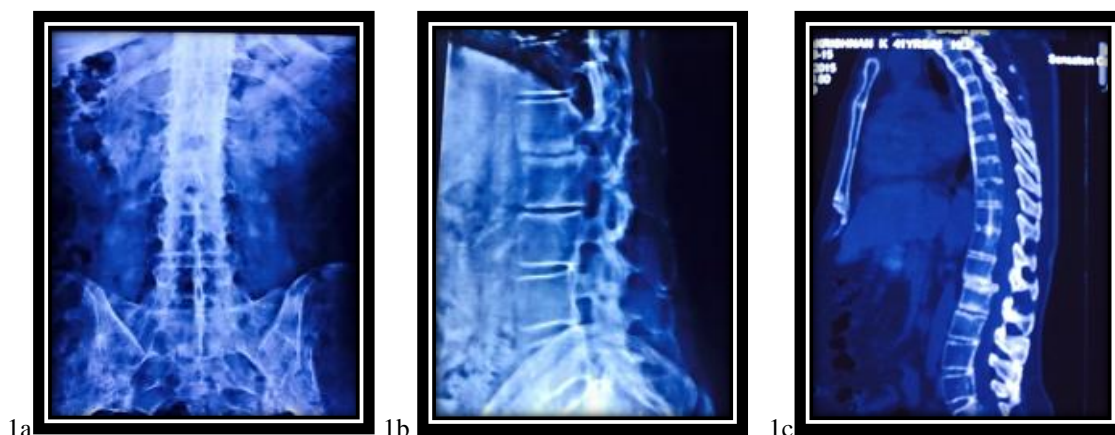
### II. Case Report

**History:** 27 year old male of Indian origin living in Muscat was diagnosed with a unique genetic disorder -Brugada syndrome and autoimmune Ankylosing spondylitis of the spine with Andersons lesion at L1-L2.

Patient complained of severe back pain at dorso-lumbar junction which increased progressively over the past 6 months and presently affecting his ADL.

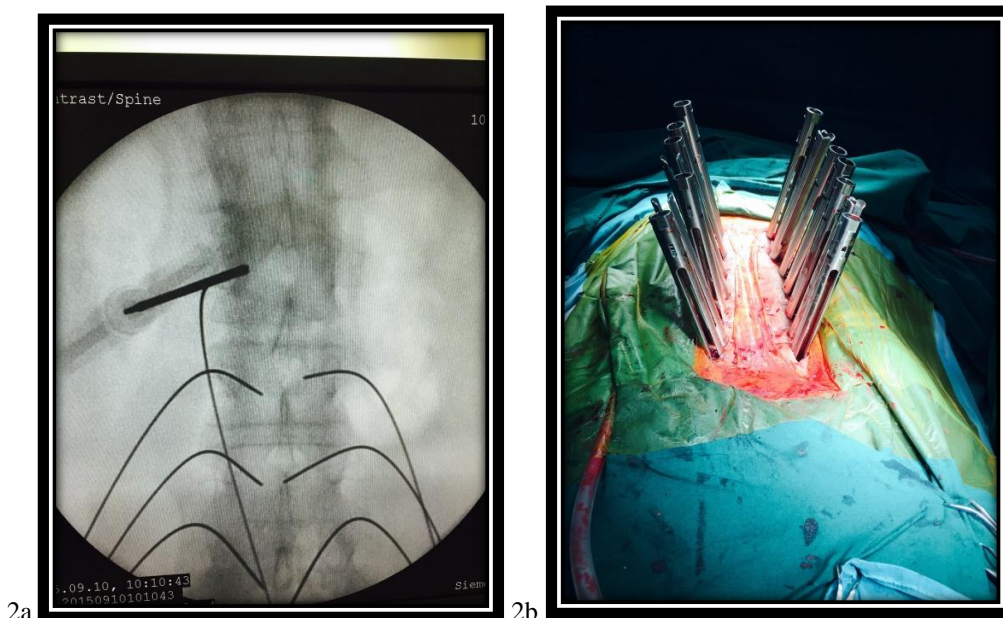
**Physical examination:** Tenderness present over dorsolumbar spine. Paraspinal muscle spasm present. Rom painful and restricted globally. Neurologically normal.

**Radiological investigation:** Xrays/MRI/CT scans showed ‘‘ Anderson's Lesion’’ at L1-2; a feature in Ankylosing spondylitis of the spine. And instability on dynamic views with no cord compression on MRI.

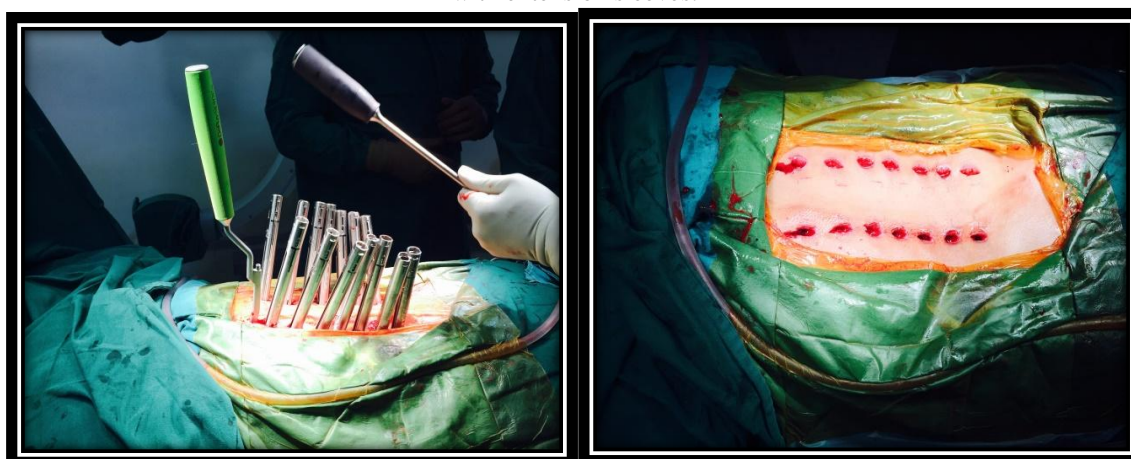


**Figure 1:** Pre operative Xray and CT showing Anderson's lesion L1, L2

**Management plan:** Posterior Long segment stabilisation D11 to L5 by minimal invasive technique with multiple paraspinous stab incisions. In this way we were able to overcome the primary limitation of not using cauterization for hemostasis owing to ICD implantation for Brugada syndrome.



**Figure 2:** Percutaneous Transpedicular Guidewire inserted and Percutaneous Transpedicular screws inserted with extension sleeves.

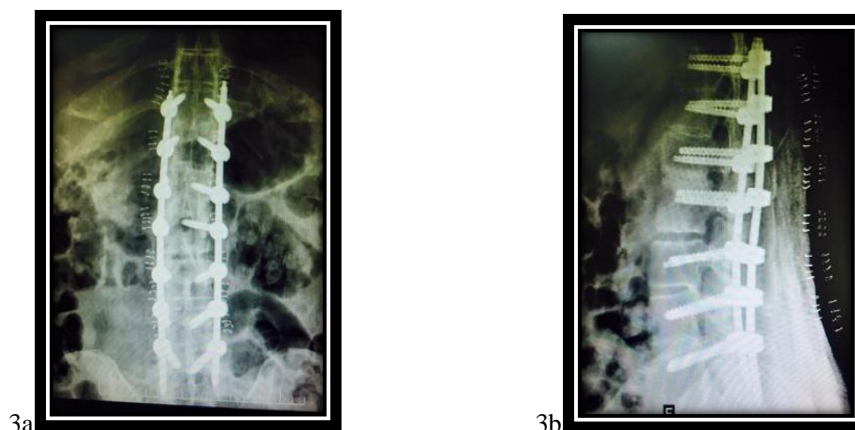


**Figure 4:** Subfascial rod insertion and stab incisions after removal of extension sleeves

**Post operative management:** Taylors spinal brace for spine support and mobilization and physiotherapy for spine and core strengthening.

At 2 weeks follow up suture removal done and aggressive physiotherapy started

At 2 month followup patient has significant relief of back pain and has excellent mobilization with Taylors Brace.



**Figure 3:** Postoperative xray with D12 to L5 stabilisation

### III. Discussion

**Ankylosing spondylitis (AS)** is a chronic inflammatory disease that primarily affects the spine and sacroiliac joints, causing pain, stiffness and a progressive thoracolumbar kyphotic deformity.<sup>8</sup>

A well-known complication in these patients is the development of a localised vertebral or discovertebral lesions of the spine, which was first described by Andersson in 1937.<sup>9</sup>

AL may result from inflammation or (stress-) fractures of the complete ankylosed spine. There is no evidence for an infectious origin. The diagnosis of AL is established on conventional radiography, but computed tomography and magnetic resonance imaging both provide additional information. There is no indication for a diagnostic biopsy. Surgical instrumentation and fusion is considered the principle management in symptomatic AL that fails to resolve from a conservative treatment.<sup>10</sup>

The aims of treating AS are to stabilize the ankylosed spine, relieve symptoms, decrease functional limitations, and reduce complications.

**Brugada syndrome:** Patients who have had an ICD implanted for Brugada syndrome should be programmed with the tachyarrhythmia therapy of the device when disabled.<sup>2</sup>Brugada syndrome patients with and without an ICD should have external defibrillator pads placed with an external defibrillator readily available.<sup>3,4,5</sup>For patients who require pacing, the ICD (or pacemaker if the patient had a device implanted for bradyarrhythmia therapy only), should be reprogrammed to a nontracking or nonsensing mode such as VOO or DOO depending on the presence of a single or dual chamber device respectively.<sup>2,3</sup> This programming change is to prevent the device from detecting electrical interference from electrocautery or other electronic equipment in the operating room. Such interference may result in an inappropriate shock by an ICD and inhibition of pacing by the pacemaker function.<sup>3</sup>

**Role of minimal invasive spine surgery:** The intraoperative period is notable for multiple stressors, both leading to sympathetic activity (surgical incision, endotracheal intubation, anesthetic induction, and emergence) as well as sudden increases in parasympathetic tone (tracheal suctioning, peritoneal insufflation, and bowel retraction).<sup>6</sup>

With minimal invasive surgical techniques, we were able to reduce the likelihood of these stress risers by avoiding a long midline incision and extensive muscle dissection, in place of which we performed long segment fixation using multiple stab incisions and muscle splitting localized over the pedicular entry point under image intensifier guidance.

Minimal invasive spine surgery also enables us to minimize blood loss and thereby, avoid the use of electrocautery which may interfere with the functioning of the ICD.

In addition to the above advantages we were able to achieve a long segment stabilization enabling early mobilization and recovery in this young patient with Anderson's lesion in dorsolumbar spine with Ankylosing Spondylosis.

#### **IV. Conclusion**

Minimal invasive spine surgery is an excellent choice for long posterior percutaneous stabilization in patients with autoimmune Ankylosing Spondylosis with Brugada syndromewhere use of electrocautery is avoidable due to implanted devices like ICD and cardiac pacemakers. This method is also beneficial in terms of reducing blood loss and enhanced post operativerecovery.

#### **References**

- [1]. Charles Antzelevitch, BencePatocskai. Brugada Syndrome. Clinical, Genetic, Molecular, Cellular and Ionic Aspects.CurrProblCardiol. 2016 January ;41(1)57.doi:10.1016/j.cpcardiol.2015.06.002.
- [2]. Carey SM, Hocking G.Brugada syndrome – A review of the implications for the anaesthetist. Anaesth Intensive Care 2011;39:571- 7.
- [3]. Cordery R, Lambiase P, Lowe M, Ashley E. Brugadasyndrome and anesthetic management. J CardiothoracVascAnesth 2006;20:407- 13.
- [4]. Edge CJ, Blackman DJ, Gupta K, Sainsbury M. Generalanaesthesia in a patient with Brugada syndrome. Br JAnaesth 2002;89:788- 91.
- [5]. Kim JS, Park SY, Min SK, Kim JH, Lee SY, Moon BK, et al.Anaesthesia in patients with Brugada syndrome. ActaAnaesthesiolScand 2004;48:1058- 61
- [6]. Inamura M, Okamoto H, Kuroiwa M, Hoka S. Generalanesthesia for patients with Brugada syndrome. A reportof six cases. Can J Anaesth 2005;52:409- 12.
- [7]. vanRoyen, B. J., de Kleuver, M. & Slot, G. H. Polysegmental lumbar posteriorwedge osteotomies for correction of kyphosis in ankylosing spondylitis. Eur.Spine J. 7, 104–110 (1998).
- [8]. Von Bechterew W (1893) Steifigkeit der wirbelsäule und ihreVerkrümmungalsbesondereErkrankungsform. NeurologischesZentralblatt 12:426–434
- [9]. AnderssonO(1937) Röntgenbilden vid spondylarthritisan kylopoetica.Nord Med Tidskr 14:2000–2002.
- [10]. Johannes L. Bron&Mirjam K. de Vries&Marieke N. Snieders&Irene E. van der Horst-Bruinsma&Barend J. van Royen. Discovertebral (Andersson) lesions of the spine in Ankylosing spondylitis revisited .ClinRheumatol (2009) 28:883–892. DOI 10.1007/s10067-009-1151-x

Shrinivas P Prabhu, et. al. “Minimal invasive spine surgery for long segment fixation in Symptomatic Andersons lesionin Ankylosing Spondylitis in a young male with Brugada Syndrome.” *IOSR Journal of Dental and Medical Sciences (IOSR-JDMS)*, 19(8), 2020, pp. 22-25.