

Noonan Syndrome with Congenital Nasolacrimal Duct Obstruction: A Case Report

Harika Anne¹, Anees Fatima², Sri Lakshmi Sikhakolli³
(Sankara Eye Hospital, Guntur, Andhra Pradesh, India)

Abstract: Purpose : Noonan Syndrome is a genetic condition inherited in an autosomally dominant manner ,characterised by short stature , facial abnormalities , congenital heart disease , urogenital malformations , ocular features and mild developmental delay and the somatic features of Turner's syndrome , but a normal karyotype.(1)

Above 95% of patients have some ocular abnormalities presenting with downward slanting lid fissures , hypertelorism , epicanthal folds , ptosis , strabismus , amblyopia , optic nerve abnormalities , cataracts and pan uveitis.(1,2)

A 14-year old patient suspected of having NS presented with complaints of watering in right eye since birth.

Key Word: Noonan syndrome , eye signs .

Date of Submission: 20-05-2021

Date of Acceptance: 05-06-2021

I. Introduction

This disease is characterised by short stature , webbed neck , low-set ears , pectus excavatum / cranium , cardiac anomalies , thrombocytopenia , abnormalities of coagulation factors in 50% of cases , cryptorchidism , disabilities with speech , hearing loss , moderate mental retardation , lymphatic system pathologies , pigmentation disorders. Eye signs usually occur as hypertelorism , downset palpebral fissures , high upperlid crease , epicanthal folds , ptosis , ocular mobility mostly of the levator , prominent corneal nerves , anterior stromal dystrophy , strabismus , amblyopia , nystagmus , coloboma , keratoconus and cataracts.(3,4)

Half of the cases are sporadic approximately and an autosomal dominant transition is observed mostly. Rarely , autosomal recessive cases have also been reported. NS can be diagnosed clinically but if possible , genetic testing is important.(5) NS should be managed in a multidisciplinary manner. A comprehensive evaluation by an ophthalmologist is generally recommended at diagnosis with subsequent annual follow-ups.(6,7)

II. Case Report

A 10 – year old male patient presented to the clinic with complaint of watering from right eye associated with mucopurulent discharge since birth. The patient was evaluated and diagnosed with NS clinically. Genetic testing was not possible.(due to pandemic- COVID-19)The patient's height was 128 cm and the weight was 20 kgs. He had webbed neck , low-set ears , pectus excavatum. Ultrasonography of abdomen showed sludge in gall bladder , B/L medullary pyramid calcification. On CVS examination , murmurs were heard. Echocardiography showed CHD – small PDA. Neurosonogram was normal at study.

The Visual acuity was 6/6 in both eyes. He had hypertelorism , epicanthal folds. On Hirschberg test visual axis was orthophoric. Eye movements and convergence were evaluated as normal. The levator function was normal in each eye (15 cm). He presented with watering from right eye associated with mucopurulent discharge. On examination , regurgitation test was positive in right eye and tear film height was increased. No additional pathology was found on biomicroscopic and funduscopy evaluation. Intraocular pressures were measured with goldmann applanation tonometry (13mmHg in right eye and 15mmHg in left eye – without any medications).




Figure 1 : A 10-year old male patient with Noonan syndrome. (Permission for using this photograph was obtained from the patient’s family).

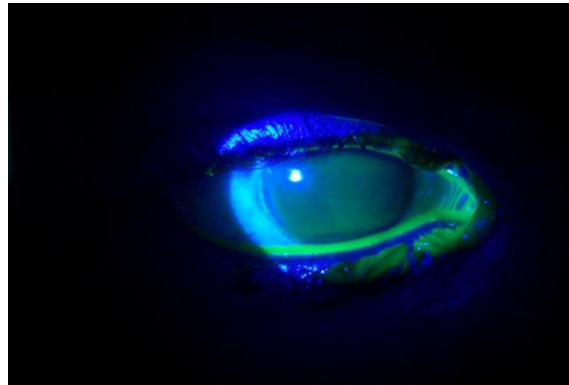
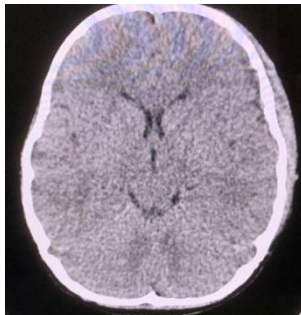


Figure 2 : Anterior segment photograph of right eye – showing increased tear film height on fluorescein staining.



The patient was sent for paediatrician for further evaluation. Complete blood picture - Hb – 9 gm/dl , TLC – 8,600 , Platelet count – 1,70,000 , BT ,CT were normal. No conduction defects on ENT evaluation. CT BRAIN – PLAIN was normal , CT CHEST – PLAIN was normal. Figure – 3 – showing normal study of CT – BRAIN of the patient.

Patient underwent Right eye External Dacryocystorhinostomy with intubation under general anaesthesia.

III. Discussion

NS is a rare autosomal dominant inherited disease. The incidence of NS is between 1 in 1000 to 1 in 2500 live births. Although NS diagnosis can be made on the basis of the clinical evaluation , but genetic testing is important if possible. The most commonly detected pathogenic variants are in PTP N11 (about 50% of cases) , SOS 1 (13%) , RAF 1 (5%) and RIT 1 (5%). Other genes such as KRAS , BRAF , LZTR 1 and NRAS are less commonly involved.(4,5,7,19)

Although NS may be easy to diagnose because it is contained in an extremely heterogenous group of abnormalities , a diagnostic criteria can be helpful in early diagnosis and treatment of anomalies.

Feature	Major	Minor
1. Facial	Typical Facial Dysmorphology	suggestive facial dysmorphology
2. Cardiac	pulmonary valve stenosis, cardiomyopathy , or electrocardiographic results typical of noonan syndrome	other defect
3. Height	<3rd percentile	<10th percentile
4. Chest wall	pectus excavatum/craniatum	broad thorax
5. Family History	first degree relative with definite noonan syndrome	first degree relative with suggestive nonnan syndrome

6. Other features	all of the following intellectual disability, cryptorchidism, and lymphatic vessel dysplasia.	one of the following : intellectual disability, cryptorchidism, and lymphatic vessel dysplasia.
-------------------	---	---

Table – 1 : Diagnostic criteria for Noonan syndrome.(1,8-10)

Definitive NS – 1. One major or two minor findings accompanying typical facial findings.
2. Two major or three minor findings accompanying suspicious facial findings. (12,14-17)

Above 95% of the cases with NS commonly have ocular abnormalities.(13)

Key ocular findings in NS are listed below. As noted, visual impairment may be permanent.

Refractive: Refractive errors occur in most patients.¹ Examples include myopia, high myopia, hyperopia, high hyperopia, and astigmatism.

External: Ptosis, hypertelorism , down slanting palpebral fissures with high-arched eyebrows, epicanthal folds.

Anterior Segment: keratoconus, prominent corneal nerves, vivid blue or blue-green irises, posterior embryotoxon, cataract.

Neuro-ophthalmologic: Strabismus, nystagmus, amblyopia, binocular optic nerve head abnormalities including hypoplasia, excavation, coloboma. (4,7,18)

Lee et al evaluated the frequency of ophthalmic findings in 58 patients and found hypertelorism (74%) , antimangaloid eyelids (38%) , epicanthal folds (39%) , ptosis (48%) , strabismus (48%) , amblyopia (33%) , nystagmus (9%) , marked corneal nerves (46%) , anterior stromal dystrophy (4%) , cataracts (8%) , pan uveitis (2%) and myelinated nerve fibres (20%). The present case of 10 – year old male patient had short stature , hypertelorism , low and back displaced ears , inverted triangular head shape , thin jaw , pectus excavatum , small PDA on 2D – ECHO , mild developmental delay.(2)

In addition , the patient had right eye congenital nasolacrimal duct obstruction , which was not reported in previous studies or case reports for which the patient underwent external DCR with intubation under general anaesthesia.

IV. Conclusion

Our case report aims to draw attention on eye findings in patients with NS which is a rare genetic disorder.

Congenital nasolacrimal duct obstruction is a new eye finding in a patient with NS.

Due to the complex and highly variable presentation , NS should be managed in a multidisciplinary manner. In terms of ocular prognosis , it appears that the severity of visual findings varies with an individuals genetic variant. Therefore further studies are required to establish ocular prognosis.

References

- [1]. Taha AYYILDIZ . Noonan syndrome Eye signs : A case report . Medical journal of Islamic world Academy of sciences.2017 ; 25(2) : 57-60.
- [2]. Lee NB, Kelly L, Sharland M. Ocular manifestations of Noonan syndrome. Eye. 1992;6:328-34.
- [3]. Noonan syndrome – clinical characteristics , genetics , treatment . Hereditary ocular disease. The university of Arizona – 2019.
- [4]. Andrew Go Lee , Jared Raabe , Nita Bhat , Shruthi Harish Bindiganavile , Robert Thompson , Christina Tise , sonali singh. Noonan Syndrome. AAO April 20 , 2021.
- [5]. Dorothee C Van Trier , Johannes R.M Crysberg. Ocular manifestations of Noonan syndrome : A prospective clinical and Genetic study of 25 patients. J ophtha . June 2016.
- [6]. Dorothy J Reynolds , Steven E Rubin , Joyce Fox , Sylvia Kods. Ocular manifestations of Noonan syndrome in the pediatric patient. J . Jaapos.2003.12.011.
- [7]. Noonan syndrome .Mayo Clinic; Mayo Foundation for Medical Education and Research (MFMER). NOV 30 , 2016.
- [8]. Dorothee C. Van Trier , Ineke Van der Burgt , Jos.M.Draaisma. Ocular findings in Noonan Syndrome : A Retrospective Cohort Study of 105 Patients. Eur J. Pediatr.2018;177(8):1293-1298.
- [9]. Randolph JC, Sokol JA, Lee HB, Nunery WR. Orbital manifestation of Noonan Syndrome. Ophthal Plast Reconstr Surg. 2011;27:160-3.
- [10]. Sharland M, Burch M, Patton MA. A clinical study of Noonan syndrome. Arch Dis Child. 1992;67:178-83
- [11]. Allanson JE. Noonan syndrome. J Med Genet. 1987;24:9-13.
- [12]. Noonan JA, Ehmke DA. Associated non-cardiac malformations in children with Congenital heart disease. J Paed. 1963;63:468- 70.
- [13]. Romano AA, Allanson JE, Dahlgren J, Gelb BD, Hall B, Pierpont ME. Noonan Syndrome: Clinical features,Diagnosis, and Management Guidelines. Pediatrics. 2010;126:746-59.
- [14]. Lemire EG. Noonan syndrome or new autosomal dominant condition with coarctation of the aorta, hypertrophic cardiomyopathy, and minor anomalies. Am J Med Genet. 2002;113:286-290.
- [15]. Lee A , Sakhalkar MV.Ocular manifestations of Noonan syndrome in twin siblings : A case report of keratoconus with acute corneal hydrops. Indian J Ophthalmol.2014;62:1171-1173.
- [16]. Vander Burgt I . Noonan syndrome. Orphonet J Rare Dis. 2007;2:4.
- [17]. Ram SP , Krishna TN.cardiopathy and ocular abnormalities in Noonan syndrome. Singapore Med J.1994 Aug;35(4): 397-399.
- [18]. schwatz DE.Noonan syndrome associated with ocular abnormalities.AmJ ophthalmol 1972 Jun;73(6):955-960.
- [19]. Tartaglia M,kalidas, shaw A et al.PTPN11 mutations in Noonan syndrome: molecular spectrum ,genotype –phenotype correlation and phenotypic heterogeneity.AmJ Hum Genet 2002 jun;70(6):1555-1563.