

Pleomorphic Lacrimal Gland Adenoma ..Recurrent Nature: A Case Report

Rohit Khatri¹, Prithviraj², Rakesh Porwal³,

¹(Department of Eye, J.L.N. Medical college and Hospital, Ajmer, Rajasthan, India)

^{2,3}(Department of Eye, J.L.N. Medical college and Hospital, Ajmer, Rajasthan)^{2,3}

Abstract:

Pleomorphic adenoma is the most common epithelial tumour of the lacrimal gland in adults¹. It is managed by surgical excision. Incomplete removal can lead to recurrence or malignant transformation. High index of suspicion is necessary for prompt diagnosis in younger after surgically removal. We describe a case of lacrimal gland pleomorphic adenoma (LGPA) in a 28-year male which recurrent in nature and emphasise the importance of CT and MRI scan in the diagnosis of extension of recurrence LGPA in young male.

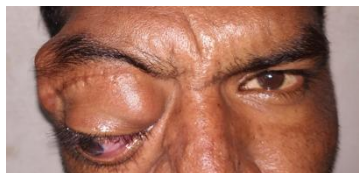Key Word: Lacrimal gland, Pleomorphic adenoma, Recurrent, Young male

Date of Submission: 02-04-2022

Date of Acceptance: 15-04-2022

I. Introduction

A 28 yr old male presented with protrusion of right eye with growing mass in superotemporal orbital region since 3 yr and superonasal orbital region since 1 & 1/2 yr which is gradual in nature, slow continuous progressive, painless, unilateral with limitation of eye movement and diminished visual acuity (Figure 1). He also complain redness and pain in same eye and difficulty to close the eye.



(Figure 1: Protrusion of right eye with growing mass)

II. PAST HISTORY

There was a history of same constitutional symptoms firstly in 2010 and the lesion was surgically excised and on biopsy diagnosed as a pleomorphic adenoma of lacrimal gland. Again he complains swelling in same region in 2013 and surgically removed again and diagnosed with pleomorphic adenoma of lacrimal gland with no malignant transformation. So He was operated two times for this tumour in 2010 and 2013.

III. GENERAL EXAMINATION

He is well nourished, average built, well oriented to place, time, and person. Systemic examination is within normal limit and not associated with any lymphadenopathy in preauricular and submandibular lymph nodes area.

IV. OCULAR EXAMINATION

INSPECTION:

Eye ball show displacement of globe with proptosis (inferolateral globe displacement), nonaxial in direction, down and out, unilateral with no peri orbital inflammation, lagophthalmos with surgical scar mark on upper lid medial to lateral side showing previous excisional surgery.

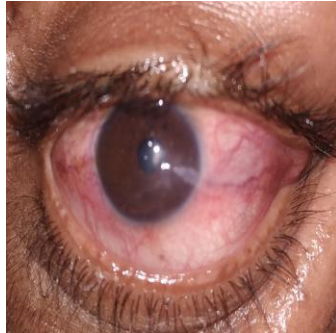
PALPATION: Mass show firm consistency in retrobulbar, no orbital thrill, lobular, non tender, non reducible with no supraorbital anesthesia.

AUSCULTATION: No bruit found.

TRANSILLUMINATION: Dark shadow effect.

Examination revealed a visual acuity of finger count 2 meter in concern eye with diplopia and 6/6 on the Snellen's chart in left eye. Anterior segment examination show conjunctival congestion and chemosis. Cornea show inferior punctate epithelial defect with infiltration nasally with decreased corneal sensation (figure 2). The proptosis was measured using the Hertel exophthalmometer showed readings of 25 mm for the left eye and 19 mm for the right eye. On Fundus examination, media was clear, mild temporal disc pallor and choroidal folds with ERM.

The ocular movement of the right eye was restricted in upward and temporal gaze. Intraocular pressure and visual fields were within normal limits on examination.



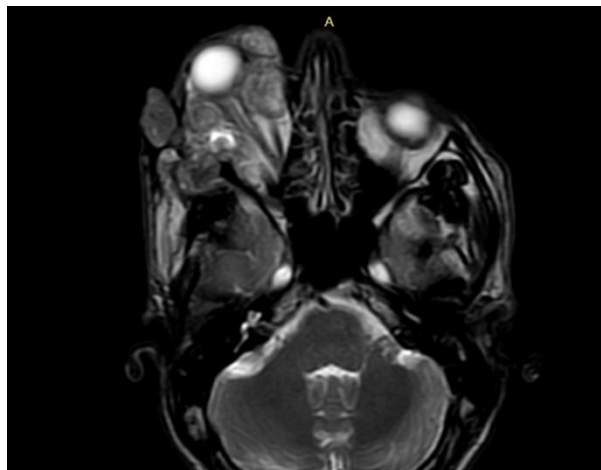
(Figure 2: right eye showing proptosis, conjunctival congestion, chemosis)

V. INVESTIGATION

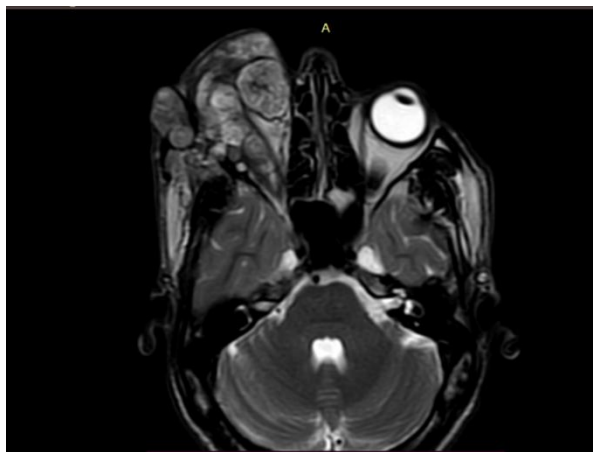
A CT scan show Multiloculated hypodense lesion with cystic and slight hyperattenuating content seen in right orbit and periorbital region causing proptosis. The lesion show subtle <10 HU enhancement. The lesion involves the intraconal, extraconal fat, periorbital extension with involvement of superior rectus, lateral rectus and superior oblique orbital muscles. Optic nerve is stretched but well preserved. Lacrimal gland is not separately identified. The right orbital roof and lateral wall remodeling seen with scalloping, thinning and focal dehiscence in the roof and focal defect seen in lateral wall.

A MRI of Right eye orbit show numerous enhancing round to oval solid lesions are seen in right orbit involving extraconal and intraconal compartments, encasing and compressing optic nerve, eye ball and extra-ocular muscles. Posteriorly lesions are extending up to orbital apex. The lesions are also seen in pre-orbital region and fronto-temporal galeal soft tissues involving temporalis muscle. Mild right proptosis is seen with eye ball displaced infero-laterally. Largest lesion measures approx. 29×24 mm at supero-medial aspect.

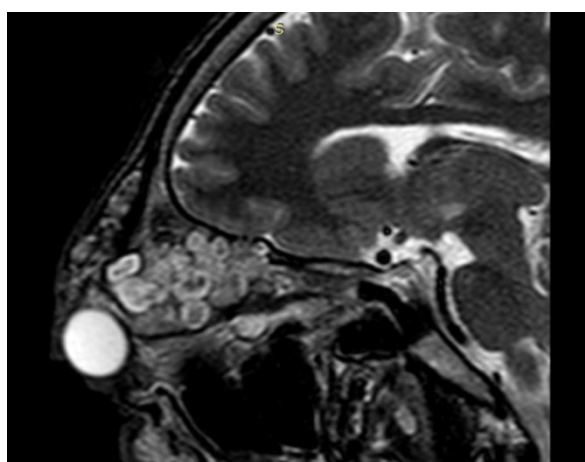
Figure 3 to 7 show extension of the adenomas in different compartment of eye.



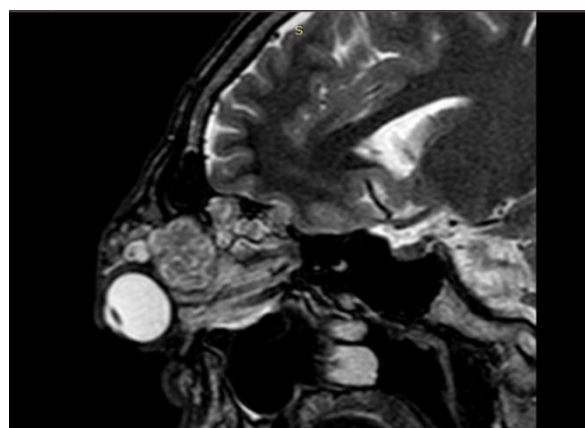
(Figure 3)



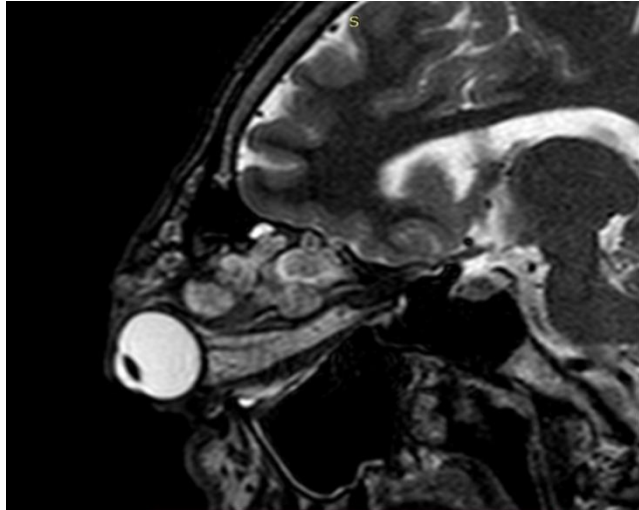
(Figure 4)



(Figure 5)



(Figure 6)



(Figure 7)

VI. TREATMENT ADVISED

Complete surgical excision with infiltration tissue resection [Complete exenteration of infiltration tissue] with excisional biopsy through anterior and lateral orbitotomy approach.

VII. DISCUSSION

Lacrimal gland pleomorphic adenoma (LGPA) is a slow-growing, benign, epithelial tumour in the orbital region¹. It is a well-circumscribed and pseudo-encapsulated superotemporal mass in a orbital region. It can be differentiated from a malignant mass by the absence of associated pain and bony erosion of orbit. LGPA is commonly seen in young and middle age group in 4th and 5th decade. In 90% cases, Orbital lobe of the lacrimal gland is involved². LGPA can rarely arise from the palpebral lobe and an ectopic lacrimal tissue in orbital region³. LGPA show PLAG1 transcription factor gene and HMGA-2 growth regulation and cell proliferation genetic alternation in cases.

A CT and MRI scan tells a initial localisation and characterisation of the tumour. It can help in differentiating benign from malignant tumour, with respect to bony erosion and moulding and associated calcification in their findings.

On histopathology, epithelial and connective tissue elements show pleomorphism nature. This epithelial tumour is derived from the ducts of the glands and shows a arrangement of double layer of cuboidal cells . The innermost layer of cells may undergo metaplasialike a myxomatous, fibroblastic, cartilagenous or even osseous tissue with areas of hyalinization. A pseudo capsule is formed, consisting of condensation of connective tissue around it and may be adherent to the periosteum attached to orbital bone. This may be invaded by the tumour and if the pseudocapsule is not incompletely removed on excision and excisional biopsy, recurrence usually follows. Recurrence also occurs in fine needle biopsy, needle track in biopsy, incomplete removal of tumours, incomplete removal of capsule and capsular breach during surgery.

The chances of recurrence 5 years postoperatively are 3% if completely excised with an intact capsule and 30% if incompletely removed⁴.

LGPA can serve as a loci for future development of malignant epithelial tumour. Around 10% of lacrimal gland tumours become malignant within 20 years of diagnosis and it increases to up to 20% after 30 years⁵.

Excisional biopsy is the definitive treatment of LGPA. Anterior orbitotomy is the preferred choice of surgery for access to the anterior extra-conal orbital space (palpebral lobe mass). Lateral orbitotomy is an approach for deeper orbital mass that could not be accessed through an anterior incision properly or require larger exposure (orbital lobe lesions). Recurrence may occur if the tumour and its capsule is incompletely excised or if an incisional biopsy was performed preoperatively.

References

- [1]. Shields CL, Shields JA, Eagle RC, et al. Clinicopathologic review of 142 cases of lacrimal gland lesions. *Ophthalmology* 1989;2013:431–5
- [2]. Font RLGJ. Epithelial tumors of the lacrimal gland: an analysis of 265 cases. In: Jakobiec F, ed. *Ocular and adnexal tumors*. Birmingham, AL: Aesculapius, 1978:787–805
- [3]. Vangveeravong S, Katz SE, Rootman J, et al. Tumors arising in the palpebral lobe of the lacrimal gland. *Ophthalmology* 1996;2013:1606–12
- [4]. Gupta S, Garg S, Singh S, et al. Pleomorphic adenoma of lacrimal gland in a 5-year-old child: diagnosed on aspiration cytology. *Diagn Cytopathol*: 18 Nov 2011. doi: 10.1002/dc.21854
- [5]. Font RLGJ. Epithelial tumors of the lacrimal gland: an analysis of 265 cases. In: Jakobiec F, ed. *Ocular and adnexal tumors*. Birmingham, AL: Aesculapius, 1978:787–805

Rohit Khatri, et. al. “Pleomorphic Lacrimal Gland Adenoma ..Recurrent Nature: A Case Report.” *IOSR Journal of Dental and Medical Sciences (IOSR-JDMS)*, 21(04), 2022, pp. 29-33.