

Unilateral Internal Jugular Vein Agenesis: an incidental finding in a patient of Ludwig's Angina

Dr George B Mangalath

Dr Bhavini Gupta, Dr Deepanshu Gupta, Dr Sarfaraz Shaikh

A 201 Navdurgachs , sector 19 A nerul , NaviMumbai pin 400706

Abstract:

Background: Internal jugular vein (IJV) agenesis represents a rare vascular malformation resulting from developmental anomaly, often diagnosed incidentally in patients presenting for other pathologies. Only few cases have been reported in literature (less than 10). The absence of unilateral IJV is associated with accessory venous drainage pathways and hypertrophy of the contralateral IJV. No surgical management is required.

Case presentation: In this study, we present a case of a 75-year-old lady who presented with severe pain and tenderness in the neck, with sudden swelling. On examination, the patient's tongue was found to be swollen and uplifted. There were additional complaints of mild fever, vomiting and nausea. A provisional diagnosis of Ludwig's Angina was made, based on the clinical findings. Emergency ultrasound was performed that showed features of thyroiditis, cervical lymphadenopathy and absent left IJV. Plain CT scan of the neck was acquired.

Conclusion: Unilateral IJV agenesis is an extremely rare vascular malformation that is diagnosed incidentally, and is usually asymptomatic. However, knowledge of its presence is important for operating surgeons.

Keywords: Case report, unilateral IJV agenesis, collateral venous drainage, enlarged contralateral IJV, vascular malformation

Date of Submission: 02-04-2022

Date of Acceptance: 15-04-2022

I. Background:

IJV is a major contributor of the venous drainage from the head and neck region. It originates from the sigmoid sinus in the cranium, exits through the jugular foramen, and is joined by the subclavian vein to continue as the superior vena cava on the right side and drains into the left brachiocephalic vein on the left. Distal to the jugular bulb, it descends in the carotid sheath, in close approximation to the internal carotid artery [1]. IJV develops from the anterior cardinal vein cephalic to the origin of the intersegmental vein that forms the subclavian vein [2].

IJV agenesis represents a rare vascular malformation resulting from a developmental anomaly of the venous drainage pathway. Most cases are asymptomatic and discovered incidentally in patients presenting with other pathologies. It does not require surgical management; however, it is important to diagnose it to avoid complications in surgical procedures.

II. Case Presentation:

A 75-year-old female presented with sudden swelling in the neck, associated with severe pain. Patient was unable to speak and made guttural noises. She had vomiting, nausea, and fever since 24 hours. However, she had no breathing difficulties. The patient was examined and found to have tenderness along the region of swelling, that extended cranially to involve bilateral cheeks. Multiple enlarged lymph nodes could be palpated in the neck. The patient was unable to speak. Based on the clinical examination, and raised TLC counts (20,000 / mm³), a clinical diagnosis of Ludwig's angina was made.

Ultrasound of the neck was performed. There was significant subcutaneous oedema with multiple enlarged non-necrotic and necrotic lymph nodes, largest measuring 2 x 0.8 cm. Cervical lymphadenopathy with subcutaneous oedema were consistent with the diagnosis of Ludwig's angina. Thyroid gland was enlarged, with heterogeneous echotexture, increased vascularity, few calcific foci, and a sub centimetre sized cystic space.

No evidence of any brain pathology noted. Contrast enhanced CT Neck was performed to confirm findings.

On multi-plane reformatted images, findings of the ultrasound were confirmed. The left IJV was absent and could not be visualized in the neck, base of skull, or in the intracranial region. The carotid sheath contained only the internal carotid artery (Figure 1 A, B and C). Contralateral IJV was mildly enlarged in size. The right IJV showed homogeneous density and no evidence of jugular thrombosis noted.

Multiple enlarged, heterogeneous density lymph nodes were noted in bilateral cervical regions (left > right) with subcutaneous oedema, adjacent tissue fat-stranding, and generalized oedema stenosing the trachea and obliterating the pyriform sinuses. (Figure 2).

The visualized part of the carotid arteries showed atherosclerotic changes in the form of wall calcifications (Figure 1A).

No surgical treatment was provided for absent IJV. It was asymptomatic and few collateral vascular channels were noted forming an accessory venous drainage pathway. Antibiotic based regimen was initiated for the treatment of Ludwig's angina.

III. Discussion:

Internal jugular vein (IJV) forms the major drainage venous drainage pathway from the head and neck, back into the superior vena cava on the right and brachiocephalic vein on the left. It is the most commonly used vein for accessing the central venous system, as a part of major surgical procedures, in intensive care units for the monitoring of critically ill patients, and for administration of drugs for fast effect. IJV cannulation has fewer complications as compared to subclavian cannulation [3]. Jugular thrombosis secondary to prolonged cannulation is a known complication.

IJV is also preserved during therapeutic neck dissection, as it forms the major drainage pathway. Though unilateral IJV agenesis is clinically insignificant, bilateral alterations in the IJV can lead to severe intracranial hypertension, raising the intracranial pressure to five times the normal, which may result in fatal cerebral oedema [4-7]. To prevent life-threatening complications, it is crucial to preserve the unilateral IJV present in neck dissections and from thrombosis secondary to cannulations. The diagnosis of IJV agenesis should prompt caution during surgical procedures to prevent inadvertent damage to the non-diseased IJV. The surgeon needs to be aware of this anomaly before ligation of involved veins in bilateral neck dissection, to avoid disruption of alternate pathways of venous drainage i.e. external jugular systems that develop in agenesis of venous systems. As a precautionary measure to prevent life-threatening complications, it has become a protocol to safeguard at least one IJV [3].

Agenesis is also associated with failed cannulation procedures. Venous Doppler is advocated for localization of IJV prior to central venous cannulation.

Venous malformations in the facial or cerebral circulations may coexist in up to 20% patients [8]. The contralateral enlarged IJV may present as a suspicious mass [9]. Possible differential diagnoses include thrombosis of the IJV or altered hemodynamic states.

IV. Conclusion:

Even though unilateral internal jugular vein agenesis may be asymptomatic, knowledge of this anomaly is critical to avoid fatal alterations of the contralateral normal IJV. Medical procedures and protocols should be altered adequately to preserve the non-diseased / present IJV with meticulous care and caution. Since, it is generally asymptomatic, findings may be missed if not looked carefully.

SUMMARY OF THE CASE:

Patient:	75-year-old female
Final diagnosis:	Unilateral Internal jugular vein agenesis in a patient presenting with Ludwig's angina
Symptoms:	Tender and severely painful swelling involving the neck with fever, nausea and vomiting
Intervention:	Antibiotic based treatment for Ludwig's angina
Specialty:	Radiology

LIST OF ABBREVIATIONS:

IJV Internal Jugular Vein
CT Computed Tomography
CECT Contrast enhanced Computed Tomography

CONFLICTS OF INTEREST: The authors declare that there is no conflict of interest regarding the publication of this article.

FUNDING: None

ETHICAL APPROVAL: Imaging findings were obtained with patient consent. Local ethical approval was not required.

CONSENT: Written informed patient consent for publication has been obtained.

References:

- [1]. Mc Minn RMH et al (1999) Head Neck and Spine, Last Anatomy 9th edition 6:438–439
- [2]. Inderbir Singh. (1999) Development of cardiovascular system. Human embryology, 6th Edition 15:247–248
- [3]. Majeed TA, Deshpande RK, Upadhaya S, Deshmukh SA. Agenesis of internal jugular vein a cause for concern. *Indian J Surg Oncol.* 2010;1(4):341-342. doi:10.1007/s13193-010-0040-8
- [4]. Dukes BJ, et al. Traumatic bilateral jugular vein thrombosis. *Neurosurgery.* 1997;41(3):680–683.
- [5]. Longjiang L, et al. Rationale radical neck dissection for oral cancer. *Chin Med J.* 2003;116(8):1123–1126.
- [6]. Kotani J, et al. Bilateral internal jugular vein ligation. *Br J Oral Maxillofac Surg.* 1992;30(3):171–173. doi: 10.1016/0266-4356(92)90151-8.
- [7]. Watkins JC et al (2000) Complications of Head and Neck Surgery StellMaran 6th Edition 6:85
- [8]. Essafti M., Belhadj A., Qamouss Y., Rokhsi R., Aissaoui Y. Agenesis of the left internal jugular vein: an unusual finding during an ultra-sound guided central venous catheterization. *J ClinAnesth.* 2018;44:87–88.
- [9]. Kayiran O., Calli C., Emre A., Soy F.K. Congenital agenesis of the internal jugular vein: an extremely rare anomaly. *Case Rep Surg.* 2015;2015

FIGURE LEGENDS

Figure 1:

Non-enhanced CT axial (A) and coronal (B) images and CECT axial (C) images show the presence of right IJV (green arrows on all images) and the absence of the left IJV (yellow arrows) in the same spot. Late arterial phase contrast (C) image shows the normal of the right IJV, however, no similar enhancing vessel present on the left side.

The right IJV (green arrows) appears mildly prominent. The carotid vessels show wall calcifications.

© Department of Radiology; Dr. D.Y. Patil Hospital

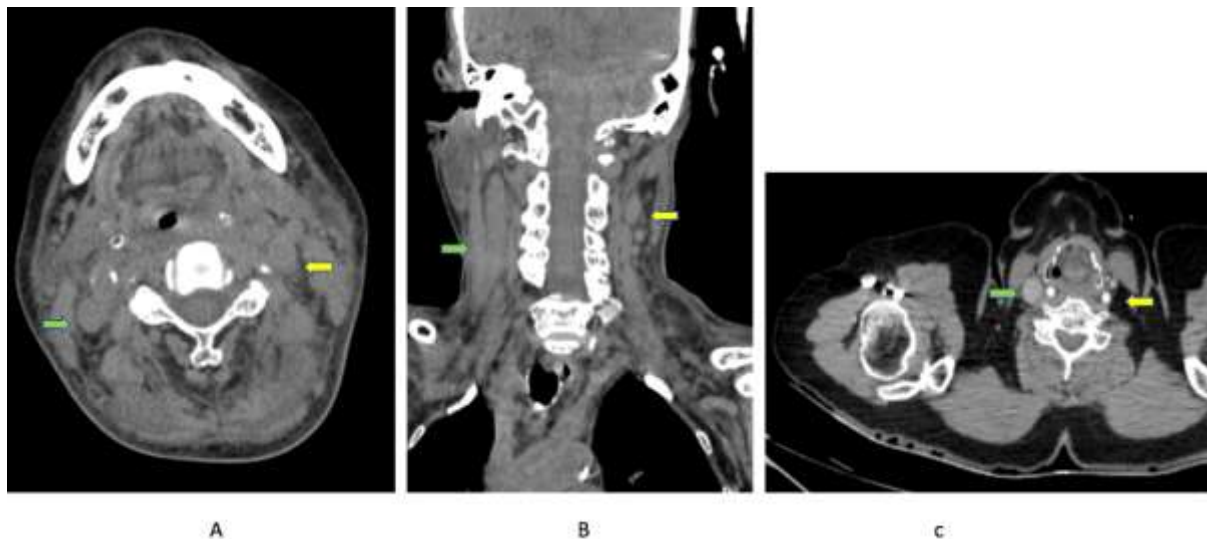
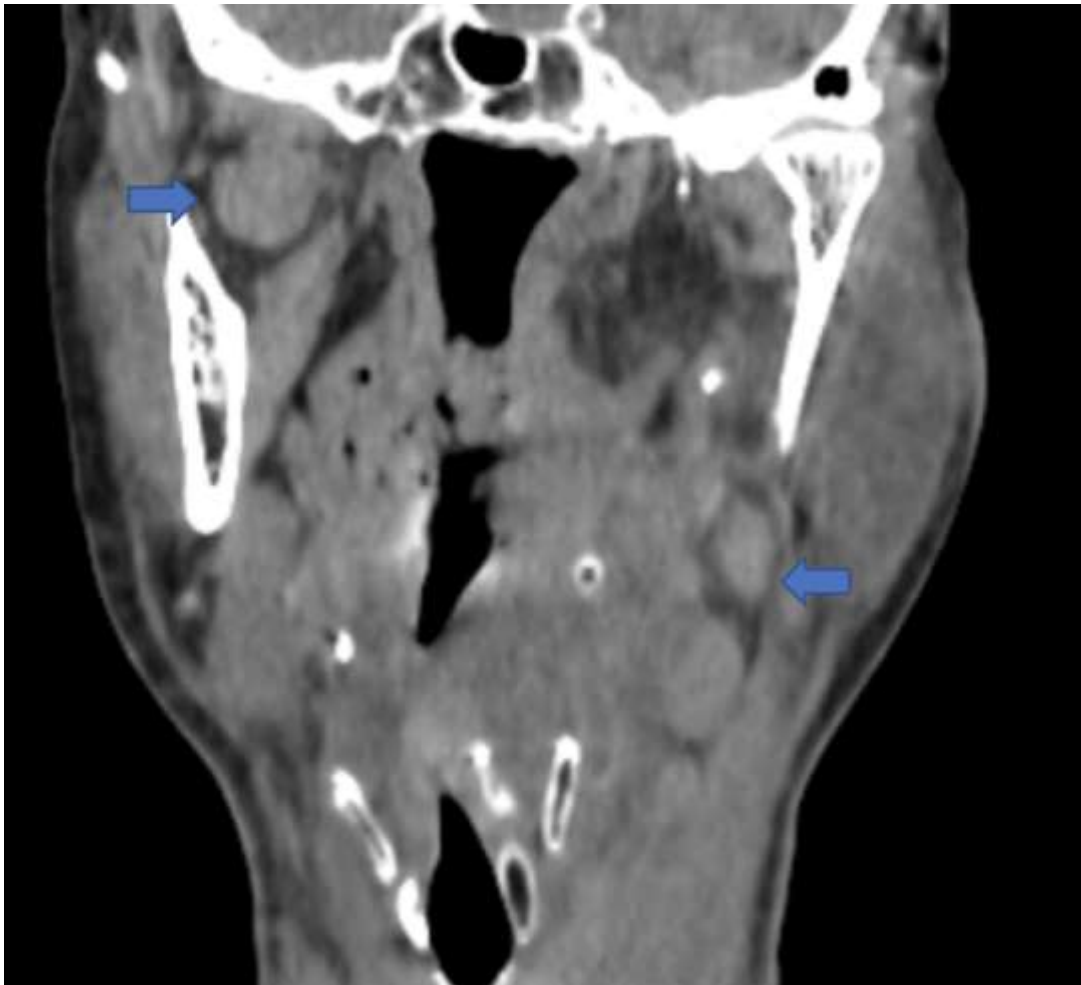


Figure 2:

Heterogeneous density globular to ovoid, well-defined, enlarged lymph nodes noted in bilateral cervical regions (blue arrows).

© Department of Radiology; Dr. D.Y. Patil Hospital



Dr George B Mangalath, et. al. "Unilateral Internal Jugular Vein Agenesis: an incidental finding in a patient of Ludwig's Angina." *IOSR Journal of Dental and Medical Sciences (IOSR-JDMS)*, 21(04), 2022, pp. 50-53.