

Management Of Mandibular Canine With Two Roots And Two Root Canals: A Case Report

Dr.Tanya Bansal¹ , Dr.H.D.Adhikari² , Dr.Kallol Saha³

1.PG Final year ,Department of Conservative Dentistry & Endodontics, Dr.R.Ahmed Dental College and Hospital,Kolkata

2.Ex- Professor and HOD, Department of Conservative Dentistry & Endodontics, Dr.R.Ahmed Dental College and Hospital,Kolkata

3. Professor. and HOD, Department of Conservative Dentistry & Endodontics, Dr.R.Ahmed Dental College and Hospital,Kolkata

Abstract

Mandibular canine with two roots and two root canals is a rare anatomical variation of the tooth that can complicate root canal treatment. Proper diagnosis and treatment planning are essential for the successful management of mandibular canine with two roots and two root canals. The clinician must be aware of the possibility of anatomical variations and use appropriate diagnostic and treatment techniques to ensure successful treatment outcomes. With proper management, mandibular canines with two roots and two root canals can be successfully treated and preserved. This article reports a clinical case of endodontic treatment of a mandibular canine with two roots and two canals.

Keywords: *Mandibular canine, Two canals, Two roots*

Date of Submission: 19-04-2023

Date of Acceptance: 02-05-2023

I. Introduction

A thorough understanding of tooth anatomy and root canal morphology is necessary for successful root canal therapy. The purpose of endodontic treatment is to eliminate the infection in the root canal and prevent it from reinfection. Endodontic procedures may also be negatively impacted by the tooth's morphologic characteristics. The prevalence of two or three root canals has been estimated to range between 1% and 43% in mandibular anterior teeth¹. The majority of the time, mandibular canines are known to have one root and one root canal. Two roots and even more than two canals are extremely uncommon, occurring between 1 and 5 percent of the time².

The mandibular canine is a tooth with strategic value in the dental arch. Its proprioceptive qualities, which control or guide masticatory function, combined with its function in occlusal guidance during eccentric movements and posterior disocclusion, make its long, stable root useful for prosthetic support³. Even though there may be various morphologic difficulties, a lot of effort is put into its preservation. The mandibular canine typically has a single root and a single root canal⁴. However, there has been a discernible increase in the number of clinical studies, in vitro/ex vivo studies, and case reports that have revealed morphological variations since the start of the 21st century as a result of the introduction of new technologies related to intraoperative vision magnification and inventive radiological imaging systems. One such example is the presence of two roots and two root canals in the mandibular canine.

Finding variations like this is unpredictable, and the clinician must assume that any mandibular canine can morphologize with variation in order to prevent any unanticipated treatment issues related to unusual root canal anatomy. In order to perform a case report on this anatomical variation, the goal of this article is to present a case on management of a mandibular canine with two roots and two root canals.

II. Case Report

A 50-year-old male patient reported to the Department of conservative dentistry and Endodontics with pain in the left lower front tooth region for the past 6 months. Medical history was non contributory. On clinical examination, there was severe attrition with dentinal exposure and microcracks in enamel in relation to tooth

number 33 (Figure 1A). Oral mucosa was normal with no presence of any sinus tracts. On pulp sensibility testing (electric pulp test and cold test), tooth number 33 showed an exaggerated response. Diagnostic radiograph revealed severe attrition involving pulp with two roots and two root canals (Figure 1B). Cone-beam computed tomography (CBCT) was performed to confirm the presence of two separate roots and root canals (Fig. 1C).

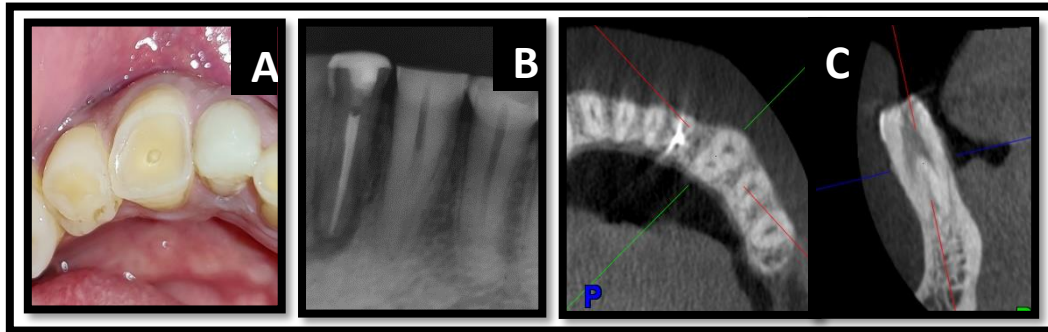


Fig.1 A.Preop clinical View B & C. Preop IOPAR & CBCT showing two roots and two root canals

Based on history, clinical and radiological examination, a diagnosis of symptomatic irreversible pulpitis was made with respect to tooth # 33. Root canal treatment was advised and informed consent was taken from the patient. Local anesthesia (2% lidocaine hydrochloride with 1:80,000 epinephrine) (Lignospan Special, Septodont, Raigad, India) was administered, and a rubber dam(GDC Dental Dam Kit) was placed. All procedures were performed under the dental operating microscope (OPMI PROergo, Carl Zeiss, Oberkochen, Germany) for better magnification and illumination. The access cavity was prepared, and DG16 endodontic explorer was used to determine the bifurcation level of the root in mandibular canine. After gaining straight-line access, the root canal was irrigated with 5.25% sodium hypochlorite (Prime Dental, Maharashtra,India) and #15 size K-files (Dentsply Maillefer, Ballaigues, Switzerland) were used to determine working length using electronic apex locator (Dentsply Propex Pixi, Switzerland) which was then reconfirmed using radiographs (Fig. 2A). Biomechanical preparation was completed using rotary nickel-titanium files (Hyflex CM,Coltene, Switzerland) till apical file size #30/04(Fig. 2B). Entire instrumentation was supplemented with copious irrigation using 5.25% sodium hypochlorite (Prime Dental , Maharashtra, India) with a negative pressure irrigation system (Endovac, Sybron Endo, New York, U.S.A). Master cone IOPAR was taken(Fig.2C) Before obturation, the canal was irrigated with 17% EDTA (Anabond Desmear Stedman Pharma Research (P) Ltd.) for 1 minute and finally flushed with 5 mL normal saline. After the canals were dried using sterile paper points, obturation was done using AH Plus sealer (Dentsply DeTreY GmbH, Konstanz,Germany) and gutta percha points using the lateral cold compaction technique(Figure 2D). The access cavity was sealed with composite resin restoration (Tetric-E-Ceram Bulk Fill;Ivoclar-Vivadent,Schaan,Liechstein) and then radiograph was taken(Fig.2E).

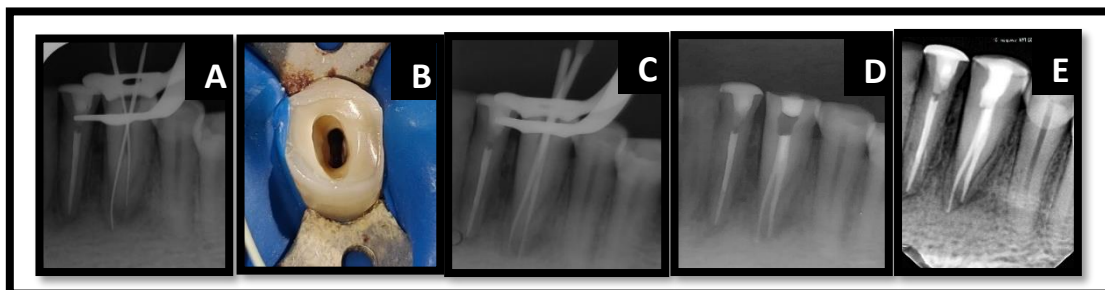


Fig.2 A. Working Length B. Cleaned and Shaped Canals C. Master cone D. Postobturation E.Postop

III. Discussion

Mandibular canines typically have a single root in terms of morphology³. Every mandibular canine has a different general anatomy with a single root and canal. Two roots and two canals, one or two roots with three canals, and other unusual findings have been reported^{4,5,6-9}. For proper management and a better prognosis, it is essential to fully comprehend the mandibular canine's complex anatomy^{8,10}. Different root canal anatomy must be taken into consideration by the dentist. Endodontic treatment becomes technically challenging when unexpected complexity is discovered in the root canal, so care should be taken from the start of the procedure until it is finished⁷.

In this case report, a mandibular canine with two roots and two canals was successfully managed. Regarding the roots and canal morphology of mandibular canine, various authors have expressed their opinions¹⁻⁵ where 18% of canines have two canals, according to research by Vertucci¹¹. On 13 out of the 100 teeth examined, Green D found two canals in a single-rooted canine¹².

Arcangelo et al presented two cases of two roots and two canals¹³. According to Laurichesse et al, only 1% of mandibular canines had two roots and two canals while 2% of them had one root and two canals⁹.

Pecora and coworkers found that 1.2% of the 830 teeth studied had two canals and two orifices in a single root and 1.7% had two distinct roots⁶. The authors Bakianian et al reported that 12 percent of cases had two canals¹⁴.

Understanding the internal anatomy of the tooth requires an understanding of intraoral periapical radiographs. Radiographs taken at various horizontal angles aid in better canal visualization. A single radiograph taken with a vertical and horizontal projection frequently does not show all the roots and canals. The tube shift technique, also known as SLOB (same Lingual Opposite Buccal) or Clark's Rule, can be used to gain access and confirm the number of roots and canals¹⁵. We used two X-ray projections in this instance, one at a mesial angle of 10°–15° and the other at a depth of 20°. There is a possibility of superimposition and image distortion even when using various techniques to take an intraoral periapical radiograph¹⁵. When taking a radiograph, changing the angle may cause the images to be foreshortened or elongated, therefore, Cone beam computed tomography (CBCT) was taken in these situations to precisely count the roots, curvatures, and bifurcations in both sagittal and axial planes, thereby overcoming these drawbacks^{10,16}. Care was taken when preparing the access cavity because of the placement of the canals was different from normal variants and the bur's proper angulation could result in iatrogenic accidents.

According to the data from various studies, the presence of root canal variations in mandibular canine is not a common finding, but the clinician should be aware of these anatomical variations before endodontically treating any tooth. This instance emphasizes the value of thorough root and canal exploration when treating mandibular canines endodontically. For precise detection of additional canals, additional diagnostic methods like cone beam computed tomography (CBCT) and tube shift techniques can be used when in doubt. It is always crucial for effective endodontic case management to have a thorough understanding of the anatomical variations of root canal morphology.

IV. Conclusion

These anatomical variations are linked to technical challenges during endodontic treatment, even though the literature suggests that mandibular canines with two roots and two root canals are uncommon. Because of this, it is crucial to carefully examine the preoperative radiograph for any indications of anatomical variations. A radiolucent groove in the lateral part of the root and a sudden loss in the continuity of the root canal lumen are two signs that more than one canal is present. A timely diagnosis and thorough investigation of the internal anatomy of a mandibular canine with two roots and two root canals enables the planning of a customized treatment regimen that is aimed at preventing excessive root weakening or perforation. This protocol is tailored to the peculiar morphology of particular tooth of the patient.

References

- [1]. Alapati S, Zaatari EI, Shyama M, Al-Zuhair N. Maxillary canine with two root canals. *Medical Principles and Practice*. 2006;15(1):74-6.
- [2]. Wang L, Zhang R, Peng B. Clinical Features and treatment of mandibular canines with two root canals: Two case reports. *Chinese Journal of Dental Research*. 2009 Jun 1;12(1):61.
- [3]. Abduo J, Tennant M, Mcgeachie J. Lateral occlusion schemes in natural and minimally restored permanent dentition: a systematic review. *Journal of oral rehabilitation*. 2013 Oct;40(10):788-802.
- [4]. Versiani MA, Pécora JD, Sousa-Neto MD. Microcomputed tomography analysis of the root canal morphology of single-rooted mandibular canines. *International Endodontic Journal*. 2013 Sep;46(9):800-7.
- [5]. Kulkarni NR, Kamat SB, Hugar SI, Nanjannawar GS. Mandibular canine with two roots and two root canals—a rare case. *Journal of Clinical and Diagnostic Research: JCDR*. 2016 Sep;10(9):ZJ07.
- [6]. Pécora JD, Neto S, Saquy PC. Internal anatomy, direction and number of roots and size of human mandibular canines. *Brazilian dental journal*. 1993 Jan 1;4(1):53-7.
- [7]. Kaffe I, KAUFMAN A, LITTNER MM, LAZARSON A. Radiographic study of the root canal system of mandibular anterior teeth. *International Endodontic Journal*. 1985 Oct;18(4):253-9.

- [8]. Shrivastava N, Nikhil V, Arora V, Bhandari M. Endodontic management of mandibular canine with two canals. Journal of the International Clinical Dental Research Organization. 2013 Jan 1;5(1):24.
- [9]. Laurichesse JM, Maestroni F, Breillat J. Endodontie clinique. Éditions CdP; 1986.
- [10]. Pineda F, Kuttler Y. Mesiodistal and buccolingual roentgenographic investigation of 7,275 root canals. Oral Surgery, Oral Medicine, Oral Pathology. 1972 Jan 1;33(1):101-10.
- [11]. Vertucci FJ. Root canal anatomy of the mandibular anterior teeth. The Journal of the American Dental Association. 1974 Aug 1;89(2):369-71.
- [12]. Green D. Brooklyn NY. Double canals in single roots Oral Surg. 1973;35:689-96.
- [13]. D'arcangelo C, Varvara G, De Fazio P. Root canal treatment in mandibular canines with two roots: a report of two cases. International Endodontic Journal. 2001 Jun;34(4):331-4.
- [14]. Vaziri PB, Kasraee S, Abdolsamadi HR, Abdollahzadeh S, Esmaeili F, Nazari S, Vahedi M. Root canal configuration of one-rooted mandibular canine in an Iranian population: An in vitro study. Journal of dental research, dental clinics, dental prospects. 2008;2(1):28.
- [15]. White SC, Pharoah MJ. Intraoral radiographic examinations. White SC, Pharoah MJ. Oral radiology; principles and interpretation. 5th ed. St. Louis: Mosby. 2004:121
- [16]. Soleymani A, Namaryan N, Moudi E, Gholinia A. Root canal morphology of mandibular canine in an Iranian population: a CBCT assessment. Iranian endodontic journal. 2017;12(1):78.