

# Comparative Study Of Functional Outcome Of Short Proximal Femoral Nail And Long Proximal Femoral Nail For The Treatment Of Peritrochanteric Fractures Of The Femur In Patients Over 65 Years Old

Dr. Ajay Sharma<sup>1</sup>

Post-Graduate Trainee, Department of Orthopaedics, Pacific Institute of Medical Sciences, Udaipur, India

Dr. Aabid Husain Ansari<sup>2</sup>

Assistant Professor, Department of Orthopaedics, Pacific Institute of Medical Sciences, Udaipur, India

Dr. Asif Husain Ansari<sup>3</sup>

Junior Resident, Department of Orthopaedics, Government Medical College, Bhilwara, India

Dr. Laxmi Narayan Meena<sup>4</sup>

Associate Professor, Department of Orthopaedics, Pacific Institute of Medical Sciences, Udaipur, India

## Abstract

**Background:** A comparative evaluation of the functional outcome of patients with peri-trochanteric fractures treated with short versus long proximal femoral nail.

**Materials and Methods:** A prospective comparative study was conducted of patients with peri-trochanteric fractures treated between August 2020 and March 2022. In all 110 patients were enrolled in the study, of which 58 were treated with short PFN and 52 were treated with long PFN. During follow-up, comparative analyses of demographic, and peri-operative data, functional outcome and complications were carried out.

**Results:** There was no significant difference noted in the two groups with regards of average time of radiological union, re-fracture, major reoperation, and Harris hip score. The surgical duration and intra-operative blood loss was significantly higher in the long PFN group as compared to the short PFN group.

**Conclusion:** A relatively quicker surgical time and less bleeding make short PFN a better implant choice in the treatment of peri-trochanteric fractures especially AO 31A1 and A2, while long PFN is better for intertrochanteric fractures with sub-trochanteric extension and severe osteoporosis.

**Keywords:** Peri-trochanteric fractures, Proximal Femoral Nail, Short, Long, Intramedullary fixation, Harris Hip Score.

Date of Submission: 03-09-2023

Date of Acceptance: 13-09-2023

## I. Introduction

Peri-trochanteric fractures of femur account for nearly half the hip fractures in elderly patients. Osteoporosis in old age is significant co-morbidity which is associated with increased incidence of hip fractures in this age group.<sup>1,2</sup>

Both an extramedullary and an intramedullary implants are commonly used to treat peri-trochanteric fractures. An intramedullary implants, Proximal femoral nail (PFN) have an advantage over an extramedullary implants. PFN is placed more closer to the mechanical axis of the limb, which decreases the lever arm and bending moment on the implant. PFN is associated with less intraoperative bleeding and less surgery duration which allow the patient to early weight bearing with less resultant shortening on long term follow up.<sup>3</sup>

We conducted this study to do a comparative evaluation of the surgical outcome of patients with peri-trochanteric fractures treated using either a short or a long PFN.

## II. Materials and Methods

We conducted a prospective comparative study on patients with peri-trochanteric fractures (intertrochanteric fractures with maximum of 3 cm extension below lesser trochanter), operated with closed/open reduction & internal fixation with either short PFN (240 mm) or long PFN (340 mm to 400 mm). Total of 110 patients have been included out of which 58 belonged to group 1 and were operated with short PFN and rest 52 were group 2 operated with long PFN. The study was carried out in the department of orthopaedics at our institute between March 2020 To March 2022 after seeking approval from Institutional Ethics Committee. Polytrauma

patients, patients with compound fracture or pathological fractures or concomitant shaft femur fractures, patients with disorders of bone metabolism other than osteoporosis or any other co-morbidity that makes them unfit for surgery, revision surgeries and age less than 65 years were excluded from the study. The surgery was performed as soon as the medical conditions allowed and fit for anaesthesia. Majority of the patients were operated under spinal anaesthesia by Consultant Orthopaedic surgeon. Closed reduction was attempted in all patients, and when the closed reduction failed Open reduction was done to reduce the fracture. Reaming was performed in all patients. In short PFN (240 mm) cases, distal locking was performed using the manufacturer custom jig, whereas in long PFN (340 mm to 400 mm) cases, distal locking was performed by a free hand technique. Antibiotics was administered 30 minutes prior to incision and two doses were repeated post-surgery. Postoperative X-ray hip were taken to ascertain the fracture reduction and position of the implant. Physiotherapy was started from day 1 and all patients were allowed to be weight-bearing as tolerated with unrestricted hip motion. Most of the patients were discharged on 4th or 5th post op day. Stitch were removed 2 weeks after surgery. All patients were followed-up at 1, 3, 6 and 12 months after the surgery. At each follow-up, X-ray hip were taken to check the status of fracture union.

Statistical analysis was performed with the SPSS version 19.0 (SPSS Inc./IBM, Chicago, IL). Student's t test was used to compare groups with continuous variables and Pearson's chi-square test was used for categorical variables. A p-value of <0.05 was considered to be statistically significant.

### III. Result

A total of 110 patients underwent surgery for peri-trochanteric fracture during the period of study. Fifty eight patients were belonged to group 1 and were operated with short PFN and rest 52 were belonged to group 2 and were operated with long PFN. The patient characteristics of both groups was not significantly different (Table 1).

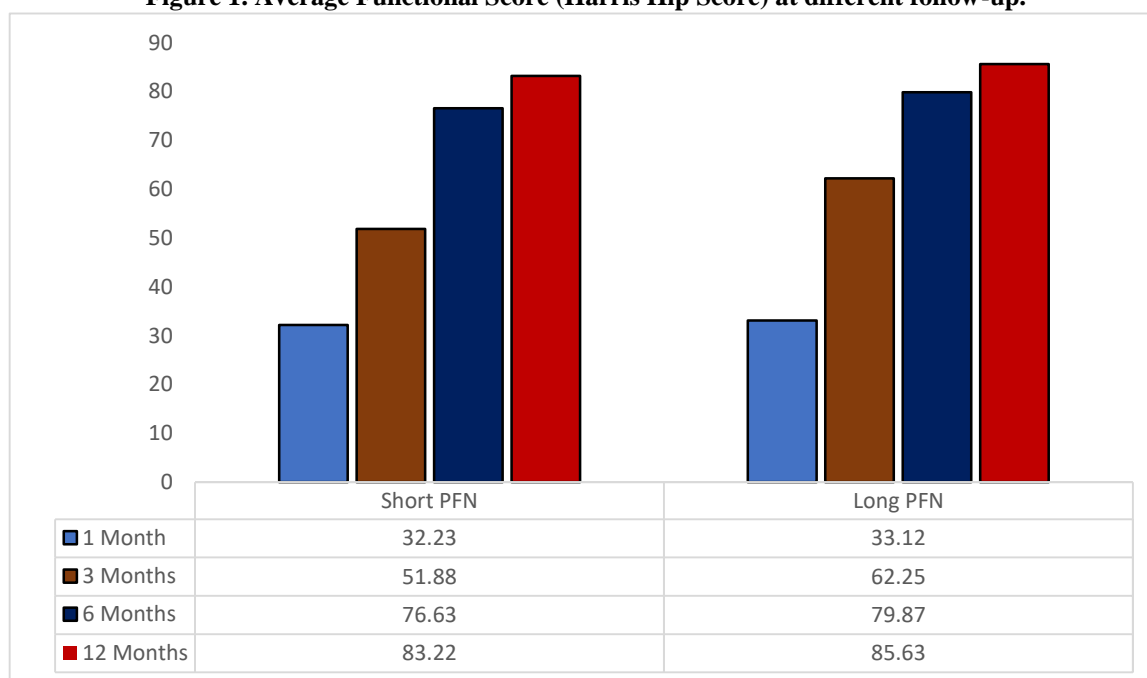
**Table 1: Patient statistics.**

Variables	Short PFN	Long PFN
Number of patients	58	52
Gender (Male/Female)	18/40	14/38
Mean age (years)	67.2	68.5
AO-31-A1/A2/A3	15/36/7	13/30/9
Anaesthesia (General/Spinal)	4/54	2/50
Fracture reduction (Closed/Open)	56/2	48/4
Average blood loss (ml)	100	150
Average operating time (min)	45.6	62.5
Union (weeks)	14.2	15.1
Harris hip score	83.22	85.63
Thigh pain (%)	10.34	3.85
Reoperations (n)	1	1

The mean age in group 1 was 67.2 years (range: 66-86 years) and 68.5 years (range: 68-89 years) in group 2. AO 31-A2 fractures were most common type of fractures in both groups. Most of the patients were operated under spinal anaesthesia. There was no significant difference in the type of anaesthesia administered to the patients in either groups (p = 0.445). Two patients in short PFN group and 4 patients in long PFN group required open reduction, whereas closed reduction were performed in rest of the patients. The average intraoperative blood loss was greater in long PFN group (150ml vs. 100ml, p = 0.04). The mean surgery duration was also more in long PFN group (62.5 minutes vs. 45.6 minutes, p = 0.02). There was no statistically significant difference in the postoperative outcome of both the groups and the data was comparable. Two patients in short PFN group and 3 patients in long PFN group required 1 unit blood transfusion postoperatively. The mean hospital stay for both groups was similar at approximately 5 days. None of the patients of either group had any infection during follow-up. Two patients (1 in each group) had serous discharge and soakage which was sterile on culture and eventually resolved with regular dressing and change of antibiotics. The mean time for radiological signs of union were almost same in both groups (3±1 months).

The mean Harris hip score was 76.63 for short PFN group and 79.87 for long PFN group at 6 months and at 12 months were 83.22 and 85.63 respectively (Figure 1).

**Figure 1. Average Functional Score (Harris Hip Score) at different follow-up.**



Few patients also complained of thigh pain which included 6 patients of short PFN and 2 patients of long PFN. During 3 months of follow up, one patient of short PFN group had lag screw cut out which was reoperated and convert into a hemiarthroplasty, whereas one patient in long PFN group had a fracture at the distal end of the nail and treated by using a locking plate.

#### IV. Discussion

Hip fractures are the one of the most common fractures occurs in the osteoporotic elderly population which is significantly associated with higher mortality and morbidity rate.<sup>2</sup> For peri-trochanteric fractures, Proximal Femoral Nail (PFN) is the better implant of choice compare to the Dynamic Hip Screw (DHS), or Dynamic Condylar Screw (DCS). PFN is a biomechanically superior implant, and associated with less surgical time, less fluoroscopy exposure, fewer complications and early mobilisation compared to DHS or DCS.<sup>4,6</sup>

This study was designed to compare outcomes for short versus long proximal femoral nail for peri-trochanteric femoral fractures. In present study, the average intraoperative blood loss and the mean surgery duration were significantly more in long PFN group compare to short PFN group. During long PFN insertion, more reaming and opening of canal were required as well as distal locking was done by free hand technique, more bleeding and more operative time. Guo et al. also found that the intraoperative blood loss was more in long PFN group compare to short PFN group (127.8±85.9 ml and 90.7±50.6 ml, respectively), and the short PFN group also had a significantly shorter operative time (43.5 min±12.3 min vs. 58.5 min±20.3 min).<sup>7</sup> We found that Short PFN has a significantly shorter surgical time, that benefit should be consider for treating peri-trochanteric fractures in emergent situations, like extremely sick patients, poor anesthesia candidates, and polytrauma patients. Harrington et al., Rao et al., and Mall et al. reported that the average time of radiological union were 16 weeks, 18 weeks and 14 weeks respectively.<sup>8-10</sup> This was similar to the average time of union in our study is 14.7 weeks (14.2 weeks for short PFN and 15.1 weeks for long PFN). There was no statistically significant difference between short PFN group and long PFN in regards of average time of radiological union, re-fracture, major reoperation, and Harris hip score. Kale et al., and Shyamkumar et al. also reported almost similar Harris hip score 1 year postoperatively in both groups.<sup>11,12</sup>

In our study, total of 8 patients reported thigh pain during follow-up, out of which 6 patients were treated with short PFN. Short PFN group had more thigh pain which may be attributed to the shorter working length of PFN and narrow proximal canal which puts more stress on the proximal femoral shaft cortices.<sup>12</sup>

Hwang et al. reported that precise nail entry point and correct insertion technique of PFN avoid the operating surgeon a lot of grief, as well as reduced surgery duration and bleeding. While performing PFN, the ethnic background of the patient should be considered, especially in the Asian population. An excessive anterior bow in a relatively shorter femur should be paid special attention.<sup>13,14</sup> The limitations of this study include small sample size and small follow up.

## V. Conclusion

The treatment of Peri-trochanteric fractures will continue to be a challenge to the treating surgeon. Both short and long PFN provide rigid fixation and have almost same functional outcome for intertrochanteric fractures. Short PFN is better for intertrochanteric fractures with fracture line up to lesser trochanter (AO 31A1 and A2) due to less intraoperative bleeding and less surgery duration, while long PFN is better for intertrochanteric fractures with sub-trochanteric extension (more than 3 cm) and severe osteoporosis, because it provides more rigid fixation and less chances of refracture. From our data and analysis we conclude that safe, predictable outcomes for the surgical fixation of intertrochanteric hip fractures are obtainable with both short and long PFN.

## Conflict of Interest

The authors declare that they have no competing interests

## References

- [1]. Cornwall R, Gilbert MS, Koval KJ, Strauss E, Siu AL. Functional Outcomes And Mortality Vary Among Different Types Of Hip Fractures: A Function Of Patient Characteristics. *Clinical Orthopaedics And Related Research*. 2004 Aug(425):64.
- [2]. Cumming RG, Nevitt MC, Cummings SR. Epidemiology Of Hip Fractures. *Epidemiologic Reviews*. 1997 Jan 1;19(2):244-57.
- [3]. Boldin C, Seibert FJ, Fankhauser F, Peicha G, Grechenig W, Szyszkowitz R. The Proximal Femoral Nail (PFN)-A Minimal Invasive Treatment Of Unstable Proximal Femoral Fractures: A Prospective Study Of 55 Patients With A Follow-Up Of 15 Months. *Acta Orthopaedica Scandinavica*. 2003 Jan 1;74(1):53-8.
- [4]. Xu YZ, Geng DC, Mao HQ, Zhu XS, Yang HL. A Comparison Of The Proximal Femoral Nail Antirotation Device And Dynamic Hip Screw In The Treatment Of Unstable Pertrochanteric Fracture. *Journal Of International Medical Research*. 2010 Aug;38(4):1266-75.
- [5]. Shen L, Zhang Y, Shen Y, Cui Z. Antirotation Proximal Femoral Nail Versus Dynamic Hip Screw For Intertrochanteric Fractures: A Meta-Analysis Of Randomized Controlled Studies. *Orthopaedics & Traumatology: Surgery & Research*. 2013 Jun 1;99(4):377-83.
- [6]. Şahin EK, İmerci A, Kınık H, Karapınar L, Canbek U, Savran A. Comparison Of Proximal Femoral Nail Antirotation (PFNA) With AO Dynamic Condylar Screws (DCS) For The Treatment For Unstable Peritrochanteric Femoral Fractures. *European Journal Of Orthopaedic Surgery & Traumatology*. 2014 Apr;24:347-52.
- [7]. Guo XF, Zhang KM, Fu HB, Cao W, Dong Q. A Comparative Study Of The Therapeutic Effect Between Long And Short Intramedullary Nails In The Treatment Of Intertrochanteric Femur Fractures In The Elderly. *Chinese Journal Of Traumatology*. 2015 Dec 1;18(06):332-5.
- [8]. Harrington KD, Johnson JO. The Management Of Comminuted Unstable Intertrochanteric Fractures. *JBJS*. 1973;55A:1367.
- [9]. RAO JP, Banzon MT, WEISS AB, RAYHACK J. Treatment Of Unstable Intertrochanteric Fractures With Anatomic Reduction And Compression Hip Screw Fixation. *Clinical Orthopaedics And Related Research (1976-2007)*. 1983 May 1;175:65-71.
- [10]. Mall B, Kumar Pathak S, Malhotra V. Role Of Dynamic Compression Hips Screw In Trochanteric Fracture Of Femour. *Indian Journal Of Orthopaedics*. 1999 Jul;33(3):226-8.
- [11]. Kale D, Munde D, Mangukiya D, Waghmare D. A Comparative Study Of Long Versus Short Proximal Femoral Nail In Peritrochanteric And Subtrochanteric Fractures In Adults. *International Journal Of Orthopaedics Sciences*. 2018;4:717-21.
- [12]. Shyamkumar C, Rao AS, Rao DV, Vikramkumar J. Comparative Study Between Long PFN And Short PFN In Treatment Of Stable Intertrochanteric Fracture Femur. *Journal Of Dental And Medical Sciences*. 2018;17(1):23-9.
- [13]. Hwang JH, Oh JK, Han SH, Shon WY, Oh CW. Mismatch Between Pfna And Medullary Canal Causing Difficulty In Nailing Of The Pertrochanteric Fractures. *Archives Of Orthopaedic And Trauma Surgery*. 2008 Dec;128(12):1443-6.
- [14]. Tang WM, Chiu KY, Kwan MF, Ng TP, Yau WP. Sagittal Bowing Of The Distal Femur In Chinese Patients Who Require Total Knee Arthroplasty. *Journal Of Orthopaedic Research*. 2005 Jan 1;23(1):41-5.