

# Ovarian Pregnancy : A Case Report And Review Of The Literature

Professor Lounas Benghanem

Head Of The Gynecology And Obstetrics Department, Mustapha University Hospital Center, Faculty Of Algiers I. Algeria.

Lydia Faïd

Obstetrician Gynecologist Gynecology And Obstetrics Department, Mustapha University Hospital Center, Faculty Of Algiers I. Algeria.

Mounir Bisker

Obstetrician Gynecologist Gynecology And Obstetrics Department, Mustapha University Hospital Center, Faculty Of Algiers I. Algeria.

Kamel Haïl

Professor In General Surgery, Mustapha University Hospital Center, Faculty Of Algiers I. Algeria.

---

## Abstract

Ovarian pregnancy is a rare form of extra uterine pregnancy.

It is a particular pathology in terms of its clinical presentation, diagnosis and therapeutic management. We report a case of ovarian extra uterine pregnancy managed laparoscopically.

**Keywords:** Ectopic pregnancy, Ovary, Laparoscopy, A case report.

---

Date of Submission: 25-12-2023

Date of Acceptance: 05-01-2024

---

## I. Introduction

Ectopic pregnancy is one of the most frequent medical and surgical emergencies in gynaecology. Pregnancy is most often located in the fallopian tube (94% of cases) [1]. Although ovarian location comes second, it is exceptional and accounts for only 3% of all ectopic pregnancies [2]. Clinical signs are poor and non-specific, and ultrasound diagnosis is difficult, which means that ectopic pregnancies are often discovered intraoperatively [3].

We report the case of a right ovarian pregnancy in a 28-year-old woman.

## II. Patient and observation

### Patient information :

A 28 year old patient with no notable pathological history G3P2 who presented with acute pelvic pain with minimal metrorrhagia and amenorrhoea of 7 weeks. On examination the patient was found to be in good general condition, with tenderness in the right iliac fossa and filling of the right cul de sac of Douglas. Ultrasound showed an empty uterus with a heterogeneous latero-uterine image measuring 53 mm, juxtaposed with the right ovary, with no intraperitoneal effusion. The beta-HCG level was 7267 IU/l.

### Therapeutic intervention :

The patient was operated on by laparoscopy the following morning, intraoperatively both tubes were healthy (figure 1) and a hypervascularised tumour ovary (figure 2) was discovered, we proceeded to a partial oophorectomy with thermofusion (figure 3,4). The surgical specimen was extracted in an endobag (figure 5,6).

### Follow-up and results :

The beta-HCG level fell by more than 50% 48 hours after the operation, and anatomopathological examination confirmed an extra uterine ovarian pregnancy.

### III. Discussion

Ovarian pregnancy is the most common form of rare ectopic pregnancy. It was first described by Mercurius in 1614 [4].

The risk factors for ovarian pregnancy are not different from those for tubal pregnancy, and are often young multiparous women with intrauterine devices [5]. Contraception with intrauterine devices appears to be particularly associated with ovarian pregnancy, with several series finding 57-90% of patients with IUDs [6].

Spielberg in 1878 [4] described 4 anatomopathological criteria for diagnosing ovarian pregnancy:

- The tube on the affected side must be healthy
- The ovarian sac must occupy the usual anatomical position of the ovary
- The ovary and gestational sac must be connected to the uterus by the utero-ovarian ligament
- Ovarian tissue must exist within the ovarian sac.

The aim of these criteria is to eliminate pregnancies that are secondarily grafted onto the ovary; our patient meets all these criteria perfectly.

Sergent et al [7] suggest combining Spielberg's 4 criteria with :

- The existence of an EP confirmed by a plasma beta-HCG level greater than 1000 IU/L
- Ovarian involvement confirmed intraoperatively, with the presence of an atypical ovarian formation or visualisation of trophoblast in the ovary.
- Both fallopian tubes are healthy
- Decrease and negativation of beta-HCG levels after treatment of the ovary.

From a pathophysiological point of view, several theories have been described to explain the occurrence of an ovarian pregnancy. The aetiopathogenesis of GO has not been clearly defined. There are several opposing hypotheses, but the mechanism seems to be transtubal reflux of the fertilised oocyte into the ovary [8].

- The theory of intra-follicular fertilisation of the non-expelled oocyte. This theory is refuted because the oocyte undergoes maturation outside the follicle.
- The theory of extra-follicular fertilisation with implantation on the scar of the follicular ostium, rarely implantation will take place further away from the corpus luteum, or even on the contralateral ovary.
- The theory of an ovarian graft from a tubo-abdominal abortion.

Therapeutically, the reference treatment for ovarian pregnancy is surgery, ideally conservative by laparoscopy [9].

Medical treatment is rarely described in the literature [10]. This is probably due to the fact that the diagnosis is often made late, thus ruling out the use of methotrexate.

In terms of prognosis, ovarian pregnancy does not compromise subsequent fertility in patients, and recurrence is exceptional due to the absence of tubal involvement. It is not a risk factor for recurrence, but an accidental extra-uterine pregnancy.

### IV. Conclusion

Ovarian pregnancy is an extra uterine pregnancy of rare localisation, a rare pathology which is often difficult to diagnose and often discovered during an operation, the therapeutic management of which is conservative surgery, ideally laparoscopic.

#### Figures

**Figure 1 :** Healthy appearance of both fallopian tubes

**Figure 2 :** Masse ovarienne droite tumorale hypervascularisée

**Figure 3 :** Partial oophorectomy by thermofusion

**Figure 4 :** Perfect haemostasis

**Figure 5 :** Surgical part placed in an endogag

**Figure 6 :** Extraction of the specimen through the left trocar port

**Figure 7 :** Overall view of the pelvis after partial oophorectomy

**Figure 8 :** Partial oophorectomy specimen with pregnancy removed

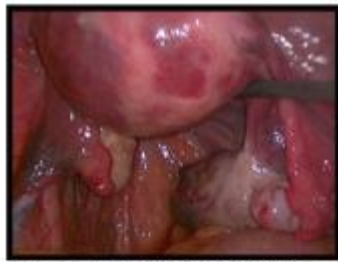

Figure 1 : Healthy appearance of both fallopian tubes

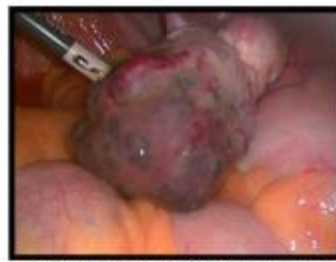

Figure 2 : Hypervascularised right ovarian tumour mass

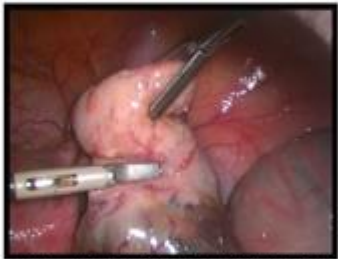

Figure 3 : Partial oophorectomy by thermofusion

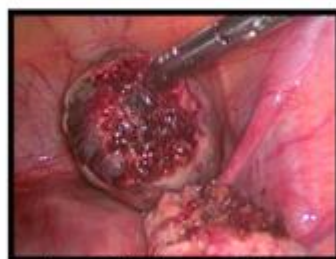

Figure 4 : Perfect haemostasis

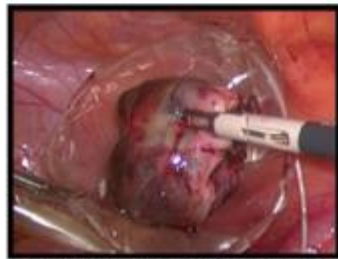

Figure 5 : Surgical part placed in an endobag

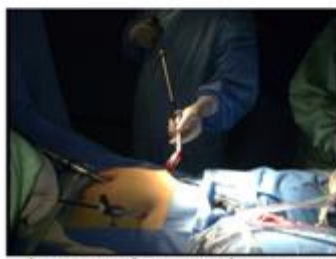

Figure 6 : Extraction of the specimen through the left trocar port

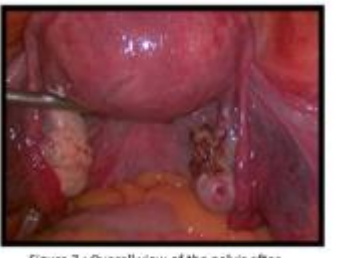

Figure 7 : Overall view of the pelvis after partial oophorectomy

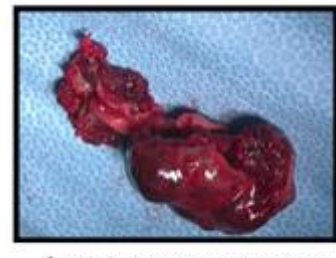


Figure 8 : Partial oophorectomy specimen with pregnancy removed

## References

- [1]. Agdi, M., & Tulandi, T. (2009). Surgical Treatment Of Ectopic Pregnancy. *Best Practice & Research Clinical Obstetrics & Gynaecology*, 23(4), 519-527.
- [2]. Kraemer, B., Abele, H., Hahn, M., Wallwiener, D., Rajab, T. K., & Hornung, R. (2008). Cervical Ectopic Pregnancy On The Portio: Conservative Case Management And Clinical Review. *Fertility And Sterility*, 90(5), 2011-E1.
- [3]. Sergent, F., Mauger-Tinlot, F., Gravier, A., Verspyck, E., & Marpeau, L. (2002). Grossesses Ovariennes: Réévaluation Des Critères Diagnostiques. *Journal De Gynécologie Obstétrique Et Biologie De La Reproduction*, 31(8), 741-746.
- [4]. Grall, J., & Jacques, Y. (1978). Ovarian Pregnancy: A Review Of Four Cases. *Revue Française De Gynécologie*, 73(2), 139-145.
- [5]. Herbertsson, G., Magnusson, S. S., & Benediktsdottir, K. (1987). Ovarian Pregnancy And Iucd Use In A Defined Complete Population. *Acta Obstetrica Et Gynecologica Scandinavica*, 66(7), 607-610.
- [6]. Pan, H. S., Huang, L. W., Lee, C. Y., Hwang, J. L., & Chang, J. Z. (2004). Ovarian Pregnancy Torsion. *Archives Of Gynecology And Obstetrics*, 270, 119-121.
- [7]. Sergent, F., Mauger-Tinlot, F., Gravier, A., Verspyck, E., & Marpeau, L. (2002). Ovarian Pregnancies: Reevaluation Of Diagnostic Criteria. *Journal De Gynecologie, Obstetrique Et Biologie De La Reproduction*, 31(8), 741-746.
- [8]. Young, R. H. (2001). A Half Century In Gynecological Pathology: Reminiscences Of Robert E. Scully On His Career: An Interview With Robert H. Young. *International Journal Of Gynecological Pathology*, 20(1), 2-15.
- [9]. Cepni, I., Ocal, P., Erkan, S., & Erzik, B. (2004). Conservative Treatment Of Cervical Ectopic Pregnancy With Transvaginal Ultrasound-Guided Aspiration And Single-Dose Methotrexate. *Fertility And Sterility*, 81(4), 1130-1132.
- [10]. Marcus, S. F., & Brinsden, P. R. (1993). Primary Ovarian Pregnancy After In Vitro Fertilization And Embryo Transfer: Report Of Seven Cases. *Fertility And Sterility*, 60(1), 167-169.