

“Maxillary Unicystic Ameloblastoma- A Rare Tumour”

¹Dr.Prachi Dwivedi, ²Dr.Shaji Thomas, ³Dr.Indrajeet Raghuwanshi, ⁴Dr.Ayush Kharia, ⁵Dr.Mohd Javed

¹Dr.Prachi Dwivedi, BDS, MDS, Resident, Department of Oral and Maxillofacial Surgery, People's College of Dental Sciences and Research Center, Bhopal, Madhya Pradesh, India.

²Dr. Shaji Thomas, BDS, MDS, Professor and Head, Department of Oral and Maxillofacial Surgery, People's College of Dental Sciences and Research Center, Bhopal, Madhya Pradesh, India.

³Dr.Indrajeet Raghuwanshi, BDS, MDS, Resident, Department of Oral and Maxillofacial Surgery, People's College of Dental Sciences and Research Center, Bhopal, Madhya Pradesh, India.

⁴Dr. Ayush Kharia, BDS, MDS, Resident, Department of Oral and Maxillofacial Surgery, People's College of Dental Sciences and Research Center, Bhopal, Madhya Pradesh, India.

⁵Dr.Mohd Javed, BDS, MDS, Resident, Department of Oral and Maxillofacial Surgery, People's College of Dental Sciences and Research Center, Bhopal, Madhya Pradesh, India.

E-Mail Id- prachipd96@gmail.com

Corresponding Author: 1Dr.Prachi Dwivedi, BDS, MDS, Resident, Department of Oral and Maxillofacial Surgery, People's College of Dental Sciences and Research Center, Bhopal, Madhya Pradesh, India.

Contact No: +91- 8840749409

E-Mail Id: prachipd96@gmail.com

Type of Publication: Case Report

Conflicts of Interest: Nil

ABSTRACT

BACKGROUND: Ameloblastoma is the most common odontogenic tumour arising from odontogenic epithelium. It is often aggressive and destructive, with the capacity to attain great size, erode bone and invade adjacent structures. Most of the UA clinically and radiographically resemble denigerous cysts in behaviour. The lesion histologically shows typical ameloblastomatous epithelium lining part of the cyst cavity with or without and/or mural tumor growth. Unicystic ameloblastoma usually presents in posterior mandibular ramus region, while it is rare and atypical in posterior maxillary region.

CASE PRESENTATION: - A 28y Male reported to the OPD of department of oral and maxillofacial surgery, PCDS with complain of swelling over left side of face region since 8 months. On examination well-circumscribed, nontender, non-fluctuant, smooth surfaced swelling of hard consistency was present in the left maxillary region.

The histopathological examination of the lesion revealed confirmed finding for unicystic ameloblastoma mural form. The lesion was surgically enucleated using Carnoy's solution; teeth and vital structures were preserved; satisfactory healing was achieved without any postoperative complications. Mandatory 1 year follow-up was done for the patient to rule out risk of recurrence.

CONCLUSION: Unicystic ameloblastoma rarely occurs in maxillary region. We emphasize the importance of differential diagnosis of an odontogenic lesion with common clinical and radiological features that will impact the treatment planning and follow up. Unilocular radiolucencies can be diagnosed as unicystic ameloblastoma.

KEYWORDS: Unicystic ameloblastoma, Enucleation, Cystic lesion, Carnoy's solution.

Date of Submission: 29-01-2024

Date of Acceptance: 09-02-2024

INTRODUCTION

Ameloblastoma is a benign odontogenic tumor generally present in the jaw bone. The tumor originates from the residual epithelium of the tooth germ, epithelium of odontogenic cysts stratified squamous epithelium and epithelium of the enamel organ. It represents approximately 1% of oral tumors.

They are classified as unicystic, multicystic or solid, 86% of cases are multicystic ameloblastomas. Ameloblastoma in the mandible can progress to great size and cause facial asymmetry, displacement of teeth, malocclusion, and pathologic fractures.

Unicystic ameloblastoma (UA) represents an ameloblastoma variant, presenting as a cyst that show clinical and radiologic characteristics of an odontogenic cyst. In histologic examination shows a typical ameloblastomatous epithelium lining part of the cyst cavity, with or without luminal and/or mural tumor proliferation.

The response of Unicystic Ameloblastoma to enucleation or curettage is more favorable than the solid multicystic ameloblastomas. Treatment of UA includes both radical and conservative surgical excision, curettage, chemical and electrocautery, radiation therapy or combination of surgery and radiation.

The purpose of this article is to present a rare case report of Unicystic Ameloblastoma in atypical location into the left anterior and premolar maxillary region.

CASE PRESENTATION

A 28y Male reported to the OPD of department of oral and maxillofacial surgery, PCDS with complain of swelling over left side of face region in the past 8 months. Patient had history of trauma (fall from bicycle) 10 years back. Patient complained of frequent symptoms of sinusitis.

On Extraoral examination facial asymmetry was present over left side of face region. A Well-circumscribed, nontender, non-fluctuant, smooth surfaced swelling of hard consistency was present in the left maxillary region. The skin overlying the swelling was normal. Obliteration of nasolabial fold was present along with slight elevation of alar base on the left side.

Intraoral examination revealed a painless swelling in the left maxillary vestibule extending from the maxillary right central incisor to the maxillary left first molar (Fig 1). The intraoral swelling was firm, nontender, covered with normal mucous membrane. Egg shell cracking was present buccally but not over palatal region. Ellis class II fracture was present w.r.t 22. Tenderness on percussion was present w.r.t 11 and 21 teeth.

An FNAC was done (Fig 2) to aspirate the cystic contents and to ease the diagnosis. FNAC reports suggested acute suppurative lesion with presence of polymorphic cells and large necrotic contents.

CBCT Maxilla (Fig 3) revealed a unilocular radiolucent lesion extending from 13 to 26 was appreciated. Knife edge resorption can be appreciated w.r.t 25.

NCCT OF PNS reported an expansile cystic lesion arising from maxillary body with expansion into left maxillary sinus and nasal cavity. A 4.4cm x 3.4cm x 4.9cm sized lesion was noted. It showed smooth thinning of walls w.r.t roots of canine and incisors. Narrowing of left maxillary sinus, resorption of lower nasal septum and left anterior turbinate.

Preoperative diagnosis of the lesion was made as dentigerous cyst based on the age of the patient, location of the swelling, aspirated thick juicy yellow liquid and visible cholesterol crystals, but the UA was also taken into consideration.

The surgical operation including total enucleation of the cystic lesion. (Figs. 4, 5,6). After removing the lesion and after measuring it, the lesion was approximately 5 cm in length (Fig. 7). The specimen was sent for pathological examination. The pathological examination revealed UA(Fig.8), intraluminal type. Infiltrating islands of atypical basaloid cells with peripheral palisading were present. Separation artifact of peritumoral stroma was evident.

The nature of the tumour was explained to the patient and we advised the patient to regard regular follow-up visits. There were no signs of recurrence in the past 1 year after the operation.

DISCUSSION

UA is a rare type of ameloblastoma, accounts for about 6 % of all ameloblastoma. It affects mandible more often than maxilla and in about 50 % of the cases occur in the second decade of life. It is presented more commonly in the mandible than in the maxilla in the ratio of 13:1. The tumour is observed in mandibular-ramus region, while posterior region of maxilla is considered to be rare and atypical. This variant is believed to be less aggressive, tends to affect patients at a younger age and its response to enucleation or curettage is more favourable than the classic solid or multicystic ameloblastomas.

In 1977, Robinson and Martinez first used the term “UA” but it was also named in the second edition of the international histologic classification of odontogenic tumors by the WHO as “cystogenic ameloblastoma.” 5-15% of all ameloblastomas are of the unicystic type.

It is presented as a painless swelling, facial asymmetry, tooth impaction, tooth displacement, mobility, or tooth resorption. On radiographic imaging the unilocular lesion with well defined sclerotic borders is seen. The differential diagnosis of UA should include keratocystic odontogenic tumor, residual cyst, central fibroma, central giant cell granuloma and dysplastic fibrosis.

There are different classifications of unicystic ameloblastoma. Based on the clinicopathologic study of 57 cases of unicystic ameloblastoma, Ackerman’s classification into three histologic groups is as follows:

- I. Luminal UA (tumor confined to the luminal surface of the cyst);

II. Intraluminal/plexiform UA (nodular proliferation into lumen without infiltration of tumor cells into connective tissue wall); and

III. Mural UA (invasive islands of ameloblastomatous epithelium in the connective tissue wall not involving the entire epithelium)

According to this classification, our case study belongs to Group II.

There is another grouping by Philipsen and Reichart which describes the forms of UA as follows:

Subgroup 1. Luminal UA;

Subgroup 1.2. Luminal and intraluminal;

Subgroup 1.2.3. Luminal, intraluminal and intramural;

Subgroup 1.3. Luminal and intramural.

Three pathogenic mechanisms for the evolution of UA: Reduced enamel epithelium, from dentigerous cyst and due to cystic degeneration of solid ameloblastoma.

The use of Carnoy's solution to decrease the risk of recurrence after conservative surgical treatment of UA's was initially suggested by Stoelinga and Bronkhorst in 1988. Also, it is advocated that vigorous curettage of the bone should be avoided because it may implant foci of ameloblastoma more deeply in bone.

According to a retrospective study of 29 patients by Lee et al., when Carnoy's solution was applied for 3 minutes after cyst enucleation despite a diagnosis of UAB histologically exhibiting 93% mural invasion, a low 10% recurrence rate was reported. This suggests that Carnoy's solution may be beneficial against recurrence. Lau and Samman reported recurrence rates of 3.6 % for resection, 30.5 % for enucleation alone, 16 % for enucleation followed by Carnoy's solution application, and 18 % by marsupialisation followed by enucleation, where the lesion is reduced in size.

CONCLUSION

Maxillary region is considered a rare and atypical location for unicystic ameloblastoma. We emphasize the importance of differential diagnosis of an odontogenic lesion with common clinical and radiological features that will impact the treatment planning and follow up. As oral health providers we should be aware that the unilocular radiolucencies may be unicystic ameloblastoma.

Every unilocular radiolucency of the jaw should be closely monitored and examined since UA shares significant clinical and radiographic similarities with odontogenic cysts and tumors. Neither the incisional biopsy may be able to reflect the true nature of the lesion nor the aspirational cytology. Long-term follow-up is mandatory because of the recurrence risk of unicystic ameloblastoma, which may occur after a long time.

Abbreviations:

UA: Unicystic ameloblastoma, WHO: World Health Organization, FNAC: Fine needle Aspiration cytology, CBCT: Cone beam computed tomography system, NCCT: Non-Contrast Computerized tomography, PNS: Paranasal sinus.

REFERENCES

- 1.Zana Agani1, Vjosa Hamiti- Krasniqi2, Jehona Recica1, Mergime Prekazi Loxha3*, Fisnik Kurshumliu4 and Aida Rexhepi5 DOI 10.1186/s13104-016-2260-
- 2.Masthan KM, Anitha N, Krupaa J, Manikkam S. Ameloblastoma. J Pharm Bioallied Sci. 2015 Apr;7(Suppl 1):S167-70. doi: 10.4103/0975-7406.155891. PMID: 26015700; PMCID: PMC4439660.
- 3.Gardner DG, Corio RL. Plexiform unicystic ameloblastoma. A variant of ameloblastoma with a low- recurrence rate after enucleation. Cancer. 1984;53:1730–5.
- 4.Stoelinga PJW, Bronkhorst FB. The incidence, multiple presentation and recurrence of aggressive cysts of the jaws. J Craniomaxillofac Surg. 1988;16:184–95.
- 5.Rasmané Béogo1*, Tarcissus Konsem2, Mathieu Millogo2, Hèra Michel Kohoun1, Toua Antoine Coulibaly1 and Ibraïma Traoré1J Oral Med Oral Surg Volume 24, Number 1, January 2018
- 6.K. AL Qahtani a, A.F. Alkudhayri b, T. Islam c, K. Al Mufargi b, W. Al Shakweer d, F. Otaibi b
- 7.Surgical management of ameloblastoma: Conservative or radical approach Ramakant Dandriyal, Atul Gupta, Swati Pant, and Hitesh Hans Baweja doi: 10.4103/0975-5950.85849
- 8.Maxillary Ameloblastoma: A Review With Clinical,Histological and Prognostic Data of a Rare Tumor ZOI EVANGELOU1, ATHINA ZARACHI 2, JEAN MARC DUMOLLARD3 doi:10.21873/in vivo.12035
- 9.Surgical management of ameloblastoma: Conservative or radical approach Ramakant Dandriyal, Atul Gupta, Swati Pant, and Hitesh Hans Baweja doi: 10.4103/0975-5950.85849

10. Agani, Z., Hamiti-Krasniqi, V., Recica, J. et al. Maxillary unicystic ameloblastoma: a case report. BMC Res Notes 9, 469 (2016). <https://doi.org/10.1186/s13104-016-2260-7>

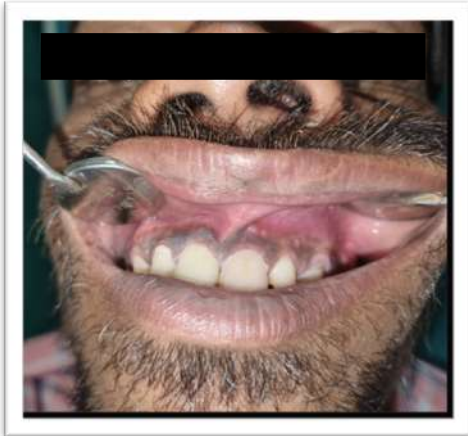

Fig:1 Pre-operative picture depicting intraoral lesion.



Fig 2: Fnac revealing thick yellow fluid.

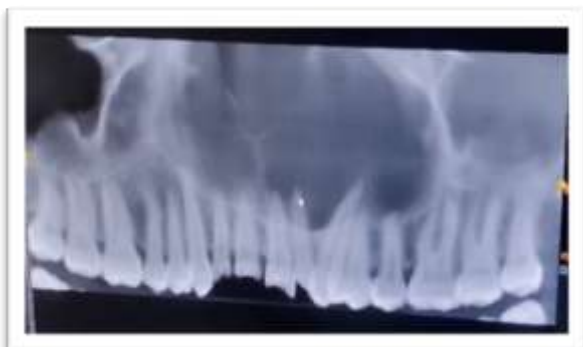
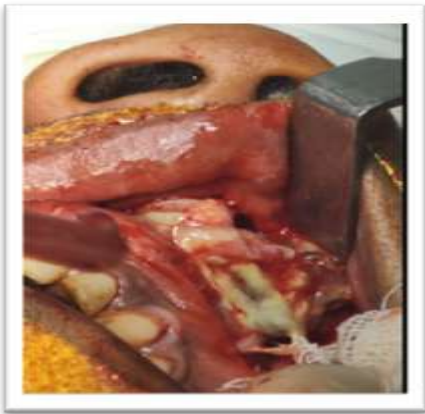
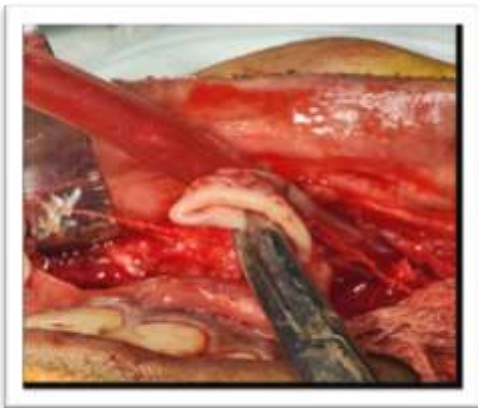Fig: 3 Cbct of maxilla depicting large lesion shown with arrows

Fig:4,5,6 Intra-operative pictures

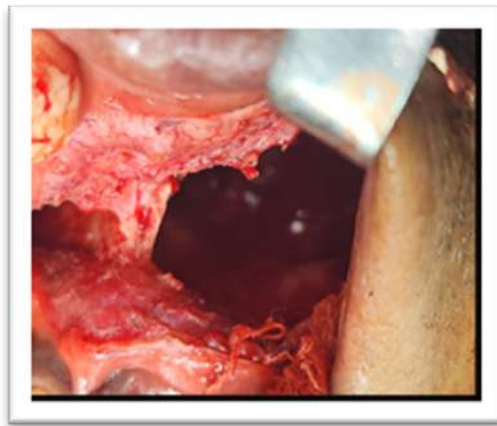

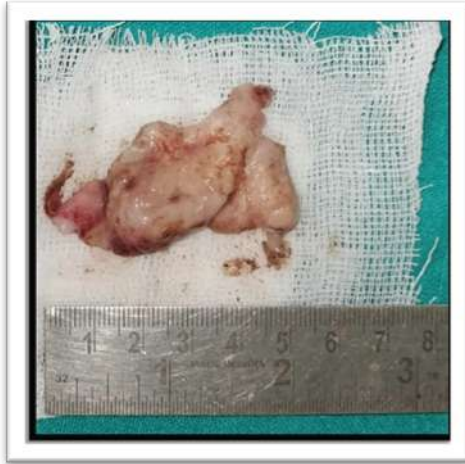


Fig:7 Enucleated lesion

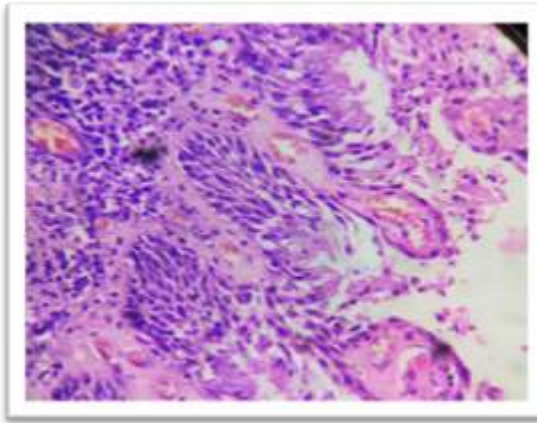


Fig: 8 Palisading basaloid cells