

Pinch-Off Syndrome: Critical And Vital Complicaion Of Central Venous Catheters

H. Dabachi, S. El Youbi, S. El Hibaoui, H. Naouli, H. Jiber, A. Bouarhroum,
A. El Ghalbi,

Service De Chirurgie Vasculaire Chu Hassan Ii, Fes
Service D'oncologie Medicale Chu Hassan Ii, Fes

Abstract:

Pinch-off syndrome (POS) is a rare and potentially life-threatening complication of implantable central venous catheters, and should be suspected when the catheter function changes with neck and arm movements, which occurs due to compression of the subclavian vein within the thoracic outlet. When POS is clinically suspected, the catheter should be promptly removed to avoid life-threatening complications such as catheter fracture and embolisation of its fragments

An interventional technique is usually preferred over surgical removal due to the risk of surgery in pediatric patients

We report a case of pinch-off syndrome successfully resolved by interventional treatment.

Keywords: Pinch-off syndrome (POS), implantable port catheter, migration, percutaneous extraction, lasso technique

Date of Submission: 25-03-2025

Date of Acceptance: 05-04-2025

I. Introduction:

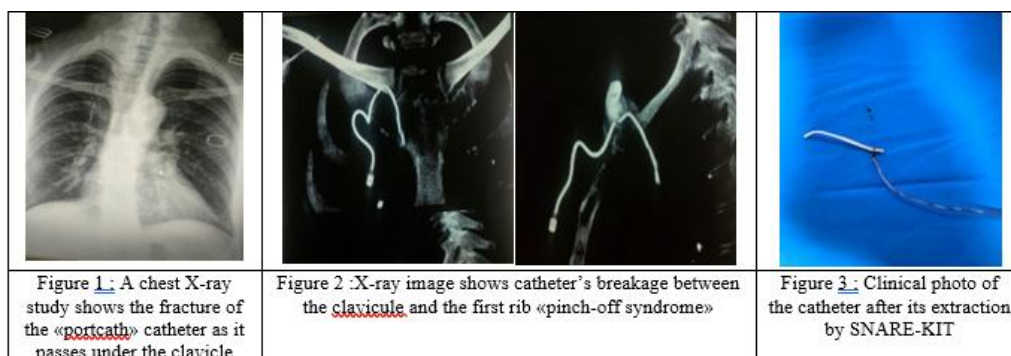
Implantable catheter ports have become essential tools in the management of patients receiving intravenous chemotherapy. It's a routine procedure, but it is also an invasive procedure with a significant complication rate. Several mechanical, infectious, and thromboembolic complications can occur. [1]

Port-a-caths placed via subclavian venous access can be affected by pinch-off syndrome, which results in catheter malfunction from compression by the subclavius-costoclavicular complex between the clavicle and first rib [2]

We report a rare case of a spontaneous fracture and embolization of a Port-a-cath., successfully resolved by endovascular treatment.

II. Observation :

We report the case of a 56-year-old patient with a history of breast cancer, who underwent surgery and received adjuvant chemotherapy through an implanted catheter. The device was inserted via percutaneous puncture of the right subclavian vein. After 12 years, the patient had a tumor recurrence with multiple secondary locations. Chemotherapy was prescribed, but the catheter was no longer functional. Chest X-ray showed catheter rupture in the costo-clavicular notch due to mechanical compression and repeated microtrauma between the clavicle and the 1st rib «Figure1» . This was confirmed by a thoracic angioscan «Figure2» . A successful percutaneous removal attempt was carried out through the right femoral vein. The catheter was completely extracted « Figure 3».



III. Discussion:

Implantable ports are medical devices that are completely implanted in the subcutaneous region, allowing direct and permanent access to the central venous system. These devices enable frequent and regular injections of blood-derived products (transfusions), chemotherapy, parenteral nutrition, or antibiotic therapy. Implantable ports consist of a housing connected to a catheter by a connecting ring, either at the time of insertion by the operator or during assembly by the manufacturer. The catheter entry point can be the subclavian vein, the internal jugular vein, or a femoral vein.

This life-saving procedure may be associated with immediate complications (pneumothorax, arterial puncture and hematoma) or late complications (thrombosis, infection), however, spontaneous fracture and migration of the catheter is a rare occurrence.

Catheter migrations have two origins: it may be either a complete mismatch between the housing and the catheter, or a catheter fracture. In the latter case, a portion of the catheter remains connected to the housing. [3]. Maladaptation is most often caused by improper fitting of the catheter to the housing during system installation.

A catheter fracture due to wear can have several origins: costoclavicular compression syndrome, known as "Pinch-off syndrome" (for subclavian catheters), repetitive daily life movements (arms, neck) causing shearing between the catheter's fixed parts - namely, the anchorage to the housing and the entry point into the vein (for arm-inserted catheters) - or high-pressure injections into the housing.

In our department, when we place implantable chambers, we prefer the internal jugular approach to avoid issues with catheter compression in the costo-clavicular pinch. Vein puncture under ultrasound guidance also helps prevent the risk of pneumothorax. Furthermore, during insertion, it is important to avoid extreme changes in catheter direction, as this is where catheter fractures occur,[4] especially when the catheter is placed via the brachial route. ,

The migration of venous catheters from implantable chambers is uncommon, ranging between 0.5 and 8% depending on the series. Moreover, these events are potentially serious, leading to thrombosis, sepsis, embolism, vascular perforation, cardiac rhythm disorders, depending on the migration site. [5].

Analysis of large series (100 and 92 patients) from the literature [6, 7] allows us to highlight the following points.

Firstly, the main migration site is the pulmonary artery, and in nearly 75% of cases, the catheter may migrate into the cardiac cavities. Migration into the hepatic veins is very rare. [6].

Secondly, if the tip of the catheter is difficult to grab with the snare (folding, intracardiac position with risks of rhythm disturbances, impaction against a vascular wall), it is advisable to move the catheter through a first maneuver before using the snare. This simple maneuver involves wrapping the catheter around a Pigtail catheter, then moving it to a simpler access site such as the inferior vena cava or an iliac vein. [8]. This allows to "straighten" the catheter and to grasp its end more easily. This initial maneuver is generally used in 20 to 50% of procedures [6,7], which was not necessary in our patient.

Thirdly, the main cause of failure is the absence of a free end and thus the probable endothelialization of the catheter, often due to a previous unnoticed migration. In this situation, the risks of extraction are higher than those of leaving the catheter in place. However, it can only be determined if the catheter is endothelialized if a retrieval device is positioned near the catheter; which is why an attempt at retrieval should be made in all cases.

Finally, failures are rare, linked to pulmonary arterial locations or old migrations; success rates range from 91 to 97%. [9]

IV. Conclusion

Our case confirmed the study which says that POS was the first cause of catheter embolism and should suggest the use of an alternative way for insertion instead of the subclavian access. When a catheter is inserted via a subclavian route, clinical and/or radiologic signs of POS require its removal.

The right internal jugular vein remains the best position to prevent POS , Although interventional techniques have made extraction of the distal fragment easier and less invasive .

Reference :

- [1] Ben Ismail, I. (2021). Migration D'un Cathéter De Chambre Implantable Dans L'artère Pulmonaire : Complication Inhabituelle. *Journal De Chirurgie Viscérale*, 158(4), S83–S84. Doi:10.1016/J.jchirv.2021.06.120 .
- [2] A Delayed Complication Of A Port-A-Cath Insertion Via Subclavian Venous Access: Case Report Of A "Pinch-Off Syndrome". Caiazzo M, Golino L, Addeo R, Fardello F, Russo G, Imperatore F. *Int J Surg Case Rep*. 2022 May;94:107039. Doi: 10.1016/J.ijscr.2022.107039. Epub 2022 Apr 7. PMID: 35461178)
- [3] Marcy P.Y., Lacout A., El Hajjam M. Failure Of Silicone Catheter Lines: Where, When And Why. *AJR Am J Roentgenol*. 2017;209:W49-W51.
- [4] Leinung S., Würfl P., Anders K., Deckert F., Shönfelder M. Port Catheter Fractures In 361 Implanted Port Systems: Analysis Of The Causes-Possible Solution – Review Of The Literature. *Chirurg*. 2002;73:696-699.
- [5] Brun A.L., Planché O., Claude-Desroches M. Radiologie Interventionnelle Thoracique. EMC - Radiologie Et Imagerie Médicale : Cardiovasculaire - Thoracique - Cervicale. 2011;18. [Article 32-500-A-10]

- [6] Bessoud B., De Baère T., Kuoch V. Experience At A Single Institution With Endovascular Treatment Of Mechanical Complications Caused By Implanted Central Venous Access Devices In Pediatric And Adult Patients. *AJR Am J Roentgenol.* 2003;180:527-532.
- [7] Cheng C.C., Tsai T.N., Yang C.C., Han C.L. Percutaneous Retrieval Of Dislodged Totally Implantable Central Venous Access System In 92 Cases: Experience In A Single Hospital. *Eur J Radiol.* 2009;69:346-350.
- [8] Mohandes M., Rojas S., Quintern V., Mercé J., Moreno C., Guarinos J. Percutaneous Retrieval Of A Port-A-Cath Using A Pigtail Catheter Combined With Snaring Technique. *Cardiovasc Revasc Med.* 2017;18:607-610.
- [9] B Ouaknine-Orlando I, E Desruennes, M F Cosset, T De Baere, A Roche[The Pinch-Off Syndrome: Main Cause Of Catheter Embolism] 1999 Nov;18(9):949-55. Doi: 10.1016/S0750-7658(00)87944-7