

Marfan Syndrome : A Case Report

Delphes Mathilde Otsasso Okomiko, Ghizlane Daghouj, Oumama Es-Samery,
Zyad Laftimi, Bouchra Allali, Loubna El Maaloum, Asmaa El Kettani

Abstract :

Purpose : The objective of the study is to describe a case of lens ectopia in children associated with Marfan syndrome.

Introduction :

Marfan syndrome accounts for 40% of congenital ectopies of the lens. It is transmitted in an autosomal dominant mode, as a result in mutation of a fibrillin-1 (FBN 1). In its complete form, it combines morphological, cardiovascular and ocular signs.

Observation :

We report the case of a 9-year-old child, from a consanguineous marriage, the first of two children, who had consulted ophthalmology for a progressive bilateral decrease in visual acuity in a non-traumatic context. Ophthalmological and general examination had revealed bilateral lens ectopia and a slender morphotype, respectively. The examination of the brother, aged 4, had noted bilateral lens ectopia with minimal lens displacement as well as heart disease. A cardiac ultrasound for etiological purposes had objectified tight mitral regurgitation associated with dilatation of the ascending aorta. The skin biopsy had noted an abnormality of fibrillin. Therapeutically, the child had benefited from anterior phacophagy without intraocular lens implantation, followed by correction of the aphakia with glasses and treatment for amblyopia.

Conclusion :

Marfan syndrome is a genetic fibrillinopathy with polymorphous clinical and paraclinical manifestations. The prognosis depends on heart damage, the main cause of death. The visual prognosis depends on the early surgical management and the well-conducted treatment of amblyopia.

Keywords: Lens ectopia-lens dislocation-Marfan syndrome.

Date of Submission: 01-04-2025

Date of Acceptance: 11-04-2025

I. Introduction :

Marfan syndrome accounts for 40% of congenital ectopies of the lens [1-2]. It is transmitted in an autosomal dominant mode, as a result of a mutation in the gene encoding fibrillin 1 (FBN1) [3-4]. It is due to a defect in fibrillin, which is the essential component. It affects collagen-rich organs, including the eyes, cardiovascular system, and ligament system. In its complete form, it combines morphological, cardiovascular and ocular signs. The most common ocular manifestations are lens ectopia in nearly 70% of cases and rhegmatogenous retinal detachment in about one-third of cases [5-6]. The objective of the study is to describe a case of lens ectopia in children associated with Marfan syndrome.

II. Observation :

We reported the case of a 9-year-old male child, from a consanguineous marriage, the first of two siblings who had consulted ophthalmology for a progressive bilateral decrease in visual acuity evolving over the past 2 years, without any notion of ocular trauma

The ophthalmological examination had revealed a visual acuity counting the fingers at 1 m in the right eye and 1/10 in the left eye. On examination of the anterior segment, there was a bilateral lens ectopia with an inferonasal displacement (Figures 1 and 2), which was greater in the right eye than in the left. The intraocular pressure was 19 mmHg and 16 mmHg in the right and left eyes, respectively. There were no retinal degenerative lesions on examination of the fundus and retinal periphery. Examination of the optic disc noted an excavation of 0.7 and 0.5 in the right and left eyes respectively.

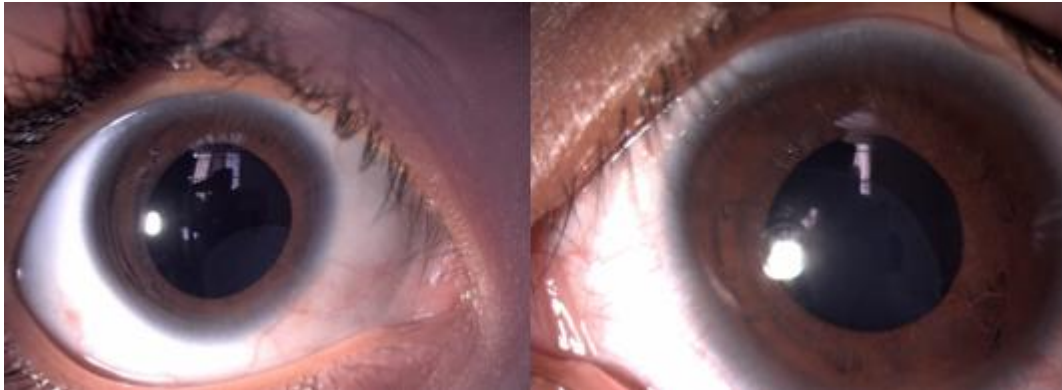


Figure 1 : Displacement Of The Lens In The Inferior Nasal (Right Eye)

Figure 2 : Displacement Of The Lens In The Nasal (Left Eye)

On general examination, the child had a slender morphotype combining dolichostenomelia and arachnodactyly (figure 3).

The examination of the brother, aged 4, had noted bilateral lens ectopia with a visual acuity of 5/10 and minimal lens displacement as well as heart disease.

A cardiac ultrasound had been performed for etiological purposes, and had objectified a tight mitral regurgitation associated with dilation of the aorta.

A protein test on a skin biopsy had revealed fibrillin abnormalities.

Therapeutically, the child had benefited from mitral and aortic plasty and then anterior phacophagy in both eyes, without intraocular lens implantation, with postoperative prevention of infective endocarditis. The aphakia was corrected with glasses, then the child was treated for amblyopia. After two years of follow-up, corrected visual acuity was 4/10, intraocular pressure was stable varying between 10-12 mmHg in both eyes, and optic disc excavation and visual field were stable. As for the younger brother, he had benefited from cardiology care and ophthalmological monitoring.

Genetic counselling had also been offered to the parents.

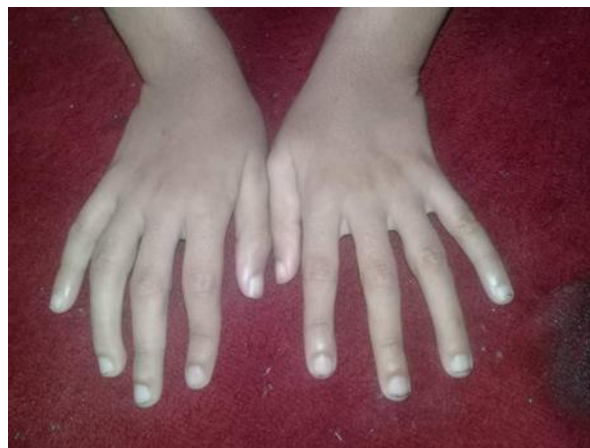

Figure 3 : Arachnodactyly

III. Discussion :

Described by Bernard-Jean Antonin Marfan in 1896 [7], Marfan syndrome is one of the most common fibrillinopathies with clinical polymorphism.

The prevalence of Marfan syndrome is estimated of 2 to 3 in 10,000 to 20,000 individuals [8]. Marfan syndrome accounts for 40% of congenital lens ectopies [1-2].

Marfan syndrome is inherited in an autosomal dominant mode, as a result of a mutation in the FBN 1 gene. It is a general disease affecting the collagen microfibril of the entire body. It is due to a defect in fibrillin, which is the essential component.

The main clinical manifestations are the large size of the affected subjects, who have a slender appearance, with small limbs (dolichostenomelia) and hands with long fingers (arachnodactyly), ligament laxity, insufficiency of the large vessels (most often aorta), cardiac involvement, aortic or mitral insufficiency, and of course ectopic microspherophakia. These abnormalities are part of the Ghent criteria [9-12]. The displacement

of the lens in Marfan syndrome is most often superotemporal but this is not a rule and all other anatomical types of subluxation can be seen.

Therapeutic management has several components. The age of the patient is an important factor to consider when choosing the surgical technique for lens ectopy [13]. For some authors, surgery is indicated when visual acuity is less than 3/10. Phacophagy associated with anterior vitrectomy by the pars plana remains the most widely used 78% according to Charif-Chefchaoui [14]. However, Erdogan [15] as well as Dogaroiu [16] had used three different techniques associated with intraocular lens implantation in their series. In our case, the child had benefited from anterior phacophagia associated with an anterior vitrectomy without intraocular lens implantation with correction of the aphakia made by glasses.

An improvement in visual acuity of 0.5 to 0.3 logMAR in a cohort of 39 patients treated with vitrectomy with and without Artisan implantation, over a study period ranging from 44 months to 3 years [17-18]. In a study by Rezar-Dreindl [19] on a series of 41 patients after a 3-year follow-up, acuity improved in 83% of patients who underwent phacophagia (with or without secondary implantation of Artisan). These results are similar to our case. From a cardiological point of view, a valvuloplasty is proposed in the event of valve insufficiency, which is the case for the child who had benefited from a mitral and aortic plasty.

The prognosis depends on vascular involvement, the most dangerous lesions being those of the root of the aorta, which can be the site of an aneurysm that can become dissectant, the main cause of death in these patients. The visual prognosis is conditioned by the precocity of treatment in children because of the risk of amblyopia [20].

IV. Conclusion :

Marfan syndrome is an autosomal dominant fibrillinopathy transmission with polymorphous clinical and paraclinical manifestations. The prognosis depends on heart damage, the main cause of death. The management is multidisciplinary and the visual prognosis in children is conditioned by good compliance with amblyopia treatment.

Conflict of interest:

No conflict of interest has been declared.

References:

- [1] Dieckmann C., Von Kodolitsch Y., Rybczynski M., Adam G. Marfan Syndrome: Pathogenesis, Phenotypes And Diagnostic Value Of Various Imaging Techniques. *Rofo* 2003;175:1482-9.
- [2] Vyskocil V., Varvarovska J., Koudela K. Marfan's Syndrome-- Application Of Revised Criteria And Differential Diagnosis In Clinical Practice. *Acta Chir Orthop Traumatol Cech* 2004;71:157-64
- [3] Ades LC, Holman KJ, Brett MS, Edwards MJ, Bennetts B. Ectopia Lentis Phenotypes And The FBN1 Gene. *Am J Med Genet* 2004;126A: 284-9
- [4] Comeglio P., Evans AL., Brice G., Cooling RJ., Child AH. Identification Of FBN1 Gene Mutations In Patients With Ectopia Lentis And Marfanoid Habitus. *Br J Ophthalmol* 2002;86:1359-6.
- [5] Wakita M., Ryu E., Nakayasu K., And Al. Statistical Analysis Of Marfan's Syndrome. *Nippon Ganka Gakkai Zasshi* 1989; 93: 682-690, [https:// Europepmc.Org/Article/Med/2816576](https://Europepmc.Org/Article/Med/2816576) (Accessed 6 December 2020).
- [6] Chandra A., Ekwalla V., Child A., Et Al. Prevalence Of Ectopia Lentis And Retinal Detachment In Marfan Syndrome. *Acta Ophthalmol* 2014; 92: E82-E83.
- [7] Gott VL. Antoine Marfan And His Syndrome: One Hundred Years Later. *Md Med J* 1998; 47: 247-252.
- [8] Yuan SM, Jing H. Marfan's Syndrome: An Overview. *Sao Paulo Med J*. 2010;128(6):360-366.
- [9] Loeys, B.L.; Dietz, H.C.; Braverman, A.C.; Callewaert, B.L.; De Backer, J.; Devereux, R.B.; Hilhorst-Hofstee, Y.; Jondeau, G.; Faivre, L.; Milewicz, D.M.; Et Al. The Revised Ghent Nosology For The Marfan Syndrome. *J. Med. Gen.* 2010, 47, 476-485. [Crossref] [Pubmed]
- [10] Von Kodolitsch Y., De Backer J., Schuler H., And Al. Perspectives On The Revised Ghent Criteria For The Diagnosis Of Marfan Syndrome. *Appl Clin Genet*. 2015;8:137-155.
- [11] Chandra A, Patel D, Aragon-Martin JA, Et Al. The Revised Ghent Nosology; Reclassifying Iso Lated Ectopia Lentis. *Clin Genet*. 2015;87(3):284 287.
- [12] Yang JH, Han H, Jang SY, Et Al. A Compar Ison Of The Ghent And Revised Ghent Nosologies For The Diagnosis Of Marfan Syndrome In An Adult Korean Population. *Am J Med Genet A*. 2012;158A(5):989-995.
- [13] Matsuo T. Howfar Is Observation Allowed In Patients With Ectopia Lentis ;Springerplus 2015, 4, 461. [Crossref] [Pubmed]
- [14] Charif-Chefchaoui M., Hajji Z., El Bakkali M., Boulanour A., Berrahoet A. Les Manifestations Oculaires Au Cours Du Syndrome De Marfan: Propos De 20 Cas. *Médecine Du Maghreb*. 2001;87:33-37.
- [15] Erdogan G., Kandemir Besek N., Onal Gunay B., Agca A. Outcomes Of Three Surgical Approaches For Managing Ectopia Lentis In Marfan Syndrome. *Eur. J. Ophthalmol*. 2022, 32, 242-248. [Crossref] [Pubmed]
- [16] Dogaroiu A.C., Duda M., Dogaroiu C., Tataru C.P. Visual Outcomes In Ectopia Lentis In Marfan Syndrome : A Study Of Four Surgical Techniques In Children And Adults. *Medicina* 2024, 60, 1098. <https:// Doi.Org/10.3390/Medicina60071098>
- [17] Rabie HM, Javadi MA, Et Al. Visual Outcomes After Lensectomy And Iris Claw Artisan Intraocular Lens Implantation In Patients With Marfan Syndrome. *Int Ophthalmol*. 2017;37:1025-1030.
- [18] Fan F., Luo Y., Liu X., Lu Y., Zheng T. Risk Factors For Postopera Tive Complications In Lensectomy-Vitrectomy With Or Without Intra Ocular Lens Placement In Ectopia Lentis Associated With Marfan Syndrome. *Br J Ophthalmol*. 2014; 98:1338-1342.
- [19] Rezar-Dreindl S., Stifter E., Neumayer T., Papp A., Gschliesser A., Schmidt Erfurth U. Visual Outcome And Surgical Results In Children With Marfan Syndrome. *Clin Experiment Ophthalmol*. 2019;47:1138-1145. <https://Doi.Org/10.1111/Ceo.13596>