

Anaesthesia in a Parturient with Myasthenia Gravis- Transient Myasthenia in newborn

Dr Nidhi Kumar¹, Dr Gaurav Chopra², Dr Rohit Goyal³

¹(Assistant Professor, Department of Anaesthesia, Himalayan Institute of Medical Sciences/ HIHT University, Dehradun, India)

²(Associate Professor, Department of Anaesthesia, Himalayan Institute of Medical Sciences/ HIHT University, Dehradun, India)

³(Assistant Professor, Department of Anaesthesia, Himalayan Institute of Medical Sciences/ HIHT University, Dehradun, India)

Abstract: Myasthenia gravis is an acquired chronic autoimmune disorder caused by decrease in functioning of acetylcholine receptors at the neuromuscular junctions owing to their destruction or inactivation by circulating antibodies. Disease manifests in the form of easy fatigability, weakness, difficulty in swallowing and even paralysis of respiratory muscles necessitating assisted ventilation. The clinical course of myasthenia gravis and its effect on pregnancy outcome is unpredictable. Worsening of symptoms can occur at any stage during pregnancy and also in post operative period. We are reporting a case of maternal myasthenia gravis who underwent caesarean section and developed respiratory distress after 20 minutes of spinal anaesthesia. Her baby also had a weak cry, hypotonia and tachypnoea. Baby was shifted to neonatal intensive care unit with continuous oxygen supplementation. Baby was kept under close observation and recovered well after two weeks.

Keywords - ENNS score, Myasthenia gravis, Pregnancy, Transient neonatal myasthenia.

I. INTRODUCTION

Myasthenia gravis is an acquired chronic autoimmune disorder caused by decrease in functioning of acetylcholine receptors at the neuromuscular junctions owing to their destruction or inactivation by circulating antibodies. The origin of these antibodies is unknown, but a role of thymus gland is suggested. Hyperplasia of the thymus gland is present in more than 70% of patients with myasthenia gravis and 10 -15% of these patients have thymomas.

II. CASE REPORT

We present a typical case of a 30 years old female patient who was a known case of myasthenia gravis with thymoma. She presented with history of 8 ½ month amenorrhoea and cough on and off with respiratory distress. She had a history of thymectomy done about 9 years back and was on regular treatment with Tablet Pyridostigmine 60 mg TDS. According to the classification of Myasthenia Gravis Foundation of American Clinical Classification, she was categorized to have type IIB myasthenia gravis with ocular and respiratory muscle involvement. She had history of frequent episodes of respiratory distress for which she had been admitted multiple times to the hospital. Patient was on regular antenatal checkup. Considering her respiratory problem due to myasthenia gravis and chronic gastro oesophageal reflux disease, patient was planned for elective caesarean section . However the evening before the planned date of surgery the patient had premature rupture of membranes for which she was taken up as an emergency case. The patient was classified as ASA grade III E physical status and an informed consent was obtained. The patient was shifted to the operation theater in left lateral position on oxygen mask. Venous access was established with 18 gauge I/V cannula and urinary catheterisation was done. O₂ was continued by face mask at a flow rate of 5L /min. Monitoring included NIBP, SpO₂, ECG .With full aseptic precautions subarachnoid block was instituted by 25 gauge Quincke spinal needle and 2.2 ml of 0.5% bupivacaine was injected. Patient was made supine and a 15° wedge was put under the right gluteal region. Desired level of block in caesarean section is upto the T4 dermatome but we deliberately achieved the level upto T6 taking into consideration the patients present respiratory distress and history of frequent complaints of respiratory muscular weakness. Intraoperatively the vitals were stable. However after about 20 minutes of spinal anaesthesia patient complained of respiratory difficulty and the SpO₂ dropped to 93%. O₂ flow was increased to 8L / min and the patient was propped up. Baby was delivered 10 mins after the skin incision . Baby was immediately handed over to the paediatrician . Baby had a weak cry, with little muscle flexion & irregular respiration. One and 5 minute Apgar score was 6, 7 respectively. IPPV & oxygen supplementation was done by ambu mask. Baby was shifted to NICU & was kept on continuous oxygen with the help of oxygen hood . Arterial blood gas analysis showed pH-7.42 ,PaO₂-54 , PaCo₂-42.

Mother was shifted to post anaesthesia care unit where NIBP, Spo₂, and ECG monitoring was continued. Mother was constantly observed for respiration, swallowing and speech to detect any evidence of further skeletal muscle weakness. Patient was kept in propped up position and Injection Diclofenac 75 mgs 8 hrly was used for post operative analgesia.

After 8 -12 hours the newborn was assessed according to Scanlon Early Neonatal Neurobehavioural Scale (ENNS)[1]. The score was 11. The baby still had weak cry, facial weakness and difficulty in breathing and feeding. Oxygen support was continued and frequent suctioning of oral cavity was done. ABG analysis and early neonatal scoring was done daily and baby was assessed accordingly. Subsequent ENNS score are depicted in graphical form.(Fig. 1) The scores improved gradually and on the day 15 the ENNS score was 18. ABG analysis on day 15 showed pH -7.40, PaO₂-70, Paco₂-40. The neurologist decided to discharge the baby thereafter.

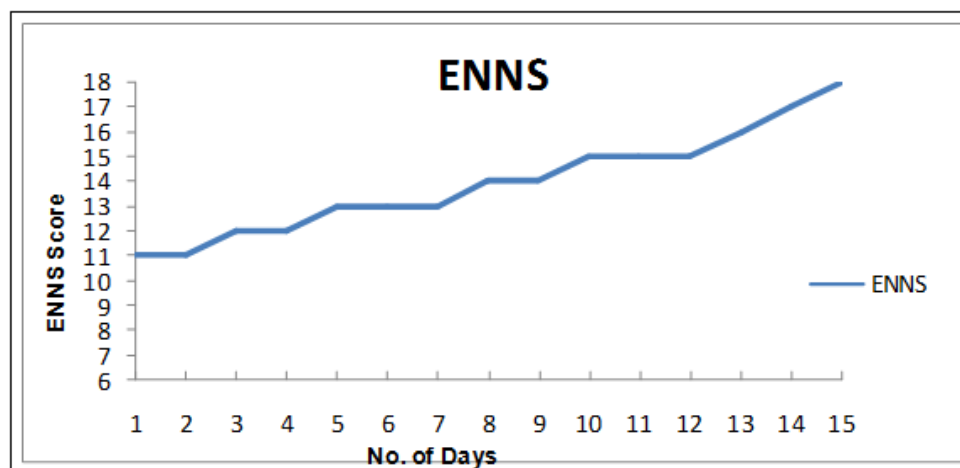


Figure 1- Showing the ENNS Score of the new born in the first fifteen days after birth.

III. DISCUSSION

Myasthenia gravis is an autoimmune disorder in which weakness is caused by circulating antibodies that block acetylcholine receptors at postsynaptic neuromuscular junction [2]. An estimated 70- 80% of functional acetylcholine receptors are lost, explaining the early exhaustion of these patients and marked sensitivity to non depolarising muscle relaxants. Women 20-30 years of age are most often affected, whereas men affected are often older than 60 years of age [3].

The hallmark of this disease is weakness and rapid exhaustion of voluntary skeletal muscles with repetitive use. Ocular, pharyngeal and laryngeal muscles are especially vulnerable as reflected by the appearance of ptosis, diplopia and dysphagia [3]. In most cases the first noticeable symptom is weakness of eye muscles. In others difficulty in swallowing & slurred speech may be the first sign. In myasthenic crises paralysis of respiratory muscles occurs, necessitating assisted ventilation. The crises may be triggered by any of the factors like infection, fever, pregnancy, an adverse drug reaction or emotional stress [4].

Abnormalities of thymus is seen in 75% of cases of myasthenia gravis. Thymectomy is indicated for thymomas & is advised in all young myasthenics who do not respond well to anticholinesterase drugs [5,6]. It is beneficial if done prior to pregnancy as was the case with our patient [7,8]. Complete remission of the disease has been described in approximately 45% of thymectomised patients and clinical improvement may not be noted until years after surgery. Therefore an operative therapy can be postponed until after delivery, since a delay does not adversely affect patients outcome [9,10].

The clinical course of myasthenia gravis and its effect on pregnancy outcome is unpredictable. In a review, Plausche et al noted improvement in 29%, exacerbation in 40% & no change in disease pattern in 31% patients [11]. Worsening of symptoms can occur at any stage during pregnancy, more likely during first trimester and first month postpartum. Studies depict improvement in 20 -40% of patients in 2nd and 3rd trimester. The clinical course of myasthenia gravis throughout first pregnancy does not predict the clinical course in subsequent pregnancies [12,13].

It is recommended that anticholinesterase therapy be continued throughout the period of pregnancy. It aims to improve neuromuscular transmission, suppress the immune system & decrease the circulating antibodies [14]. Though safe, the dose of corticosteroids should be reduced to the lowest possible level to enhance wound healing and minimise the risk of infection [3]. Plasmapheresis can be safely done throughout pregnancy especially when a short term benefit is needed. It has been recommended as preoperative preparation for any myasthenia gravis patient with a vital capacity of < 2L. After plasmapheresis caution should be used in administration of drugs metabolised by plasma cholinesterase such as

succinylcholine, mivacurium, remifentanyl [3]. Use of Immunoglobulins in pregnancy is still experimental but seems to be effective and safe therapeutic approach [15].

Although the precipitating factors of myasthenia crisis like emotional stress, physical exertion and fatigue are inseparable with labour, still vaginal delivery is preferred [12,16]. In our case caesarean section was planned considering her respiratory problems and also the premature rupture of membranes.

Perioperative management of such patients should include evaluation of extent of myasthenia gravis, determination of the severity of myasthenia attacks and optimisation of medical therapy. In severe cases PFT and ECG should be required. Anaesthetic management should be focussed to manage complications arising because of associated disease, anticholinesterase drugs, plasmapheresis and the effect of labour itself. Myasthenic patients having respiratory and bulbar involvement are more prone to develop respiratory depression with IV opioids. Ester local anaesthetics are not recommended for regional anaesthesia as they are minimally metabolised due to decrease in plasma cholinesterase activity [17,18].

Both regional and general anaesthesia have been described by various workers of caesarean section. In patients having bulbar and respiratory involvement general anaesthesia is more appropriate. Regional anaesthesia is better choice in ocular and well controlled generalised disease. Central neuraxial blockade in the form of spinal is preferable over epidural as systemic absorption of the greater quantity of local anaesthetic needed in epidural block can itself result in muscle weakness [17,18].

In our patient although we intended to block upto T6 dermatome still patient developed respiratory difficulty nearly 20 minutes after spinal anaesthesia . This showed that even at T6 level accessory respiratory muscles can get involved in this type of patients.

Fifteen to 20% of neonates born to myasthenic mothers develop transient myasthenia, due to protective effects of alpha foetoprotein, which inhibits binding of anti-acetylcholine receptor antibody to acetylcholine receptor. Signs are usually present at birth, but occasionally may be delayed for 12- 48 hr. Maternal anti-acetylcholine receptor antibody can cross via breast milk and accentuate neonatal myasthenia. Commonly associated features include difficulty in sucking and swallowing, difficulty with breathing, weak infant cry, ptosis and facial weakness. The most likely explanation of neonatal myasthenia is the passage of AChR antibodies across the placenta, but no correlation has been found between the presence or degree of neonatal myasthenia and the concentration of the antibodies in the infant's serum.

The condition has a tendency to spontaneous remission, usually within two to four weeks, and once therapy has been tapered and stopped there is no risk of relapse.

Treatment of transient neonatal myasthenia includes respiratory support when needed and suction to remove built up secretions. In severely affected infants, treatment should be commenced immediately by anticholinesterase inhibitors. In our case, the baby required oxygen supplementation only and gradually improved over a period of 2 weeks after birth. Although there are no relapses once complete recovery has occurred, yet the mother was advised to take good care of baby's sucking and crying activity.

REFERENCES

- [1] Cohen SE. Evaluation of the neonate: Shnider, Levinson G, editors. Anaesthesia for obstetrics: 1st Ed Baltimore: Williams and Wilkins, 1981: 370-84.
- [2] Conti-Fine BM, Milani M, Kaminski HJ. Myasthenia gravis: past, present, and future. J. Clin. Invest. 2006; 116(11): 2843-54.
- [3] Drachman DB. Myasthenia gravis. New Engl. J. Med. 1994; 330: 1797-1810
- [4] Bedlack RS, Sanders DB. How to handle myasthenic crisis. Essential steps in patient care. Postgrad Med.2000; 107(4): 211-4
- [5] Rosenbaum RB, Donaldson JO. Peripheral nerve and neuromuscular disorders. Neurol Clin. 1994;12: 461-78.
- [6] Eden RD, Gall SA. Myasthenia gravis and pregnancy: A reappraisal of thymectomy. Obstet Gynecol 1983; 62: 328-33.
- [7] Roth TC, Raths J, Carboni G, Rösler K, Schmid RA. Effect of pregnancy and birth on the course of myasthenia gravis before or after trans-sternal radical thymectomy Eur J Cardiothorac Surg 2006; 29: 231-5.
- [8] To WK, Cheung RT. Neurological disorders in pregnancy. Hong Kong Med. J. 1997; 3: 400-8.
- [9] Rowland JM, Hendrickx AG. Corticosteroid teratogenicity- Advances in Veterinary Science and Comparative Medicine. 1983; 27: 99-128.
- [10] Bever CT, Aquino AV, Penn AS. Prognosis of ocular myasthenia. Annals of Neurology. 1983; 14(5): 516-519.
- [11] Plausche WC. Myasthenia gravis in mothers and their newborns. Clin Obstet Gynaecol. 1991; 34: 82-99.
- [12] Djelmis J, Sostarko M, Mayer D, Ivanisevic M. Myasthenia gravis in pregnancy: report on 69 cases. European Journal of Obstetrics Gynecology and Reproductive Biology. 2002; 104(1): 21-25.
- [13] Batocchi AP, Majolini L, Evoli A, Lino MM, Minisci C, Tonali P. Course and treatment of myasthenia gravis during pregnancy. Neurology. 1999; 52(3): 447-452.
- [14] Krucylak PE, Naunheim LS. Preoperative preparation and anaesthetic management of patients with myasthenia gravis. Seminars in Thoracic and Cardiovascular Surgery. 1999; 11: 47-53.
- [15] Ellison J, Thomson AJ, Walker ID, Greer IA. Thrombocytopenia and leucopenia precipitated by pregnancy in a woman with myasthenia gravis. British Journal of Obstetrics and Gynaecology 2000; 107(8): 1052-1054.
- [16] Klehmet J, Dudenhausen J, Meisel A, Course and treatment of myasthenia gravis during pregnancy, Nervenarzt 2010; 81: 956-962.
- [17] Rolbin WH, Levinson G, Schnider SM, Wright RG. Anesthetic considerations for MG and pregnancy. Anesth Analg 1978; 57: 441-7.
- [18] D' Angelo R, Gerancher JC. Combined spinal and epidural analgesia in a parturient with severe MG. Reg Anesth Pain Med 1998; 23: 201-3.