

Monostotic Fibrous Dysplasia and Ichthyosis Vulgaris ----- A Rare Association

Surojit Mondal¹, Aniket Chowdhury², Goutam Bandyopadhyay³

Department of Orthopaedics, B.S.Medical College, West Bengal, India¹

Department of Community Medicine, B.S.Medical College, West Bengal, India²

Department of Pathology, R.G.Kar Medical College, West Bengal, India³

Abstract: Fibrous Dysplasia of bone is an uncommon congenital skeletal disorder that is found equally in both genders and is not inherited. Fibrous Dysplasia is characterized either monostotic or polyostotic, and may occur as a component of McCune Albright Syndrome or the rare Mazabraud Syndrome. Long bones, skull bones and ribs are most commonly affected bones.¹ We present a case of a 18 years old boy having pathological fracture of right shaft femur due to Fibrous Dysplasia associated with Ichthyosis Vulgaris. Clinicoradiological examination further established our diagnosis. Biopsy stated delicate trabeculae of immature bone, with no osteoblastic rimming, enmeshed within a bland fibrous stroma of dysplastic spindle shaped cells without any cellular features of malignancy.

Keywords: Fibrous Dysplasia, Ichthyosis Vulgaris.

I. Introduction:

Fibrous Dysplasia is a benign bone tumour that has been linked to a localized developmental arrest; all of the components of the normal bone are present, but they do not differentiate into their mature structures. The lesions appear in three distinctive but sometimes overlapping clinical patterns: (1) Involvement of single bone (monostotic): (2) Involvement of multiple, but never all, bones (polyostotic): and (3) Polyostotic disease, associated with cafe-au-lait skin pigmentation and endocrine abnormalities, especially precocious puberty. The skeletal, skin and endocrine lesion result from a somatic (non hereditary) mutation occurring during embryogenesis that involves the gene that codes for a G-protein.²

Monostotic fibrous dysplasia accounts for 70% of all cases. It occurs equally in boys and girls usually in early adolescents and often stops growing at the time of growth plate closure. The ribs, femur, tibia, jaw bones, calvaria, and humerus are most commonly affected in descending order of frequency. The lesion is asymptomatic and it's usually discovered incidentally. Monostotic disease does not evolve into polyostotic form.²

The initial classic sign is usually painless enlargement of affected bones. Other signs and symptoms include bone pain and bone deformities. Malignant transformation is usually rare and is usually precipitated by radiation therapy.³⁻⁵

Ichthyoses are a group of disorder of cornification which may be inherited or acquired. The inherited form of the disease usually presents in infancy and persists throughout the life. The inherited ichthyosis includes ichthyosis vulgaris, recessive x-linked ichthyosis, autosomal recessive congenital ichthyosis (ARCI), congenital bullous ichthyosiform erythroderma (CBIE), and syndromic forms of ichthyosis. Syndromic ichthyosis is associated with extracutaneous features, Netherton's syndrome, Refsum's disease, Chanarin-Dorfman Syndrome and Sjogren-Larsson Syndrome.⁶ Till date association between fibrous dysplasia and ichthyosis vulgaris is seldom published.

II. Case Report:

A 18 years old boy, product of consanguineous marriage, 2nd in birth order with no normal sibs and death of older sib presented with limping gait, skeletal deformity and pigmented scale over whole body. There was no history of colloidian membrane (elder sib was a colloidian baby); patient bright red in colour at birth, developed blister during the neonatal period, which progress for 9-10 years. Erythroderma appeared at the site of friction leading to erosion, peeling and widespread areas of denuded skin without any scarring. Later on skin became thick and scaly with pungent body odour after gradual subsidence of erythroderma. (Fig: 3) There was generalized involvement with sparing of hair, teeth, oral mucosa. Palm and soles had deep creases and hyperkeratotic lesions. Patient had a severe skeletal deformity in the form of symmetrical Genu varus, bowed femur, flexion contracture of both knee, hypo plastic trochlear notch of femur, hypo plastic patella and recurrent subluxation of patella with generalized ligamentous laxity.(Fig : 4) On examination a pathological fracture was noted at lower third of right shaft of femur and dermatological examination revealed thick waxy scales present

throughout the body except scalp, palm and soles (Where there were hyperkeratotic deep creases). No clinically significant findings were noted on examination of other alive members.

Baseline routine investigations are within normal limits. Ca^{2+} , PO_4^{2-} , Alkaline Phosphatase, Parathormone, 25-Hydroxy Vit D levels were normal. Radiographs showed pathological fracture of lower third of left shaft femur. Skiagram of Right Femur also shows mottled radio-opaque pattern resembling as ground-glass with ill-defined border blending into normal adjacent bone with typical 'Shepherd crook deformity'. Skiagram of other common sites in descending order of frequency- Femur of other side, skull, tibia, humerus, ribs, fibula, radius, ulna, mandible and vertebra were normal. CT scan further establishes the diagnosis of Fibrous Dysplasia and excludes Osteopetrosis and Osteogenesis imperfecta.

The key histologic features of fibrous dysplasia are delicate trabeculae of immature bone, with no osteoblastic rimming, enmeshed within a bland fibrous stroma of dysplastic spindle shaped cells without any cellular features of malignancy (Fig.1 & 2). The ratio of fibrous tissue to bone ranges from fields that are totally fibrous to those filled with dysplastic trabeculae. Examination of macro sections of intact lesions reveals the margins of the lesion to be separated from surrounding bone by a thin shell of mature lamellar reactive bone. The overall impression is of a variable number of immature, non-stress oriented, disconnected dysplastic trabeculae floating in a sea of immature mesenchymal cells that have little or no collagen about them. The pattern of the bizarrely shaped trabeculae has been likened to "alphabet soup." The mesenchymal stroma surrounding the dysplastic trabeculae is relatively hypocellular and is composed of spindle-shaped primitive mesenchymal cells that produce little or no collagenous fibrils. There is a characteristic absence of plump osteoblasts rimming the isolated immature trabeculae, which often have abnormally thick seams of osteoid, similar to those seen in osteomalacia (Figs. 1 & 2). These trabeculae, which fail to undergo remodeling, seldom contain cement lines. Multiple delicate capillaries are found throughout the lesion and, when injured, incite a giant-cell reactive process. Lobules of cartilage are infrequently seen and, when present, are composed of mature hyaline cartilage.

III. Discussion:

Fibrous Dysplasia is a skeletal developmental anomaly of the bone forming mesenchyme that manifests as a defect in osteoblastic differentiation and maturation, leading to a replacement of medullary bone by a fibrous tissue. It is a non-hereditary disorder of unknown cause and can affect virtually any bone in the body.⁷ The initial manifestations are most common in the 3-15 year age group, but the disease can manifest any time upto 70 years of age.⁸

In our patient the bone pathology first came to our observation at age of 18, when the boy presented to our clinic with pathological fracture lower third shaft of Right Femur, long time after the onset of skin lesions, which was present from the neonatal period.

Autosomal co-dominant Ichthyosis vulgaris usually appears within first year of life. Pruritus, palmar and plantar hyper-linearity, atopic dermatitis, and keratosis pilaris are often seen in Ichthyosis vulgaris. The cause of the disease is Filaggrin gene mutation.⁹⁻¹⁰

Our patient was bright red in colour at birth, developed blisters during the neonatal period which progressed for 9-10 years. Erythroderma appeared at the site of friction leading to erosion, peeling and widespread areas of denuded skin without any scarring. . Later on skin became thick and scaly with pungent body odour after gradual subsidence of erythroderma.(Fig: 3)

Skiagram of the Right shaft femur showed a mottled radio-opaque patterns resembling ground-glass, with ill-defined borders blending into normal adjacent bones with pathological fractures of lower third of right shaft femur.

Furthermore, CT scan established the diagnosis of Fibrous Dysplasia whereas excluding Osteogenesis Imperfecta, Osteopetrosis. Patient was planned for elective surgery after routine baseline investigations were within normal limits. Patient was treated with Open Reduction and Internal Fixation with contoured reconstruction plate and screw construct. During the procedure of internal fixation there was multiple unusual bleeders, which represent increased concentration of small vessels characteristic of Fibrous Dysplasia. After securing haemostasis and taking bone specimen (for biopsy) from fracture site, the wound was closed conventionally. HPE examination of the bone taken from pathological fracture site shows characteristic absence of plump osteoblasts rimming the isolated immature trabeculae. The pattern of the bizarrely shaped trabeculae has been likened to "alphabet soup." Multiple delicate capillaries are found throughout the lesion and, when injured, incite a giant-cell reactive process. Lobules when present, are composed of mature hyaline cartilage. Dermatological lesions were treated with Acetretin (35mg/day) and topical emollients. Patient is still under follow-up. Surgical wound healed normally, but patient is suffering from problem in weight-bearing of affected leg due to recurrent patellar subluxation.

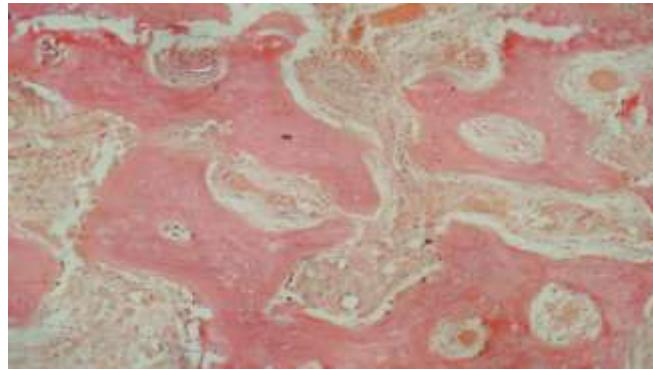


Fig: 1 Showing Fibrous Dysplasia with bony trabeculae not associated with osteoblastic rimming (hematoxylin and eosin, 100 \times).

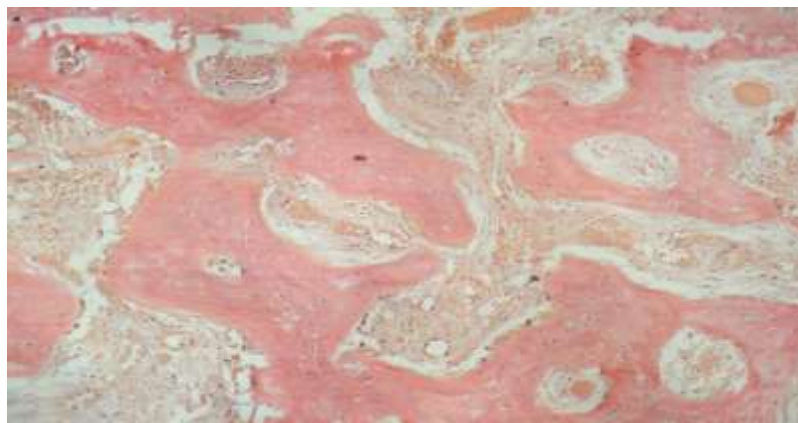


Fig 2 Showing Fibrous Dysplasia(hematoxylin and eosin, 400 \times)zqA

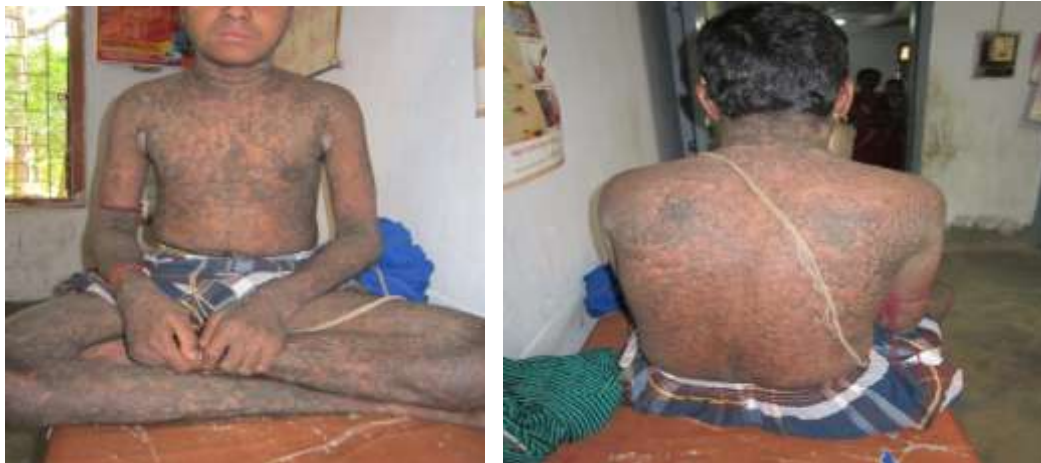

Fig:3 Showing thick waxy scaly skin of Ichthyosis Vulgaris



Fig: 4 Showing Hyperlaxity of the metacarpo-phalangeal & proximal inter-phalangeal joints.

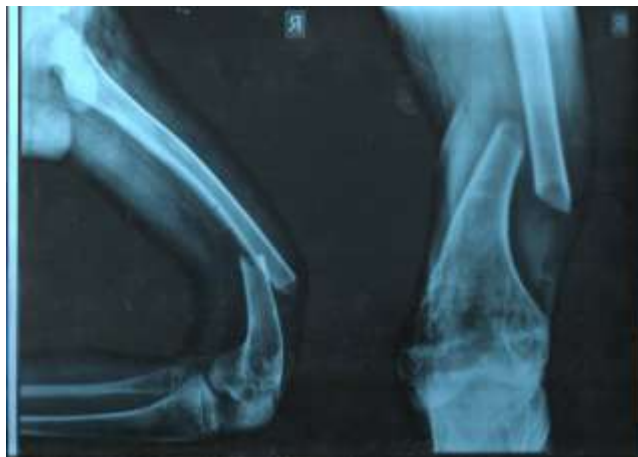

Fig: 5 Pathological fracture of Rt. shaft femur.

References:

- [1] Mohan H, Mittal P, Mundi I, Kumar S. Fibrous Dysplasia of bone : a clinicopathological review. *Dove Press Journal Pathology and Laboratory Medicine International*: 2011; 3:31-42.
- [2] Weinstein LS, Chen M, Lin J: Gs (α) mutations and imprinting defects in human disease. *Ann NY Acad Sci* 968:173, 2002.
- [3] Feller L, Wood NH, Khammissa R, Lemmar J, Raubenheimer EJ. The nature of Fibrous Dysplasia. *Head Face Med* 2009; 5:22.
- [4] Riminucci M, Saggio I, Robey PG, Bianco P. Fibrous Dysplasia as a stem cell disease. *J-Bone Miner Res*.2006; 21.suppl 2: P125-P131.
- [5] Ogunsaini CO, Lewis A, Danqueh L. Benign fibroosseous lesions of the jaw bones in Jamaica: analysis of 32 cases. *Oral Dis* 2001; 7(3):155-62.
- [6] George R, Srivastava MV: *Genodermatoses and Naevi*; IADVL's Concise Textbook of Dermatology: Chapter 29, Pg-328.
- [7] Anand MKN. Fibrous Dysplasia. *E-medicine.com* 2004. Section 1 to 12.
- [8] Harris WH, Dudy HR Jr, Barry RJ. The Natural History of Fibrous Dysplasia. *J Bone Joint Sur AM* 1962; 44:207.
- [9] Krug M, Oji V, Traupe H, Berneburg M. Ichthyoses – Part 1: Differential diagnosis of vulgar ichthyoses and therapeutic options. *JDDG* 2009; 7: 511–519. PMID: 19192163.
- [10] Oji V, Traupe H. Ichthyoses: differential diagnosis and molecular genetics. *Eur J Dermatol* 2006; 16: 349-359. PMID: 16935789