

The Histological Spectrum of Myxoma, Myxofibroma /Fibromyxoma and Odontogenic Fibroma- “A Chicken And Egg Situation”

¹Dr. Monica Mehendiratta, ²Dr. Shweta Rehani, ³Dr. Monica C Solomon

¹Senior Lecturer, ²Reader, Dept. of Oral and maxillofacial pathology, Sudha Rustagi Dental College and Research Institute, Haryana, India.

³Professor, Dept. of Oral and maxillofacial pathology, Manipal College of Dental Sciences, Manipal, Karnataka, India.

Abstract: The spectrum of odontogenic fibroma, fibromyxoma/myxofibroma and myxoma represents a histogenetically related but behaviourally distinct heterogenous group of benign mesenchymal neoplasms. The terminologies myxofibromas/ fibromyxomas have been used histologically in the literature in a contradictory way either synonymously to myxomas or to designate simple odontogenic fibromas/ fibromas undergoing myxomatous degeneration. This article is shedding light on the importance of these disputed terminologies and emphasizes on the required distinctions pertaining to the clinical relevance of the same along with a case-report of a clinically soft to fibrous lesion with a histological diagnosis of peripheral odontogenic myxofibroma in a 33years-old male patient.

Key Words: Fibroma, Fibromyxoma, Myxofibroma, Myxoma, Odontogenic, Terminologies.

I. Introduction:

The odontogenic fibroma is defined by WHO as a benign odontogenic neoplasm of fibroblastic origin characterized by relatively mature collagenous fibrous tissue and varying amounts of odontogenic epithelium with potential to occur either in a central or extraosseous location.¹ The histopathology of the peripheral odontogenic fibroma (POF) is similar to central odontogenic fibroma (COF) - WHO type and is seen only in the teeth bearing areas.^{2,3} Microscopically, it shows collagenous background containing inactive odontogenic rests and/or mineralized tissue. It can also show some myxomatous stroma in its collagenous background and can undergo myxomatous degeneration as well. This has led to its designation as fibromyxoma which is actually considered to be a different odontogenic tumor of ectomesenchymal origin.²

As described by WHO, the central odontogenic myxoma (synonymously used myxofibroma/fibromyxoma) is a locally invasive neoplasm consisting of rounded and angular cells that lie in an abundant mucoid stream.⁴ Both central and peripheral odontogenic myxomas are histologically similar but peripheral counterpart is less aggressive, usually encapsulated or circumscribed.^{5, 6} When a relatively greater amount of collagen is evident in a myxoma, the term myxofibroma or fibromyxoma is used.⁷

No separate consideration has been given to these more collagenized variants, although some investigators have suggested that these may represent part of a spectrum that includes the central odontogenic fibroma at the other endpoint of central odontogenic myxomas.²

The article discusses some issues on the clinical significance of the terminologies being used as myxoma, myxofibroma/ fibromyxoma and fibroma along with a case report on a rare peripheral odontogenic fibromyxoma.

II. Case Report

A 33 year old male patient reported to the Department of Oral Medicine and Radiology of Sudha Rustagi College of dental science and research, Faridabad with a tender and exophytic growth. The lesion was soft to firm in consistency on palpation and represented well delimited growth in the right lateral incisor-canine mandibular region, extending from the mesial aspect of 43 to distal of 44 of five years duration.

History revealed a soft, reddish, small growth initially, which grew to the present size and become firmer (Figure 1). Based on the clinical features a provisional diagnosis of fibroma was made. The radiograph revealed an ill-defined and non-diagnostic, radiolucent shadow wrt 43 and 44 (Figure 2).

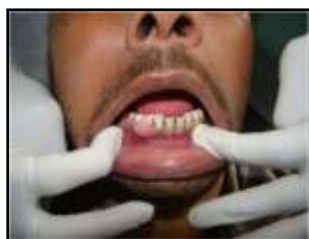

Fig 1. A fibrous growth can be seen in the lateral incisor-canine region.

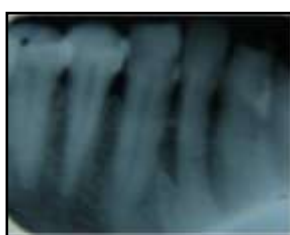

Fig 2. Faint radiolucency in the lateral incisor-canine region.

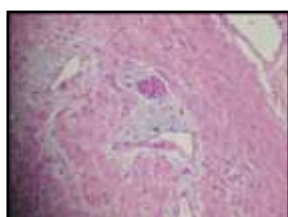

Fig 3. An odontogenic nest can be seen in the myxofibrous stroma.

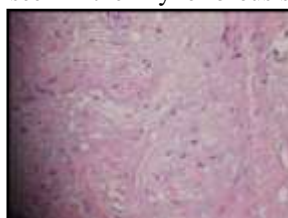


Fig 5. Loosely arranged, less cellular stroma with abundant ground substance.

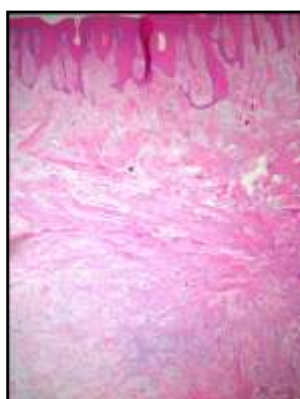


Fig 4. A fibro-myxoid stroma with predominantly myxoid in the deeper connective tissue



Fig 6. Alcianophilic stroma in the deeper connective tissue

Histopathologically, the lesions showed few nests, strands and rests of odontogenic epithelial cells (Figure 3) scattered in a mature fibrous stroma interspersed with few areas of myxomatous tissue. The deeper connective tissue showed predominantly myxomatous tissue (Figure 4) exhibiting relatively less cellular, loosely arranged tissue dominated by an amorphous, irregular ground substance with spindle and stellate-shaped cells (Figure 5). The alcianophilic of the myxoid component is well demonstrated with the alcian blue staining (Figure 6). Keeping all the clinical and histopathological findings in mind, a diagnosis of peripheral odontogenic fibromyxoma was made.

III. Discussion:

The central odontogenic fibroma (COF) has been divided into simple and WHO type. The so-called simple COF have been suggested by some investigators belongs to the spectrum of odontogenic myxoma, and should be designated as a myxofibroma on account of its cellularity and amount of ground substance.² Also, when odontogenic fibroma undergoes myxomatous degeneration, myxofibroma terminologies have been used.⁸ However, detailed description of the POF is lagging even in the recent WHO classification and requires attention. Clinically, POF often presents as solitary, non-capsulated, slowly growing lesion often seen in the lateral incisor-canine region of either jaw. Histopathologically, POF is similar to WHO type-COF consisting of cellular fibrous connective tissue which may be interspersed with areas of less cellular, myxoid substance and containing non-neoplastic vacuolated odontogenic epithelium ranging from scanty to numerous.^{2,9} Odontogenic myxoma are classified as benign tumor of ectomesenchymal origin with/without odontogenic epithelium.² The peripheral myxoma is a rare, slowly growing, benign mesenchymal tumor but potentially infiltrative. It shows less aggressive behavior and lower recurrence rate than its central counterpart. The details available regarding oral peripheral myxoma is less in the English literature.^{10,11}

The histogenesis of myxomatous component of odontogenic and non-odontogenic origin is still obscured and is a subject of debate. This even includes myxoid degeneration which can occur in an originally non-myxoid tumor. The peripheral odontogenic myxomas bear a close microscopic resemblance to the mesenchymal portion of a developing tooth such as dental follicle and papilla and other odontogenic tumours such as ameloblastic fibroma. Thus, the origin of odontogenic myxomas from odontogenic ectomesenchyme

The histological spectrum of myxoma, myxofibroma/fibromyxoma and odontogenic fibroma- "A was put forth.^{2,12} One of the hypotheses of origin is altered/primitive fibroblasts or myofibroblasts producing excess of mucopolysaccharides and was commonly incapable of forming mature collagen even if some cells could retain this capacity.^{6, 12, 13} Even their origin from periodontal tissue has also been suggested.¹⁴

Thus, in the spectrum of odontogenic myxoma-myxofibroma-fibroma, the histological similarities between myxomas and COF simple type have led to the disputed hypothesis that the latter entity would merely represent the formers most collagenous variant of the histological spectrum called as myxofibroma.¹⁵ The consideration of the clinical history of rapid growth with invasive behavior, radiographic features, young age, and association with the surgical aspect of a gelatinous tissue in myxomas when compared to the COF can help distinguish the two.¹⁶ The histological abundance of collagen and greater cellularity also favors the diagnosis of COF.⁴

Now the question arises, what came first "Hen or egg?" This statement is analogous to the so-called spectrum of "Myxoma-myxofibroma-fibroma", although they are histogenetically interrelated; the direction of movement has a clinical relevance. If the myxoma and fibroma are the two ends of spectrum; what is the direction of progression whether "fibroma turns myxoma" or "myxoma turns fibroma"? Or is it myxomatous degeneration happening inside the odontogenic fibroma?

The clinical importance of the distinction of odontogenic myxomas and fibromas is understandable but the behavior of myxofibroma does remain unanswered. Also, the amount of myxomatous tissue in the present case is high in the depth of the lesion, does it call for a classification of POF into Simple and WHO-type or is it myxomatous degeneration occurring and is it a myxofibroma or Simple type-POF?

IV. Conclusion and Summary:

Although the clinical aggressiveness of peripheral odontogenic myxoma or fibroma is known to be lesser when compared to their central odontogenic counterpart but the article discusses both peripheral and central lesions. Unlike odontogenic fibromas, odontogenic myxomas are infiltrative in nature and exhibit rapid growth. Thus, it is important to know their (both central and peripheral) respective histopathology which in turn would determine the clinical course. Here a 'circular reference' condition is created by the term "Myxofibroma" by being a type of myxoma or fibroma, or formed by myxomatous degeneration of a fibroma. The article emphasizes on the need to pay attention the multiple usage of this term keeping the clinical prognosis in mind. It calls for a justified classification of myxofibroma after considering the histological predominance of myxomatous and fibrous tissue in an odontogenic lesion taking into account the pathogenesis and prognosis of the term "myxomatous degeneration" which can be occur in an odontogenic fibroma.

REFERENCES

- [1] Pindborg JJ, Kramer IR, Torloni H. Histological typing of Odontogenic tumors, jaw cysts and allied lesions. International histological classification of tumors No.5. Geneva: World Health Organization; 1971. p. 30-1
- [2] Neville BW, Damn DD, Allen CM, Bouquot EJ. In: Oral and maxillofacial Pathology. 3rd Edition. Saunders Elsevier; 2009.
- [3] Martelli-Junior H, Mesquita RA, de Paula Am, Pego SP, Souza LN. Peripheral odontogenic fibroma (WHO type) of the newborn: a case report. Int J Paediatr Dent. 2006 Sep; 16(5):376-9.
- [4] Brannon RB. Central odontogenic fibroma, myxoma (odontogenic myxoma, fibromyxoma), and central odontogenic granular cell tumor. Oral Maxillofac Surg Clin North Am. 2004; 16: 359-74.
- [5] Lombardi T, Lock C, Samson J, Odel EW. S100, alpha-smooth muscle actin and cytokeratin-19 immunohistochemistry in odontogenic and soft tissue myxomas. J Clin Pathol 1995; 48(8):759-762.
- [6] Barnes, L. (2001) Tumours and tumour-like lesions of the soft tissues. In: Barnes, L. (ed). Surgical Pathology of the Head and Neck, 2nd edition, pp. 952-954. New York: BC Decker.
- [7] A. Buchner, E.W. Odell. Odontogenic myxoma / Myxofibroma. Pathology & Genetics Head and Neck Tumours. Edited by Leon Barnes, John W. Eveson, Peter Reichart, David Sidransky. pp 316.
- [8] Anil Govindrao Ghom. Teeth Anomalies. Anil Govindrao Ghom (ed). Text book of Oral Medicine, 2nd edition. New Delhi, Jaypee Brothers 2010:260.
- [9] Rajendran R, Sivapathasundaram Shafer's Textbook of Oral Pathology. 6th edition. Elsevier; 2009.
- [10] Ramraj PN, Shah SP. Peripheral myxoma of maxilla. A case report. Indian J Dent Res. 2003; 14(1):67-9.
- [11] Aytac-Yazicioglu D, Eren H, Gorgun S. Peripheral odontogenic myxoma located on the maxillary gingiva: report of a case and review of the literature. Oral Maxillofac Surg. 2008 Sep; 12(3):167-71.
- [12] Adekeye EO, Avery BS, Edwards MB, Williams HK. Advanced central myxoma of the jaws in Nigeria. Clinical features, treatment and pathogenesis. Int J Oral Surg 1984; 13:177-86.
- [13] Lucas RB. Tumours of Fibrous Connective Tissue, In Pathology of Tumours of the Oral Tissues. 4th Ed, New York. Churchill Livingstone 1984: 165-68.
- [14] Shimoyama T, Horie N, Kato T, Tojo T, Nasu D, Kaneko T et al. Soft tissue myxoma of the gingiva: report of a case and review of the literature of soft tissue myxoma in the oral region. J Oral Sci. 2000; 42(2):107-9.
- [15] Philipsen HP, Reichart PA, Sciubba JJ, van der Waal: Odontogenic fibroma. In World Health Organization Classification of tumours. Pathology and genetics of Head and neck tumors. Edited by Barnes L, Eveson JW, Reichart P, Sidransky D. Lyon: IARC Press; 2005:315-318.
- [16] Rocha AC, Gaujac C, Ceccheti MM, Amato-Filho G, Machado GG. Treatment of recurrent myxoma by curettage and cryotherapy after thirty years. Clinics (Sao Paulo) 2009, 64(Suppl 2):149-152.