

Breast Border Extraction & Pectoral Muscle Detection using RGB pixel-wise clustering.

Farag H. Alhsnony¹, TawfikEzatTawfik², Mohamed S. M. Geoda³

¹(Electrical Engineering Department, National Board for Technical & Vocational Education
"The Higher Institute Of Science And Technology", TOBRUK- LIBYA)

^{2,3}(Computer Technologies Department, National Board for Technical & Vocational Education
"The Higher Institute Of Science And Technology", TOBRUK- LIBYA)

Abstract:

Background: Breast cancer can be cured if diagnosed early, with digital mammography which is one of the most effective imaging modalities for early breast cancer detection. However mammogram images often come with low contrast, high background noises and artifacts, all these things making diagnosis difficult. The purpose of this paper is to preprocess digital mammogram images to improve results with a computer aided diagnosis (CAD) system. In this paper we have proposed three distinct methods: image processing to removing unwanted objects method;

a breast border detection and segmentation method; and a pectoral muscle detection and suppression method.

Materials and Methods: The presented method in this paper applied image contour extraction technique by computer technology in mammogram images to find and extraction the breast border and pectoral muscle automatically. The proposed algorithms were extensively applied on more than 200 mammogram images in (MIAS) database resulting in complete pectoral muscle removing in most of the images. In this proposed the algorithm is compared with other segmentation methods showing good results in comparison.

Results: The proposed techniques are tested with the Mini MIAS dataset by Matlab simulation program, this technique is applied to extract the breast border to many type of tissues of mammograms and achieved in general 96 % segmentation accuracy. Also applied same technique to extraction and suppression the pectoral muscle and achieved 93 % extraction accuracy.

Conclusion: The proposed methods were extensively applied on more than 100 mammogram images in MIAS database resulting in complete pectoral muscle detection and suppression in most of the images also applied this technique to find the breast border.

Key Word: Mammogram images, Breast Border, Pectoral Muscle, Segmentation, Breast Contour.

Date of Submission: 06-01-2021

Date of Acceptance: 21-01-2021

I. Introduction

Cancer is a group of diseases that cause cells in the body to change and grow out of control. Most types of cancer cells eventually form a lump or masses called a tumor, and are named after the part of the body where the tumor originates. Breast cancer begins in breast tissue, which is made up of glands for milk production, called lobules, and the ducts that connect lobules to the nipple. The remainder of the breast is made up of fatty, connective, and lymphatic tissue¹.

Breast cancer is a leading cause of cancer deaths among women. For women in US and other developed countries, it is the most frequently diagnosed cancer. About 2100 new cases of breast cancer and 800 deaths are registered each year in Norway². The incidence of breast cancer is rapidly increasing in the Asia Pacific regions³. In India, breast cancer accounts for 23% of all the female cancer death followed by cervical cancer (17.5%) in India. Although the incidence is lower in India than in the developed countries, the burden of diagnosing and treating of breast cancer in India is alarming⁴.

Abnormal mass growth in breast can be detected by screening mammograms as a first line testing tool. Digital mammography is the most effective imaging modality for early detection of breast cancer. In most of the advanced country screening mammogram has become a mandate for women after a certain age as a routine checkup. Increasing the population cases of mammograms has increased highly over time in comparison to constant number of available radiologists. This has resulted in a highly skewed patient: radiologist ratio. The burden of screening hundreds more mammogram images has fallen on the radiologists. Added to this problem, digital mammogram images often contain noise, low contrast and artifacts making it difficult for the radiologists to make a decision and timely judgment about appropriate diagnosis.

In these challenges a computer aided tool for analyzing mammograms could be highly helpful. Consequently the diagnosis is more accurate if a better quality image is provided.

In this proposal basically focusing on breast border detection and extraction and pectoral muscle suppression. In the first stage of this paper a preprocessing technique is proposed for removing unwanted objects in a mammogram image , the second stage in this paper a breast border extraction is proposed to segment the breast area from the image background. Breast border extraction is an important for any CAD system. Segmenting the breast area accurately from the image background limits the search area for the localization of masses or micro-calcifications, hence increasing the chances of improved detection.

And lastly an automated segmentation technique to detection and remove the pectoral muscle is applied as the intensity range of pectoral muscle is very similar to as that of masses. The objective of this research work is to produce better preprocessed mammogram images for input to a Computer Aided Diagnosis (CAD) system, which would eventually radiologists assist in better diagnosis.

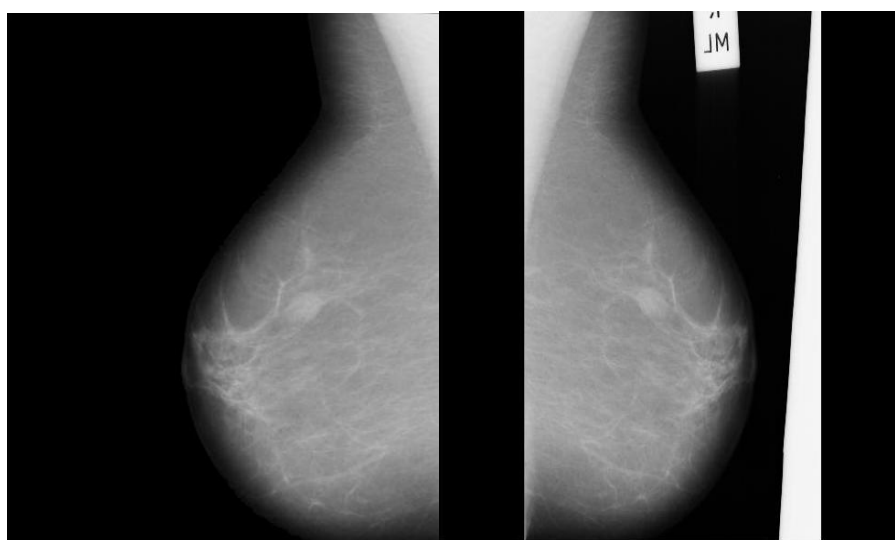
II. Material And Methods

The proposed preprocessing techniques were tested on the digital mammogram images collected from popular publicly available MIAS dataset ⁵. Digital mammogram images are medical images that are difficult to be explicated, thus a preparation phase is important in order to improve the mammogram image quality and make the segmentation results more clarity and accurate, thus, the scheme in this paper is involved four steps: (I) pre-processing and enhancement (II) breast segmentation (III) detection of the breast border; and (IV) detection of the pectoral muscle. In these steps used some of techniques as : convert the mammogram image (gray image) into binary image , also used technique to convert the original image in to RGB (color image) with multi levels.

I. Pre-preprocessing and enhancement

The main objective of this process is to improve the quality of the image to make it ready to other processing by removing the noise and unwanted parts in the background of the mammogram image. In this paper, used a technique for pre-preprocessing and enhancement to improve the detection of the suspicious regions in a mammogram image. The pre-preprocessing and enhancement method consists of two processing steps; first, the removal of film artifacts such as labels and X-ray marks are removed from the mammogram image for helping physicians to better diagnose.

Second, scanning the image to find the chest wall and unify the orientation of the breast body in one direction (always to the left direction or pectoral muscle, is on the upper left corner of the image). Determine the orientation of the breast ,It is important objective for beginning to searching in image with knowing the chest wall or breast border orientations. This section is based on the technique of converting the image to binary image for scanning each pixel one by one in all digital mammogram image. Scanning the image horizontal and vertical to search for impurities and artifacts as labels and X-ray marks, moreover scanning to find orientation of the breast body and fixed the orientation breast body to left side.



(a) (b)

Figure1:preprocessing method to make the image orientation always left ,
(a): Original image , (b):The mammogram after preprocessing technique.

III. Breast Segmentations:

Previous work from many authors used mammography image databases, specially MIAS⁵ and DDSM⁶, both comprised of scanned and digitized SFM images. First methods for breast border contour detection were manual⁷ and semiautomatic⁸. In the manual methods segmentation is done by a selecting device, like computer mouse, so those methods probably cannot be treated as something that is considered to be segmentation today. Among fully automatic methods, gray level thresholding or histogram based methods are dominant^{9,10}. Some different approaches like Polynomial modeling¹¹, Active contours^{12,13}, Classifiers and Wavelet decomposition¹⁴.

The main objective of our study includes a pixel-wise clustering scheme plus post processing to segment the breast boundaries precisely and segment the pectoral muscle area.

IV. Breast Border Segmentation.

Process of breast segmentation is the first step in mammography image analysis. It is basic to find the skin-air interface, or the breast contour, and define the region of interest (ROI) for further analysis

The technique for breast border segmentation proposed in this paper use a pixel-wise clustering technique. Segmentation starts by automatically selecting the desired region The method has two phases : In the first phase searching from right direction for first pixel (color pixels) in the image that representing a breast border pixels (contour of breast border). And second phase register all position breast border points and redrawing in original image with white pixels the region of pectoral muscle as shown the figure.

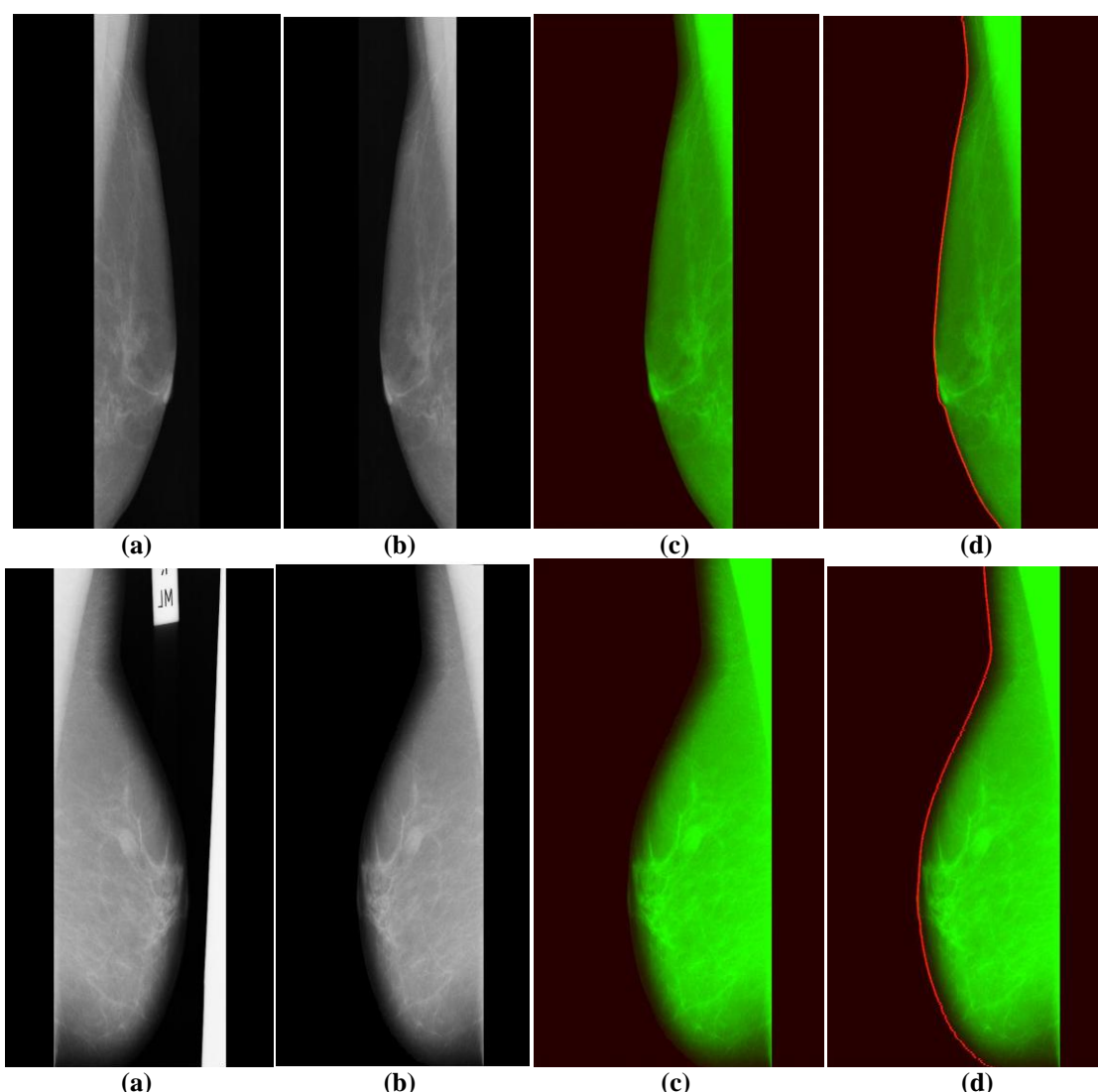


Figure2: shows the stages of the proposal techniques to find the breast border in digital mammogram image
(a): Original image , **(b):**the image after preprocessing technique, **(c):** shows the image after converted to RGB image, **(d):** shows the final stage to drawing the breast border on the image .

V. Pectoral Muscle Segmentation.

The technique for pectoral muscle segmentation proposed in this paper use a pixel-wise clustering technique to detect pectoral muscle. Segmentation starts by automatically selecting the desired region. The region of interest containing pectoral muscle is determined by three phases : In the first phase searching for all pixels (color pixels) in the image with limit value as a color pixels that representing a pectoral muscle pixels (pectoral muscle line). second phase scanning the image from upper left corner in position (1,1) row and column in to lower left corner into end of contour of the breast, third phase register all position of pectoral muscle points and redrawing in original image with white pixels or suppression the region of pectoral muscle as shown the figure.

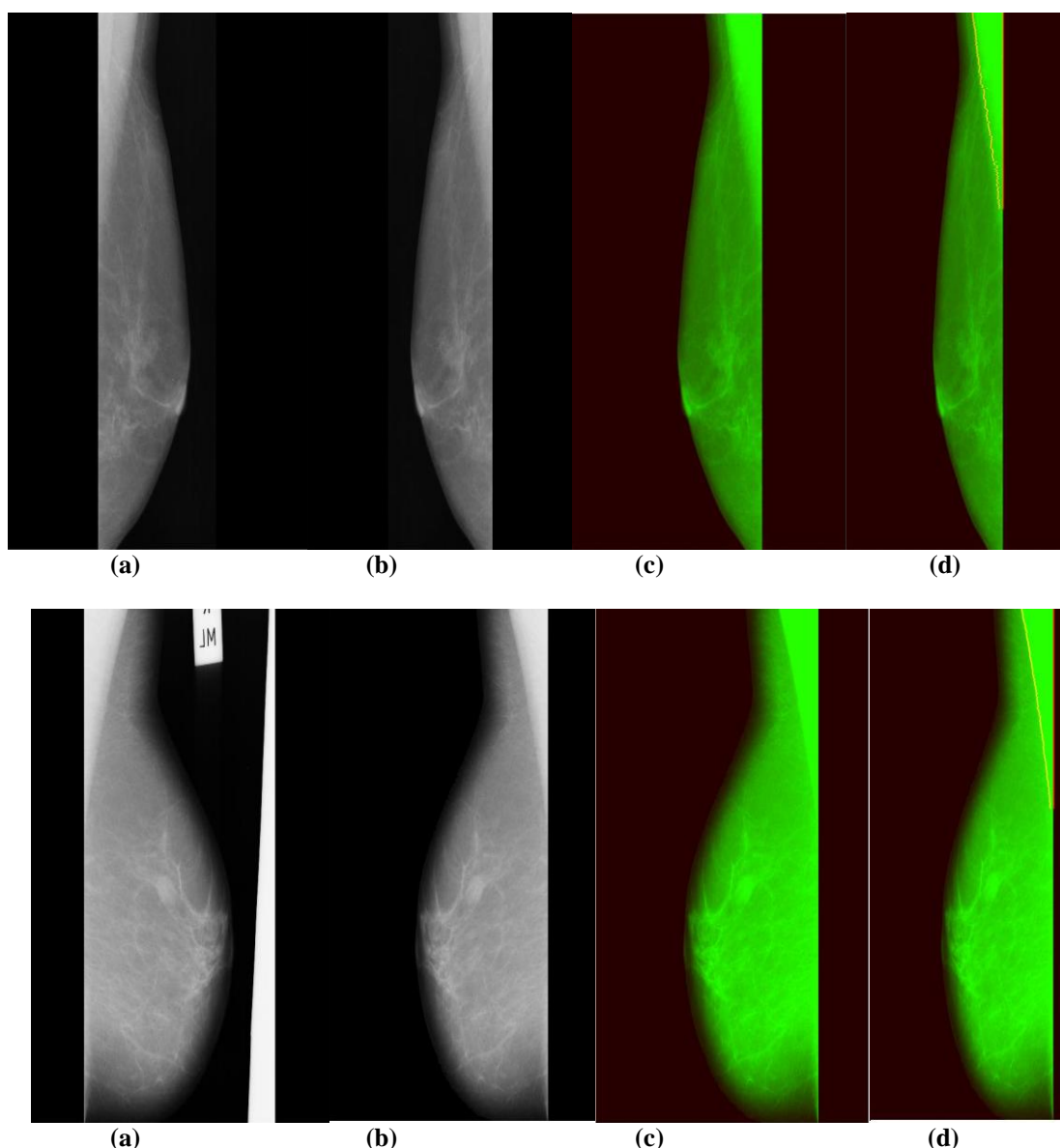


Figure3: shows the stages of the proposal techniques to detect pectoral muscle in digital mammogram image

(a): Original image , (b):the image after preprocessing technique, (c): shows the image after converted to RGB image, (d): shows the final stage to drawing pectoral muscle .

VI. Result & Discussion

The proposed techniques are tested with the Mini MIAS dataset by Matlab simulation program , this technique is applied for breast border extraction to almost 40 fatty mammogram images, almost 40 fatty-glandular images, and more than 40 dense glandular images achieved in general 96 % segmentation accuracy. Also applied same technique to extraction and suppression the pectoral muscle and achieved 93 % extraction accuracy.

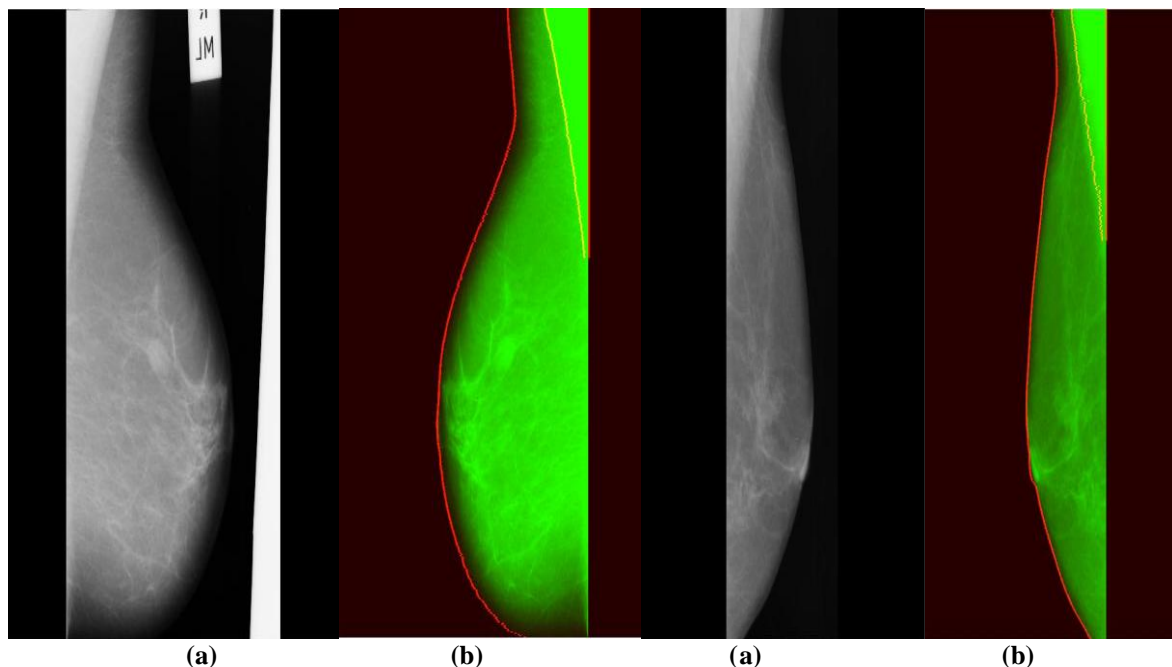


Figure4:Shows the RGB digital mammogram image in final phase to find and draw the breast border and pectoral muscle.(a): Original image , (b):Breast border and pectoral muscle draw in the RGB image.

Table no 1 : Shows breast border extraction and pectoral muscle detection results.

Breast tissues	Extraction accuracy. Breast Border	Extraction accuracy. Pectoral muscle
• fatty mammogram images	98 %	94 %
• fatty-glandular images	93 %	93 %
• dense -glandular images	97 %	92 %
Average results	96 %	93 %

VII. Conclusion

The proposed methods were extensively applied on more than 100 mammogram images in MIAS database resulting in complete pectoral muscle detection and suppression in most of the images also applied this technique to find the breast border.

In this paper, were presented an image processing using RGB wise pixels clustering to processing mammogram images, including a breast border and pectoral muscle detection and segmentation method. Skin-air boundary is firstly detected based on RGB gradient weight, and breast boundary is then finding by scanning the image with applying RGB clustering pixels technique.

Next, breast segmentation is performed in the pixel-wise classification to get the initial boundary between pectoral muscles and breast region based on line detection and curve fitting. Experimental results showed that the proposed automatically method for breast border and pectoral detection and segmentations has higher efficiency.

References

- [1]. Breast Cancer Facts Figures, 2009–2010, American Cancer Society, Inc.
- [2]. J. Norum, Breast cancer screening by mammography in Norway. Is it cost-effective? *Ann. Oncol.* 10 (1999) 197–203.
- [3]. Youlten DR, Cramb SM, Yip CH, Baade PD (2014). Incidence and mortality of female breast cancer in the Asia-Pacific region. *Cancer Biol Med*, 11, 101–15.
- [4]. M.K.J. Siddiqui, M. Anand, P.K. Mehrotr, R. Sarangi, N. Mathur, Biomonitoring of organochlorines in women with benign and malignant breast disease, *Environ. Res.* 1 (2004) 1–8.
- [5]. Suckling J., Parker J., Dance D.R., Astley S., Hutt I., Boggis C.R.M., Ricketts I., Stamatakis E., Cernaes N., Kok S.L., Taylor P., Betal D., Savage J., "The Mammographic Image Analysis Society Digital Mammogram Database", *Proceedings of the 2nd*

- International Workshop on Digital Mammography, York, England, 10–12 July 1994, Elsevier Science, Amsterdam, The Netherlands, pp. 375-378.
- [6]. Heath M., Bowyer K., Kopans D., Moore R., Kegelmeyer P. Jr., "The Digital Database for Screening Mammography", Proceedings of the 5th International Workshop on Digital Mammography, Toronto, Canada, 11-14 June 2000, Medical Physics Publishing, 2001, pp. 212-218.
- [7]. Kallergi M., Woods K., Clarke L.P., Qian W., Clark R.A., "Image Segmentation in Digital Mammography: Comparison of Local Thresholding and Region Growing Algorithms", *Computerized Medical Imaging and Graphics*, 16 (5) (1992), pp. 323-331.
- [8]. Chandrasekhar R., Attikiouzel Y., "Gross Segmentation of Mammograms using a Polynomial Model", Proceedings of the 18th Annual International Conference of the IEEE Engineering in Medicine and Biology Society, Amsterdam, The Netherlands, 31 October - 3 November 1996, pp. 1056-1058.
- [9]. Bick U., Giger M., "Automated Segmentation of Digitized Mammograms", *Academic Radiology*, 2(1995), pp. 1-9.
- [10]. Raba D., Oliver A., Martı́ J., Peracaula M., Espunya J., "Breast Segmentation with Pectoral Muscle Suppression on Digital Mammograms", Proceedings of the 2nd Iberian Conference (IbPRIA 2005), Estoril, Portugal, 7-9 June 2005, Pattern Recognition and Image Analysis, Springer-Verlag, Heidelberg, 2005, pp. 471-478.
- [11]. Godsitt M., Chan H., "Classification of Compressed Breast Shapes for the Design of Equalization Filters in x-ray Mammography", *Medical Physics*, 25 (1998), pp. 937-947.
- [12]. Ferrari R.J., Rangayyan R.M., Desautels J.E.L., Frère A.F., "Segmentation of Mammograms: Identification of the Skin – air Boundary, Pectoral Muscle, and Fibroglandular Disc", Proceedings of the 5th International Workshop on Digital Mammography, Toronto, Canada, 11-14 June 2000, Medical Physics Publishing, 2001, pp. 573–579.
- [13]. Wirth M., Stapsinski A., "Segmentation of the Breast Region in Mammograms using Snakes", Proceedings of the 1st Canadian Conference on Computer and Robot Vision (CRV 2004), London, Ontario, Canada, 17-19 May 2004, pp. 385-392.
- [14]. Mencattini A., Salmeri M., Lojaco R., Frigerio M., Caselli F., "Mammographic Images Enhancement and Denoising for Breast Cancer Detection Using Dyadic Wavelet Processing", *IEEE Transactions on Instrumentation and Measurement*, 57 (7) (2008), pp. 1422-1430.

Farag H. Alhsnony, et. al. "Breast Border Extraction & Pectoral Muscle Detection using RGB pixel-wise clustering." *IOSR Journal of Electrical and Electronics Engineering (IOSR-JEEE)*, 16(1), (2020): pp. 01-06.