

## L-Ergothioneine Supplement Protect Testicular Functions In Cisplatin-Treated Wistar Rats.

Ayobami DARE<sup>1</sup>, Olugbemi Tope OLANIYAN<sup>2</sup>, Maimuna Abdu SALIHU<sup>1</sup> and Kehinde Linus ILLESANMI<sup>1</sup>

<sup>1</sup>(Department of Physiology, Faculty of Basic Medical Sciences, Bingham University, Karu, Nasarawa state, Nigeria),<sup>2</sup>Department of Physiology, College of Medical sciences, Edo State University, Iyamo, Edo state).

**ABSTRACT:** The present study was designed to investigate the role of L-ergothioneine supplement against cisplatin-induced reproductive toxicity in male wistar rats, regarding the antioxidant and cytoprotectant property of this supplement, and redox indices generated by cisplatin administration during administration. Twenty adult male wistar rats randomly divided into four groups (n=5) were used in this study and subjected to treatment as follows; Group I (control) received 10mL/kg distilled water for 14days; Group II (Cis alone) received a single dose of 7 mg/kg IP of cisplatin on the 10th day. Group III (Erg alone) received 10mg/kg Erg orally for 14days and group IV (Cis+erg) received both Erg and Cis. Body and reproductive organ weight, Sperm analysis, serum level of reproductive hormones (Testosterone, FSH and LH), biochemical (CAT, MDA, SOD, GP<sub>x</sub>) and histological (H&E dye) evaluations of testis were performed.

Treatment with Cisplatin shows a decrease in sperm count, serum testosterone concentration, SOD, GP<sub>x</sub>, CAT and increased abnormal sperm morphology, percentage dead sperm cells, MDA level and causes histopathological damage. However, L-ergothioneine supplement significantly prevent these deleterious effect of Cis.

The result from this study shows that L-erg supplement has protective effects on Cisplatin-induced testicular dysfunction via its antioxidant and cyto-protectant activities. Thus, it has the potential for use as therapeutic adjuvants against reproductive toxicity in patients undergoing Cisplatin therapy.

**Keywords:** L-ergothioneine, cisplatin, antioxidant, testis

Date of Submission: 21-12-2018

Date of acceptance: 06-01-2019

### I. Introduction

Cancer has become a major source of morbidity and mortality globally (Sylla & Wild, 2011) and its increase prevalence has led to the use of antitumour drugs such as Cisplatin (Cis). However, administration of Cisplatin has been reported to cause adverse side effects in a dose-dependent manner via the production of reactive oxygen species (ROS) leading to oxidative damage (Lu *et al.*, 2015). Both human and animal models have demonstrated Cis induces testicular damage (Amin & Hamza, 2006) via germ cell apoptosis, Leydig cell dysfunction and testicular steroidogenic disorder resulting to infertility (Soni *et al.*, 2015; 2016). Studies into the aetiology of Cis-induced reproductive toxicity revealed that it promote the production of ROS causing imbalance in pro-oxidant/antioxidant status which eventually result into lipid peroxidation in the cell membranes (Harman & Richburg, 2014). Thus, a potent antioxidant has been proposed to be a protective measure to ameliorate Cis-induced toxicity.

The benefits of antioxidants continue to be advocated in the context of health and disease management. To this end, scientist evaluated the protective role of some antioxidant compounds like lycopene, selenium (Salem *et al.*, 2012), roselle, ginger (Amin & Hamza, 2006), hesperidin (Kaya *et al.*, 2015) and quercetin (Aldemir *et al.*, 2014) against Cis-induced male reproductive system damage and sperm characteristics which all provide partial amelioration of Cis toxicity. L-ergothioneine (L-erg) is a naturally occurring 2-thio-imidazole amino acid which at physiologic pH, does not auto-oxidize and is therefore very stable in aqueous solution (Melville *et al.*, 1955). It is an excellent chelator of divalent metals and remarkably stable to strong alkali, properties which further differentiate it from other biological thiols (Askari & Melville, 1962). In humans, L-erg is only absorbed through consumption of plant diet, primarily by consumption of edible mushrooms and meat (Shires *et al.*, 1997). Several in-vitro studies have reported the antioxidant and cyto-protective ability of L-ergothioneine (Cheah & Halliwell, 2012; Servillo *et al.*, 2015). Presently, L-erg is radioprotective (Vanet *et al.*, 1993), scavenges free radicals (Ishimoto *et al.*, 2014), confers cellular homeostasis in neuronal cells (Aruoma *et al.*, 1999) and significantly inhibit lipid peroxidation (Kawano *et al.*, 1983). Moreover, it has been shown that L-ergothioneine is well-tolerated without any adverse effect on reproductive function (Forster *et al.*, 2015).

In line with the antioxidant properties of L-ergothioneine and its reproductive safety evaluations, it was of interest to determine whether it could protect testicular functions during Cisplatin administration.

## II. Materials and Methods

### Drugs and chemicals

Cisplatin (50 mg/ 50 ml) manufactured by Khandel Lab. Mumbai, India was purchased from Eden U-K pharmacy in Nigeria. L-ergothioneine supplement (5 mg, 60 capsules) was purchased from Terraternal Ltd, Santa Clara, CA. All other chemicals used in the study were of analytic grade and procured from British Drug house (Poole, Dorset, UK).

### Experimental animals

Twenty adult male Wistar rats weighing (150–230 g) were obtained from National Veterinary Research Institute (VOM) Jos, Nigeria and were housed in Bingham University Animal Care Unit. They were maintained under standardized conditions (12-h light/dark cycle, 27–30°C, 50–80% relative humidity), and were acclimatized in the laboratory for 2 weeks before the commencement of the study. The rats were fed with standard rodent diet and water ad libitum. All the animals were well-cared for according to criteria outlined in the “Guide for the Care and Use of Laboratory Animals” prepared by the National Academy of Science and approved by Bingham University Ethical Research Committee.

### Experimental design:

After acclimatization, the rats were randomly divided into four groups of five animals each and were treated as follows; Group I (control)- 10mL/kg distilled water orally for 14 days; Group II (Cis alone)- distilled water with oral gavage during 14 days and 7 mg/kg Cisplatin single injection IP on the 10th day; Group III (L-erg alone) - 10 mg/kg L-erg supplement orally for 14 days while group IV (Cis + L-erg) were administered both L-erg for 14 days and Cis was injected IP on the 10<sup>th</sup> day. Animals in group I and III were also injected normal saline intraperitoneally on the 10<sup>th</sup> day and the experiment lasted for 14 days. All treatments were given once daily between 7 am and 10 am.

### Evaluation of Biochemical parameters

An hour after the last treatment, all the animals were euthanized under thiopentone sodium anesthesia (30 mg/kg bw, *ip*). Afterwards, they were dissected and blood was collected from the heart via cardiac puncture from which serum was separated. Reproductive organs (testes, prostate, epididymis and seminal vesicle were harvested, cleared of adhering tissue and weighed. Serum samples were assayed for testosterone, FSH and LH level using Enzyme-linked immunosorbent assay (ELISA) technique. The ELISA kits were produced by Fortress diagnostic Ltd and purchased from Bridge Biotech Laboratory (Ilorin, Nigeria). The analyses were performed using a spectrophotometer (Jenway, 6300 spectrophotometer, UK) according to the manufacturer’s instruction.

In addition, the level of superoxide dismutase (SOD), catalase (CAT), Glutathione peroxidase (GPx) and malondialdehyde (MDA) were determined from the testicular homogenate using diagnostic kits purchased from Fortress Diagnostic Limited, UK.

### Semen Analysis

**Progressive sperm motility:**This was done immediately after the semen collection. Semen was squeezed from the caudal epididymis onto a pre-warmed microscope slide (27<sup>o</sup>C) and two drops of warm 2.9% sodium citrate was added, the slide was then covered with a warm cover slip and examined under the microscope using X400 magnification. Ten fields of the microscope were randomly selected and the sperm motility of 10 sperms was assessed on each field. Therefore, the motility of 100 sperms was assessed randomly. Sperms were labelled as motile, sluggish, or immotile. The percentage of motile sperms was defined as the number of motile sperms divided by the total number of counted sperms (i.e. 100) (Mohammad-Reza *et al.*, 2005).

**Sperm viability (percentage dead sperm):**This was done by adding two drops of warm Eosin/Nigrosin stain to the semen on a pre-warmed slide, a uniform smear was then made and dried with air; the stained slide was immediately examined under the microscope using x400 magnification. The live sperm cells were unstained while the dead sperm cells absorbed the stain. The stained sperm were counted and the percentage was calculated (Laing, 1979).

**Sperm morphology:**This was done by adding two drops of warm Walls and Ewas stain (Eosin/Nigrosin stain can also be used) to the semen on a pre-warmed slide, a uniform smear was then made and air-dried; the stained slide was immediately examined under the microscope using x400 magnification (Laing, 1979). Five fields of the microscope were randomly selected and the types and number of abnormal spermatozoa

were evaluated from the total number of spermatozoa in the five fields; the number of abnormal spermatozoa were expressed as a percentage of the total number of spermatozoa.

**Sperm count:** This was done by removing the caudal epididymis from the right testes and blotted with filterpaper. The caudal epididymis was immersed in 5ml formol-saline in a graduated test-tube and the volume of fluid displaced was taken as the volume of the epididymis. The caudal epididymis and the 5ml formol-saline were then poured into a mortar and homogenized into a suspension from which the sperm count was carried out using the improved Neubauer haemocytometer under the microscope.

### **Testicular Histology**

After weighing the testes, they were immediately fixed in Bouin's fluid for 12 hours and the Bouin's fixative was washed from the samples with 70% alcohol. The tissues were then cut in slabs of about 0.5cm transversely and the tissues were dehydrated by passing through different grades of alcohol: 70% alcohol for 2 hours, 95% alcohol for 2 hours, 100% and finally 100% alcohol for 2 hours. The tissues were then cleared to remove the alcohol, the clearing was done for 6 hours using xylene. The tissues were then infiltrated in molten Paraffin wax for 2 hours in an oven at 57°C, thereafter the tissues were embedded. Serial sections were cut using rotary microtome at 5 microns (5µm). The satisfactory ribbons were picked up from a water bath (50<sup>0</sup>-55<sup>0</sup>C) with microscope slides that had been coated on one side with egg albumin as an adhesive and the slides were dried in an oven. Each section was deparaffinized in xylene for 1 minute before immersed in absolute alcohol for 1 minute and later in descending grades of alcohol for about 30 seconds each to hydrate it. The slides were then rinsed in water and immersed in alcoholic solution of hematoxylin for about 18 minutes. The slides were rinsed in water, then differentiated in 1% acid alcohol and then put inside a running tapwater to blue and then counterstained in alcoholic eosin for 30 seconds and rinsed in water for a few seconds, before being immersed in 70%, 90% and twice in absolute alcohol for 30 seconds each to dehydrate the preparations. The preparations were cleared of alcohol by dipping them in xylene for 1 minute. Each slide was then cleaned, blotted and mounted with DPX and cover slip, and examined under the microscope. Photomicrographs were taken at x40 magnifications.

### **Statistical analysis**

All data were presented as mean ± SEM. Data were analyzed by one way analysis of variance (ANOVA), followed by Tukey-Kramer multiple comparison post hoc test. Differences in mean were considered statistically significant at *p*<0.05.

## **III. Results**

### **Effect on relative organ weight**

The weight of reproductive organs (testis, epididymis, prostate and seminal vesicle) was expressed as percentage weight of the organ to that of the body weight prior sacrifice. There was no significant change (*P*>0.05) in the relative reproductive organ weight of rats administered L-erg supplement (10 mg/kg B.W) for 14 days when compared with the control as well as Cisplatin alone group (table 1).

**Table 1:** Effect of 10 mg/kg L-ergothioneine supplement on reproductive organ weight of Cis-treated Wistar rats after treatment for 10 days (n=5).

Organ weight	Control	Cis	L-erg	Cis + L-erg
Testis (%)	0.63 ± 0.03	0.61 ± 0.03	0.63 ± 0.02	0.65 ± 0.03
Epididymis (%)	0.29 ± 0.01	0.29 ± 0.02	0.30 ± 0.02	0.29 ± 0.01
Seminal vesicle (%)	0.40 ± 0.06	0.34 ± 0.03	0.49 ± 0.02	0.32 ± 0.02
Prostate (%)	0.13 ± 0.01	0.17 ± 0.03	0.16 ± 0.01	0.17 ± 0.02

### **Effect on sperm parameters**

Table II shows the effect of L-erg supplement on sperm characteristics. Group IV(cis+L-erg) shows a significant increase (*P*<0.05) in sperm count when compared with group II (Cis alone) while group III (L-erg alone) showed an increase in sperm count when compared with control.

Group III (L-erg alone) showed a significant increase (*P*<0.05) in sperm motility when compared with the control (group I) while Cis+L-erg (group IV) also caused a significant increase (*P*<0.05) in sperm motility when compared with Cis alone group.

Administration of L-erg alone (group III) caused a significant reduction (*P*<0.05) in the percentage of abnormal sperm cells when compared with control (group I) while Cis+L-erg (group IV) also caused a significant decrease (*P*<0.05) when compared with (Cis alone group II).

L-erg alone (group III) reduces the percentage of dead sperm cells when compared with control (group I) however not significant but Cis+L-erg (group IV) showed a significant decrease ( $P < 0.05$ ) in the percentage of dead sperm cells when compared with Cis alone (group II) group.

**Table II:** Effect of 10 mg/kg L-ergothioneine supplement on sperm characteristics of Cis-treated Wistar rats after treatment for 10 days (n=5; \* $P < 0.05$  compared with control; # $P < 0.05$  compared with Cis alone group).

Sperm characteristics	Control	Cis	L-erg	Cis + L-erg
Count ( $\times 10^6$ /ml)	6.28 $\pm$ 0.33	5.64 $\pm$ 0.28	6.92 $\pm$ 0.18	6.64 $\pm$ 0.32 <sup>#</sup>
Motility (%)	49.00 $\pm$ 3.30	39.00 $\pm$ 2.45*	67.00 $\pm$ 3.00*	60.00 $\pm$ 7.58 <sup>#</sup>
Abnormal morphology (%)	17.00 $\pm$ 2.00	24.00 $\pm$ 2.45*	9.00 $\pm$ 1.00*	16.00 $\pm$ 2.45 <sup>#</sup>
Dead cells (%)	20.00 $\pm$ 4.47	38.00 $\pm$ 4.89*	17.00 $\pm$ 2.00	24.00 $\pm$ 2.91 <sup>#</sup>

**Effect on lipid peroxidation and antioxidant status**

Table III shows the effect of 10 mg/kg L-erg supplement on the levels of MDA, SOD, CAT, and GPx in testicular tissue respectively. The result shows that 7 mg/kg Cisplatin treatment lead to a significant increase ( $P < 0.05$ ) in MDA levels and significantly decreases ( $P < 0.05$ ) the level of SOD, CAT and GPx when compared with control and other groups respectively. However, administration of L-erg together with Cis significantly reduces ( $P < 0.05$ ) the level of MDA and also caused a significant increase ( $P < 0.05$ ) in the level of SOD, CAT and GPx when compared with Cis alone group. Also, L-erg supplement significantly increase ( $P < 0.05$ ) SOD and CAT while it significantly decrease MDA level when compared with the control group.

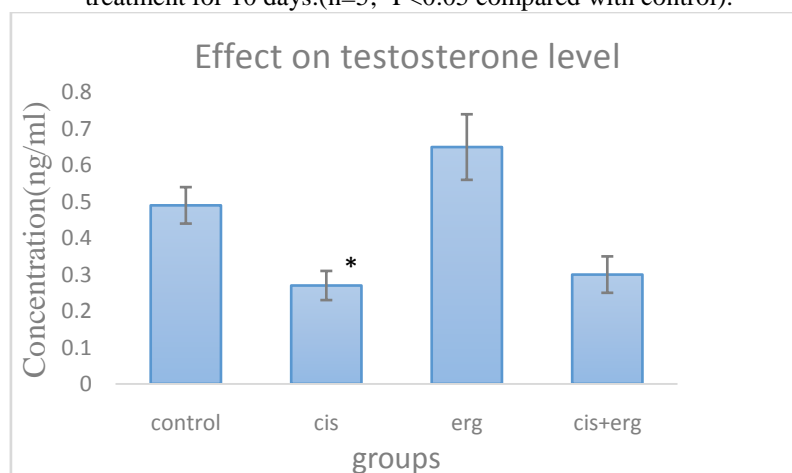
**Table III:** Effect of 10 mg/kg L-ergothioneine supplement on lipid peroxidation and antioxidant enzymes in Cis-treated rats after treatment for 10 days. (n=5; \* $P < 0.05$  compared with control; # $P < 0.05$  compared with Cis alone group).

Biochemical indices	Control	Cis	L-erg	Cis + L-erg
MDA ( $\mu$ mol/ml)	5.42 $\pm$ 0.63	14.07 $\pm$ 1.29*	2.91 $\pm$ 0.25*	7.63 $\pm$ 0.73 <sup>#</sup>
SOD (IU/ml)	1.13 $\pm$ 0.07	0.79 $\pm$ 0.03*	1.38 $\pm$ 0.05*	1.13 $\pm$ 0.06 <sup>#</sup>
CAT ( $\mu$ mol/min/ml)	8.48 $\pm$ 1.24	3.92 $\pm$ 0.61*	21.68 $\pm$ 0.38*	19.16 $\pm$ 2.41 <sup>#</sup>
GPX (IU/ml)	0.57 $\pm$ 0.01	0.52 $\pm$ 0.01*	0.57 $\pm$ 0.01	0.56 $\pm$ 0.01 <sup>#</sup>

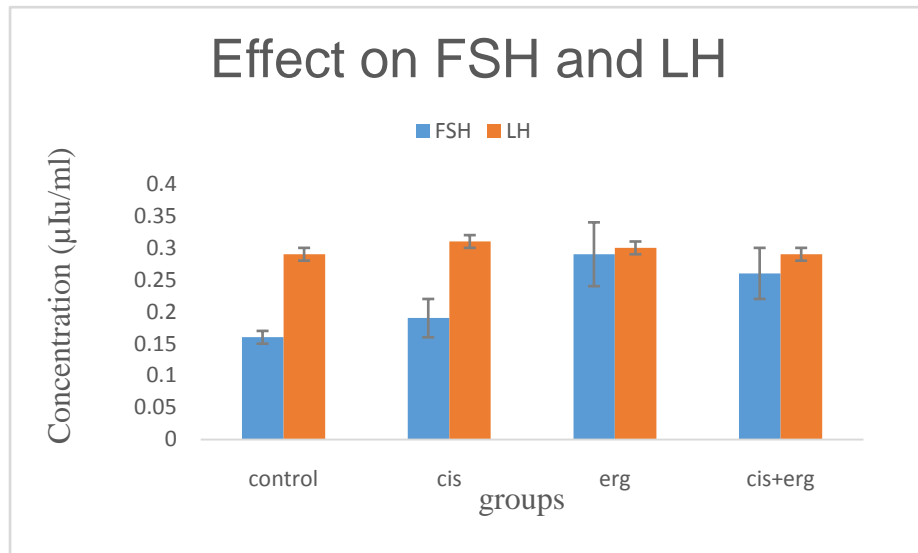
**Effect on reproductive hormones**

The serum level of testosterone was significantly ( $P < 0.05$ ) reduced by cisplatin. However, serum level of testosterone was not significantly affected when treated with L-erg supplement alone as compared with the control but it was able to prevent the reduction in testosterone level when co-administered with cisplatin (figure 1). The serum level of FSH and LH were not significantly affected by both cisplatin and L-erg supplement when compared to control (figure 2).

**Figure 1:** Effect of 10 mg/kg L-ergothioneine supplement on serum concentration of testosterone after treatment for 10 days.(n=5; \* $P < 0.05$  compared with control).

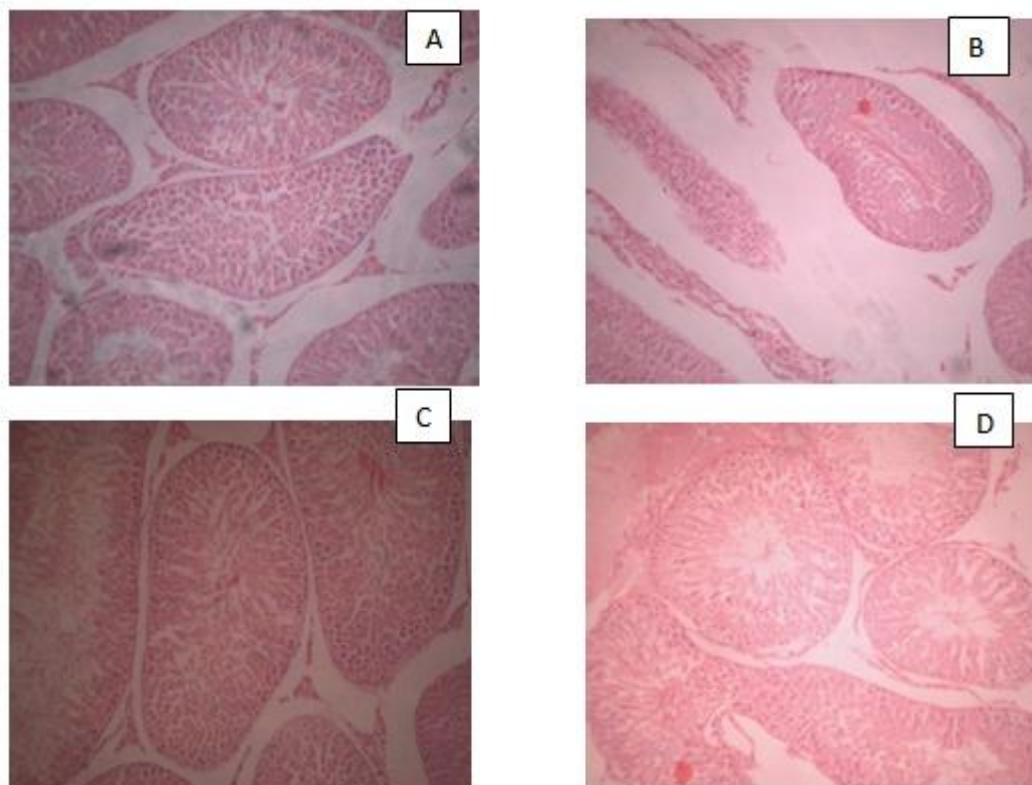


**Figure 2:** Effect of 10 mg/kg L-ergothioneine supplement on serum concentration of FSH and LH after treatment for 10 days. (n=5).



**Effect on testicular histology**

Plate 1(A-D) shows photomicrograph of testicular section stained with H&E at x40. Photomicrograph of the testis shows the following changes. The control group (A) presented testis with normal arrangement of the germinal epithelium, seminiferous tubules and interstitial cells. Cis alone group (B) presented with severe necrosis, degeneration of interstitial cells and loss of matured germinal cells. L-erg alone (C) presented with similar testicular arrangement similar to the control with no visible lesion while Cis+L-erg (D) shows mild derangement of the spermatogenic series and germinal epithelium. The lesions induced by Cis were substantially recovered by L-erg pretreatment.



#### IV. Discussion

In this study, it was demonstrated that Cis treatment had no significant effect on the percentage reproductive organ weight similar result was reported by Beytur and colleagues in 2012. This could be due to the sensitivity of rats and duration of drug treatment (Beytur *et al.*, 2012). It was also observed that administration of L-erg supplement had no significant effect on the reproductive organ weights. This result suggests that L-erg supplement was not toxic to the rats because change in relative or absolute weight of an organ after drug administration is an indication of the toxic effect of the drug (Maina *et al.*, 2008). It could also be due to the absence of androgenic property in this compound, since androgens possess anabolic activities (Johnson & Everitt, 1998). In addition, the weight of male reproductive organs usually provides a useful fertility/reproductive risk assessment in experimental studies (Raji *et al.*, 2005c). Testicular size is the best primary assessment for spermatogenesis since the tubules and germinal elements account majorly for the testicular weight (Sherines & Howard, 1978). Findings from this study shows that L-erg was able to prevent the reduction in weight when co-administered together with Cis although not significant which implies that L-erg could be a protective adjuvant to protect testicular function during Cisplatin chemotherapy.

Previous studies about the oxidative status of the testis indicated that L-erg administration reduces lipid peroxidation and enhance antioxidant enzyme activities (Guijarro *et al.*, 2002, Cheah & Halliwell, 2012). Also, our result, shows that L-erg supplement decreases lipid peroxidation in rat testis when administered together with Cis as shown by the significant reduction in MDA level in Cis+L-erg treated group when compared with Cis alone group. Excess production of free radicals can cause lipid peroxidation because lipids are the most important component of cell membrane. L-erg treatment also enhance the antioxidant enzymes activity in the testis by significantly increasing the level of SOD, CAT and GPx level in Cis+L-erg group compared with Cis alone group. This could be due to the antioxidant activity of this natural compound; several in-vitro and few in-vivo experiments have reported its antioxidant efficacy against different stressors (Guijarro *et al.*, 2002; Jang *et al.*, 2004). Previous studies reported that L-erg scavenges certain reactive oxygen species (ROS) and bind transition metal ions (Halliwell & Gutteridge, 2015; Servillo *et al.*, 2015). Antioxidant and related effects of L-erg on cell culture have also been demonstrated (Markova *et al.*, 2009; Ishimoto *et al.*, 2014). Grundemann and colleagues in 2005 identified a Na<sup>+</sup>-dependent transporter for L-erg, the organic cation transporter novel, type 1 (i.e. OCTN1) which is present in a wide range of animal tissues suggests that animals may gain benefit from obtaining L-erg and retaining it in their tissues (Grundemann *et al.*, 2005). It has also been shown that L-erg concentration increases in tissue exposed to oxidative stress suggesting a protective role of this compound against oxidative damage (Paul & Snyder, 2010).

It was also observed that L-erg co-administered with Cis prevents spermatological dysfunctions by increasing sperm count and motility as well as reducing percentage abnormality and dead sperm cells significantly when compared Cis alone group. All these indices were negatively affected by Cis treatment in this study as confirmed by the reports of previous findings (Rezvanfar *et al.*, 2013; Aksu *et al.*, 2015). It has been reported that Cisplatin induces reproductive toxicity via the production of ROS causing damage in body cells by impairing macromolecules such as polyunsaturated fatty acids in membrane lipids and proteins in cell membranes (Salem *et al.*, 2012; Harman & Richburg, 2014). The damage induced by ROS in the sperm cell membrane may be the cause of death, abnormality and motility loss. It has been demonstrated that spermatological parameters such as progressive motility, sperm cell density and morphology of spermatozoa are in close relation to each other. Thus, factors that adversely affect one of them will also alter other parameters (Bonde *et al.*, 1996). L-erg supplement significantly reduced oxidative stress by decreasing MDA levels and increasing SOD, GPx and CAT activities. Thus, protecting against Cis-induced spermatologic damages.

Hormones play a vital role in initiating and maintenance of male reproductive function (Meeker *et al.*, 2007a) and it is known that gonadal dysfunction is one of the most common side effects of chemotherapy (Desantis *et al.* 1999) affecting both the endocrine and exocrine compartments of the testis (Spermon *et al.*, 2006). In this study, it was observed that L-erg supplement has no significant effect on the serum concentration of reproductive hormones (Testosterone, FSH and LH) when compared with the control group but was able to prevent the significant reduction in testosterone level caused by Cisplatin when administered together. It has been reported that Cis cause damage to the Leydig cells (Vawda, 1994), so that testosterone production is hampered. Thus, L-erg supplement enhanced the steroidogenic activity of the testis thereby ameliorating the detrimental effect of Cis on testosterone. The increased levels of LH with a decreased serum testosterone levels indicates malfunctioning of leydig cells and invariably impairment of endocrine function (Hansen *et al.* 1990; Howell & Shalet, 2001). The increased levels of LH and FSH observed could be ascribed to the feedback mechanism through which the gonadotropins helps to reinstate normal testosterone levels (Nijman *et al.* 1987). The histological evaluation of the testis revealed that Cis caused significant alterations in the cyto-architecture of the testicular tissue which was in agreement with previous studies (Trivedi *et al.*, 2011; Ataman *et al.*, 2015). However, L-erg supplement prevented the degenerative changes induced by Cisplatin. Furthermore, L-erg supplement shows a normal histological arrangement similar to the control when administered alone. It was able

to prevent these damages via its antioxidant, cytoprotectant and steroidogenic ability thereby hindering the processes of peroxidation of the polyunsaturated fatty acids in the membrane of testicular tissues, protecting the seminiferous tubule and leydig cell, thereby maintaining the integrity of the testis.

#### IV. Conclusion

This study has demonstrated that L-ergothioneine supplement significantly protect the testes against Cis-induced testicular toxicity by enhancing the antioxidant enzyme activities, reducing lipid peroxidation and maintaining the steroidogenic enzyme activity in the testis. These result suggest that supplementation of L-ergo could be beneficial to male cancer patient undergoing Cisplatin chemotherapy.

#### References

- [1]. Aksu, EH, Akman, O, Ozkaraca M, Omur AD, Ucar O (2015): Effect of *Maclura pomifera* extract against cisplatin-induced damage in reproductive system of male rats. *Kafkas Universitesi Veteriner Fakultesi Dergisi*. 21:397–403.
- [2]. AldemirM, OkuluE, KösemehmetoğluK, Ener K, Topai F, Evigren O, Gurleyik E, Avci A (2014): Evaluation of the protective effect of quercetin against cisplatin-induced renal and testis tissue damage and sperm parameters in rats. *Andrologia*. 46 (10), 1089-1097.
- [3]. Amin AA, Hamza EA (2006): Effects of Roselle and Ginger on cisplatin-induced reproductive toxicity in rats. *Asian Journal of Andrology*. 8(5), 607–612.
- [4]. Aruoma OI, Spencer JP, Mahmood N (1999): Protection against oxidative damage and cell death by the natural antioxidant ergothioneine. *Food and Chemical Toxicology*. 37(11):1043-53.
- [5]. Askari A, Melville DB (1962): The reaction sequence in L-Ergo biosynthesis: hercynine as an intermediate. *Journal of Biological Chemistry*. 237:1615–8.
- [6]. Ataman JE, Osinubi AA, Baxter-Grillo, D (2015): *Cytoarchitectural effects of ethanolic leaf extract of Newbouldia laevis (P. Beauv.) on cisplatin-induced testicular damage in wistar rats. Annals of Biomedical Sciences*. 14(1): 10-19.0
- [7]. Beytur A, Ciftci O, Oguz F, Oguzturk H, Yimaz F (2012): Montelukast attenuates side effects of cisplatin including testicular, spermatological, and hormonal damage in male rats. *Cancer Chemotherapy and Pharmacology*. 69(1):207–213.
- [8]. Bonde JP, Giwercman A, Ernst E (1996): Identifying environmental risk to male reproductive function by occupational sperm studies: logistics and design options. *Occupational and Environmental Medicine*. 53(8):511–19.
- [9]. Cheah IK, Halliwell B (2012): Ergothioneine; antioxidant potential, physiological function and role in disease. *Biochimica et Biophysica Acta*. 1822(5): 784-793.
- [10]. DeSantis M, Albrecht W, Holtl W, Pont J (1999): Impact of cytotoxic treatment on long-term fertility in patients with germ-cell cancer. *International Journal of Cancer*. 12 (10): 83:864–865.
- [11]. Forster R, Spezia F, Papineau D, Sabadie C, Erdelmeier I, Moutet M, Yadan J (2015): Reproductive safety evaluation of L-ergothioneine. *Food chemical toxicology*. 80: 85-91.
- [12]. Grundemann D, Harlfinger S, Golz S, Geerts A, Lazar A, Jung N, Rubbert A, Schomig E (2005): Discovery of the Ergothioneine transporter. *Proc Natl Acad Sci*. 102(14):5256-61.
- [13]. Guijarro MV, Indart A, Aruoma OI, Viana M, Bonet B (2002): Effects of ergothioneine on diabetic embryopathy in pregnant rats. *Food and Chemical Toxicology*. 40(12), 1751–1755.
- [14]. Halliwell B, Gutteridge JMC (2015): Antioxidant defences synthesized in vivo. in: *Free Radicals in Biology and Medicine*. 5th ed., Oxford University Press, 77-152.
- [15]. Hansen SW, Berthelsen JG, and von der Maase H (1990): Long-term fertility and Leydig cell function in patients treated for germ cell cancer with cisplatin, vinblastine, and bleomycin versus surveillance. *Journal of clinical Oncology*. 8(10), 1695-1698.
- [16]. Harman JG, Richburg JH (2014): Cisplatin-induced alterations in the functional spermatogonial stem cell pool and niche in C57/BL/6J mice following a clinically relevant multi-cycle exposure. *Toxicology Letters*. 277(2),99–112.
- [17]. Howell SJ, Shalet SM (2001): Testicular function following chemotherapy. *Human Reproduction Update*. 2001; 7: 363-369.
- [18]. Ishimoto T, Nakamichi N, Hosotani H (2014): Organic cation transporter-mediated ergothioneine uptake in mouse neural progenitor cells suppresses proliferation and promotes differentiation into neurons. *PLoS One*. 9(2) e89434.
- [19]. Johnson, MH, Everitt BJ (1998): In Essential reproduction. *BlackWell Scientific Publication*. *N Engl J Med*. 338(16):1128-37.
- [20]. Kawano H, Otani M, Takeyama K, Kawai Y, Mayumi T, Hama T (1983): Studies on ergothioneine. VI. Distribution and fluctuations of ergothioneine in rats, *Chemical and Pharmaceutical Bulletin*. 30(5), 1760–1765.
- [21]. Kaya K, Ciftci O, Cetin A (2015): Hesperidin protects testicular and spermatological damages induced by cisplatin in rats. *Andrologia*. 47(7),793–800.
- [22]. Laing JA (1979): Fertility and infertility in domestic animals. 3rd edition 1979 Bailliere Tindall, a division of Cassell Lt.
- [23]. Lu Q, Zhang Q, Ning Ou N, Wang C, Warrington J (2015): In Vitro and In Vivo Studies of Non-Platinum-Based Halogenated Compounds as Potent Antitumor Agents for Natural Targeted Chemotherapy of Cancers. *EBiomedicine*. 2(6): 544-553.
- [24]. Maina MB, Garba SH, Jacks TW (2008): Histological evaluation of the rat testis following administration of herbal tea mixture. *Journal of Pharmacology and Toxicology*. 3(6):464-470.
- [25]. Markova NG, Karaman-Jurukovska N, Dong KK, Damaghi N, Smiles KA, Yarosh DB (2009): Skin cells and tissue are capable of using L-ergothioneine as an integral component of their antioxidant defense system, *Free Radical Biology and Medicine*. 46(8): 1168-1176.
- [26]. Meeker J D, Godfrey-Bailey L, Hauser R (2007a): Relationships between serum hormone levels and semen quality among men from an infertility clinic. *Journal of Andrology*. 28(3), 397–406.
- [27]. Melville DB, Horner WH, Otken CC, Ludwig ML (1955): Studies of the origin of L-Ergo in animals. *Journal of Biological Chemistry*. 213(1),61–68.
- [28]. Mohammad – Reza P, Farzaneh D, Taherch TK, Zoherb PP (2005): The effects of hydroalcoholic extract of *Actinidia chinensis* on sperm count and motility, and blood levels of estradiol and testosterone in male rats. *Achieves of Iranina Medicine*. 8(3), 211-216.
- [29]. Nijman JM, SchraffordtKoops H, Kremer J, Sleijfer DT (1987): Gonadal function after surgery and chemotherapy in men with stage II and III nonseminomatous testicular tumors. *Journal of Clinical Oncology*. 5(4), 651–656.
- [30]. Paul BD, Snyder SH (2010): The unusual amino acid L-ergothioneine is a physiologic cytoprotectant, *Cell Death and Differentiation*. 17(7): 1134–1140.

- [31]. Raji Y, Ifabunmi OS, Akinsomisoye OS, Morakinyo OA, Oloyo AK (2005c): Gonadal response to antipsychotic drugs: chlorpromazine and thioridazine reversibly surpress testicular function in albino rats. *International Journal of Pharmacology*. 1(3),287-292.
- [32]. Rezvanfar MA, Rezvanfar, MA, Shahverdi, AR, Ahmadi A, Baeeri M, Mohammadirad A, Abdollahi M (2013): Protection of cisplatin-induced spermatotoxicity, DNA damage and chromatin abnormality by selenium nano-particles. *Toxicology and Applied Pharmacology*. 266(3):356–365.
- [33]. Salem EA, Salem NA, Maarouf AM, Serefoglu EC, Hellstrom WJ (2012): Selenium and lycopene attenuate cisplatin-induced testicular toxicity associated with oxidative stress in Wistar rats. *Urology*.; 79(5),1184. 1–6.
- [34]. Servillo L, Castaldo D, Casale R, D’Onofrio N, Giovane A, Cautela D, Balestrieri ML (2015): An uncommon redox behavior sheds light on the cellular antioxidant properties of ergothioneine, *Free Radical Biology and Medicine*. 79; 228-236.
- [35]. Sherines RJ and Howards SS Male fertility (1978): In: Harrison, JH, Gittes, RF, Perimutter, AD, Stanney TA and Walsh PC (Eds.). *Campbell’s Urology*. 4th Edition, Saunders, WB Co., Philadelphia, Pa., pp715.
- [36]. Shires TK, Brummel MC, Pulido JS, Stegink LD (1997): Ergothioneine distribution in bovine and porcine ocular tissues, *Comparative Biochemistry and Physiology part C Pharmacology, Toxicology and Endocrinology*. 117(1), 117–120.
- [37]. Soni KK, Kim HK, Choi BR, Karna KK, You JH, Cha JS, Shin YS, Le SW, Kim CY, Park JK (2016): Dose-dependent effects of cisplatin on the severity of testicular injury in Sprague Dawley rats: reactive oxygen species and endoplasmic reticulum stress. *Drug Design, Development and Therapy*. 10: 3959–3968.
- [38]. Soni KK, Zhang LT, Jae Hyung You JH, Lee SW, Kim CY, Chae HJ, Kim HK, Park JK (2015): The effects of MOTILIPERM on cisplatin induced testicular toxicity in Sprague–Dawley rats. *Cancer Cell International*. 15(121): 1-11.
- [39]. Spermon JR, Ramos L, Wetzels AM, Sweeps CG, Braat DD Kiemeney LA, Witjes JA (2006): Sperm integrity pre- and post-chemotherapy in men with testicular germ cell cancer. *Human Reproduction*. 21(7):1781–1786.
- [40]. Sylla BS, Wild CP (2012): A million Africans a year dying from cancer by 2030: what can cancer research and control offer to the continent? *International Journal of Cancer*. 130 (2):245-50.
- [41]. Trivedi PP, Tripathi DN, Jena GB (2011): Hesperetin protects testicular toxicity of doxorubicin in rat: role of NF $\kappa$ B, p38 and caspase-3. *Food and Chemical Toxicology*. 49(4), 838–847.
- [42]. Van den Broeke LT, Beyersbergen GM (1993): Thiols as potential UV radiation protectors: An *in vitro* study. *Journal of Photochemistry and Photobiology B: Biology*. 17 (3); 279-286.
- [43]. Vawda AI (1994). Effect of testosterone on cisplatin-induced testicular damage. *Archives of Andrology*. 32(1), 53-57.

Ayobami DARE "L-Ergothioneine Supplement Protect Testicular Functions In Cisplatin-Treated Wistar Rats.: Jatropha grossy piifolia, Justicia secunda and Parquetina nigrescens from East Côte d'Ivoire." *IOSR Journal of Pharmacy and Biological Sciences (IOSR-JPBS)* 14.1 (2019): 06-13.