

Breast Fibroadenoma an Overview

Mayuri.K.Lonare^{*1}, Rubina.R.Shaikh², Jyoti.B.Chavan¹, Bhakti.R.Kasode² and
Monali.A. Katkade¹

1-Department of Quality Assurance, Pravara Rural College of Pharmacy
(For Women) Chincholi, Nashik, 422103, (MS) India.

2-Nandkumar Shinde College Of Pharmacy, Vaijapur, 423701, (MS) India.

*Corresponding Author: Ms. Mayuri K. Lonare

Department of Quality Assurance, Pravara Rural College of Pharmacy
(For Women) Chincholi, Nashik, A/P-Sinnar, Dist-Nashik 422103, India (MS).

Abstract

Fibroadenomas is the most common lumps found in adolescence girls. That usually occur under the influence of hormonal changes that is girls undergo at the time of puberty & they happen due to overgrowth of glandular tissue in the breast. Ultrasonography is the best diagnosis for fibroadenoma. There are no medical treatments for the fibroadenoma except surgical excision & a new method recently comes out—vacuum assisted fibroadenomas resection.

Keywords: Fibroadenoma, Ultrasound, Adolescence Girls, Glandular Tissue, Submammary Incision, Periareolar Incision

Date of Submission: 17-08-2020

Date of Acceptance: 03-09-2020

I. Introduction

Fibroadenoma is a benign breast lump that occurs mainly in women under 35. This is the most common lump found in teenagers and in women in their early 20's. Fibroadenomas are solid lumps made up of fibrous tissue and gland cells that have multiplied faster than normal. It is usually painless, firm lump that may increase in size over time, but it does not tend to change with the menstrual cycle. Some women find the lump becomes tender before their period. Fibroadenomas are usually rubbery and firm, but they can be difficult to feel properly. If you push on the lump, you will probably find that it moves away from beneath your fingers. This is why fibroadenoma called 'breast mouse'. They do not move far within the breast. The natural behavior of fibroadenomas is to gradually increase in size up to 1-3cm over a period of about 5 years. Fibroadenomas range in size. They can be smaller than a marble or as large as a gall ball. Most fibroadenomas appear suddenly and then stay the same size. Some shrink or continue to grow. Fibroadenomas are affected by hormones just like any other breast tissue. They often change size over the menstrual cycle or in pregnancy. Traditionally all fibroadenomas were treated by surgical excision just to exclude malignancy. It is not known what causes a fibroadenoma. It is thought that it probably occurs because of increased sensitivity to the hormone estrogen. Researchers also do not know what causes fibroadenomas. Sometimes a fibroadenoma can be difficult to distinguish from cancer; therefore further testing is required.

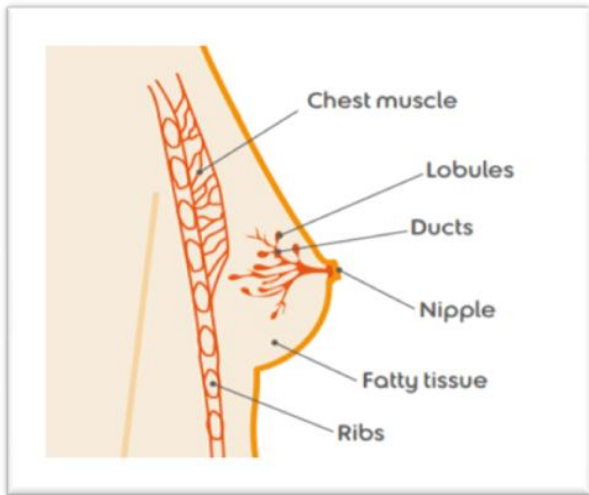


Fig no.1 Normal breast structure¹¹



Fig No.2 Disease mainly affect to young womens¹¹

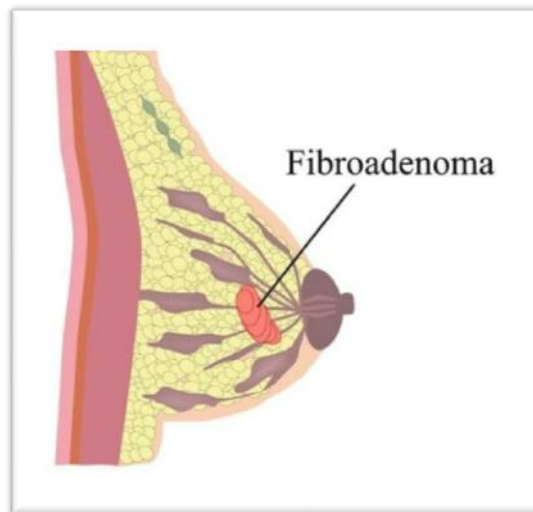


Fig No.3 fibroadenoma¹¹

Fibroadenomas category²

Subclasses of fibroadenomas consist of simple fibroadenoma, giant juvenile fibroadenoma, and multicentric fibroadenoma. 70-90% of fibroadenomas remain simple fibroadenomas, the utmost collective kind of fibroadenoma. Giant juvenile fibroadenomas exist as exceptional variant of fibroadenoma. They are demarcated as one promptly benign encapsulated fibroadenoma with a span greater than 5cm, deliberate 500 g, or transferring at least four fifths of the breast. Giant fibroadenomas are concomitant by means of skin ulceration and venous enlargement .The occurrence of giant fibroadenomas is just about 0.5%-2% of all fibroadenomas. Giant fibroadenomas: is the ultimate collective origin of estrogen.

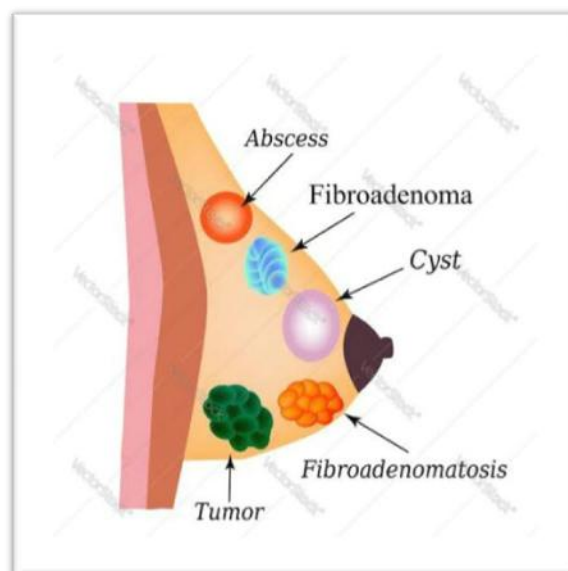


Fig no.4 other disease including fibroadenoma.¹²

II. HISTORY³

The natural history of fibroadenomas is well understood. A large proportion of fibroadenomas regress spontaneously. Some of remain static, others shrink, while some of them grow. About 40% of fibroadenomas reduce in size over period of two years. Approximately 10% disappear each year. Most stop growing after they reach 2 to 3 cm. On 1st January 2013 to 30th June 2014 cross sectional study was carried out in a rural medical college and hospital. Among a total of 1236 patient with benign breast diseases, fibroadenomas was most common lesion constituting 842(68%)cases. When fibroadenomas involutes in the postmenopausal women, coarse calcification may develop they may grow rapidly during pregnancy, hormone replacement therapy and immunosuppressive of treatment. Fibroadenomas predominantly occur in second and third decade of decade. Fibroadenoma is a discrete, smooth, mobile, nontender mass frequently situated in the upper outer quadrant where the most breast tissue lies. First discover is 1-2cms in size. of pain-site, character, relationship with menstrual cycle; History of lump- number and site of lump, onset and progression, premenstrual aggravations of lump; History of discharge- site, type of discharge.

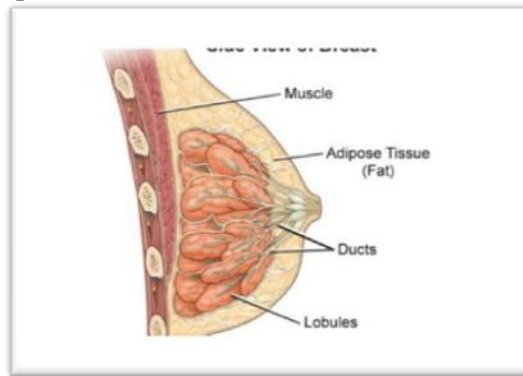
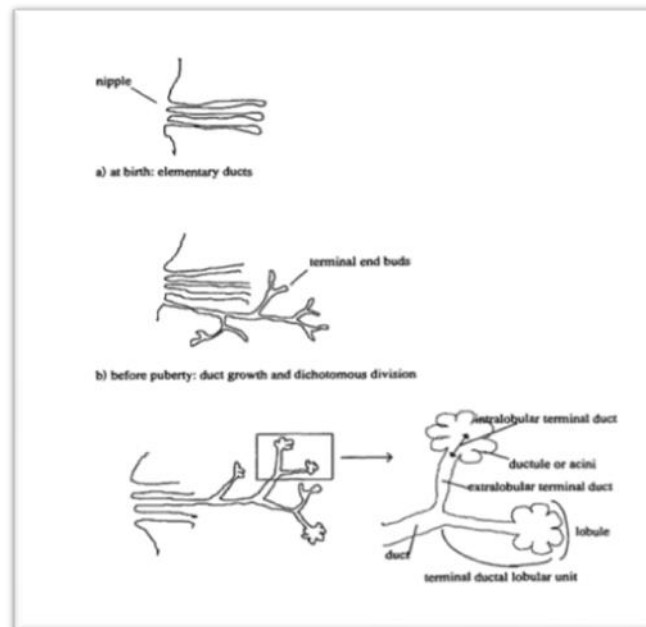
III. Epidemeology Of Fibroadenomas^{5,6}

Benign breast of disease deserves attention because of its high prevalence, its impact on women's quality of the life, and, for some histologic types, its cancerous potential. Identification of the risk factors for benign breast disease could improve our understanding of its etiology or pathogenesis and help to the define preventive strategies.

Methods

All autopsy and cohort studies that we were able to identify were used to estimate the frequency of benign breast disease. Studies that relied only on anamnestic or clinical definitions of benign breast disease, intervention trials in which there were no control stand studies for which incomplete information about methodology was provided were excluded from analysis.

1. case-control studies with hospital controls,
2. case-control studies with population controls,
3. cohort and nested case-control series. Each risk factor was then studied separately.

Breast morphology and development:**Fig No.5 Side view of breast^{11,12}****Fig No.6 Morphology of breast^{11,12}.**

Breast development and related terminology is presented in fig.

- 1) the mammary gland develops in the embryo from an invagination of the superficial ectoderm which forms elementary ducts in the connective tissue;
- 2) before puberty, the ducts grow and divide in a dichotomous way; and
- 3) lobule formation occur after menarche and increases with age up to about the age of 25 years.

Epithelial and stromal proliferation and regression occur regularly with menstruation, but complete differentiation with maximal development of lobular tissue takes place only through pregnancy and lactation. Fibroadenomas are benign tumors. Macroscopically; they are pseudoencapsulated and sharply delimited; microscopically, they have both an epithelial and a stromal component. Fibrocystic breast disease in contrast to fibroadenoma. Clinically it is define as “ a condition in which there are palpable lumps in the breast, usually associated with pain and tenderness, that fluctuates with the menstrual cycle and progressively worse until menopause”.

Accordingly, a fibroadenoma develops from a single lobule as a benign breast “ disorder” or if its size exceeds 5 cm, as a benign breast “disease”(giant fibroadenoma). The changes usually linked to fibrocystic disease (eg. Cysts, sclerosing adenosis, and simple hyperplasia) are aberrations of involution and are classified as benign breast “disorder”. At the end of the spectrum, atypical and lobular hyperplasia are classified as benign breast “disease”.

Frequency of benign breast disease³

Estimating the incidence of benign breast disease in the general population is difficult, because it is not a life threatening condition and it does not necessarily come to medical attention. Women who are diagnosed and receive medical care are therefore selected subset of all cases. Thus the actual detection rate is not known and can only be approximately by comparing the prevalence rates of benign breast disease obtained from autopsy studies with the cumulative incidence rates from cohort studies.

Factors associated with benign breast disease³

For this disease analysis of risk factors, was separated into two subgroups, fibrocystic breast disease and fibroadenoma. Fibroadenoma represents smaller subgroup, even though it is the most common form of benign breast disease in women aged less than 30 year. Two studies included only fibroadenoma: 1) Canny et al. conducted a hospital-based case control study 2) Yu et al. used two types of controls, negative breast biopsy controls and population controls. The other studies that separated fibroadenoma from fibrocystic breast disease comprised one cohort study, one cohort-nested case control study, one screening-based case-control study, two population-based case-control studies, and 13 hospital-based case-control studies.

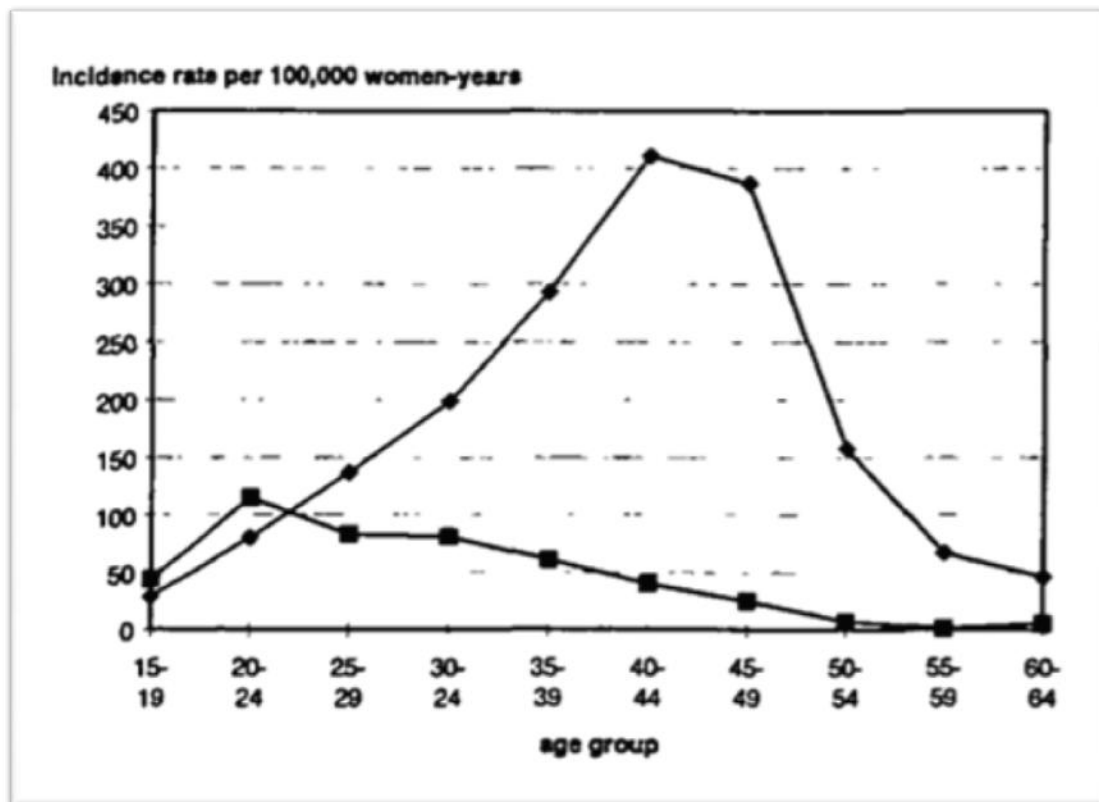


Fig No:7 Graph of case-control study^{11,12}.

➤ Age at menarche:

Age at menarche is not associated with either fibrocystic breast disease or fibroadenoma. This association has only been assessed in case-control studies, none of which have suggested that age at menarche influences the subsequent risk of benign breast disease (46, 47, 51, 52, 54, 58, 61, 69-72).

➤ Age at menopause:

Age at menopause may possibly be related to fibrocystic breast disease but not to fibroadenoma. The evidence in favour of an increased risk of fibrocystic breast disease with later age at natural menopause comes from four hospital based studies (58-60, 70) and two population-based case-control studies (47, 73). Cole et al. (47) reported the relative risks to be 1.4 and 3.0 for ages at menopause of 49-51 and >52 years, respectively, relative to ages at menopause of <49 years (p for trend = 0.0005). Studies with more refined histologic definitions of benign breast disease (48, 69, 71) found no association.

➤ Nulliparity:

Nulliparous women may be at increased risk of fibrocystic breast disease but not of fibroadenoma. One hospital-based case-control study and cohort study found an increased risk of fibrocystic breast disease for nulliparous versus women. In the study by Cole et al. (47), this positive association was restricted to women under 40 years

of age.

➤ **Multiparity**

A higher parity may be protective against fibrocystic breast disease but not against fibroadenoma. The association of fibroadenoma with parity has not received much attention, and the limited available data are inconsistent: Yu et al. found a protective effect for fibroadenoma using population controls but not when using biopsy controls.

➤ **Age at first live birth:**

Finding relating late age at first live birth to fibrocystic breast disease are inconsistent. A positive association with fibrocystic breast disease was observed only in hospital-based case-control studies(59,60,69,)Reported findings of fibroadenoma with age at first live birth have been consistently negative(46, 47, 54, 56-61).

➤ **Breastfeeding**

Studies which examined the relation of ever breast feeding with benign breast disease failed to show an association with either fibrocystic breast disease or fibroadenoma (52,54,56,57,69).Overall the most salient findings related to reproductive and menstrual history are that being parous, being multiparous, being young at natural menopause may protect against fibrocystic breast disease.

➤ **Education:**

Studies in which the compared groups were not matched on a socioeconomic variable(56, 61,69, 72,74,) showed that a higher level of education was positively related to fibrocystic breast disease. It also include following factor.

➤ **Obesity**

➤ **Oral contraceptives**

➤ **Estrogen replacement therapy**

➤ **Smoking**

➤ **Diet**

IV. Etiology⁸

Fibroadenomas is more common in younger women in their teens and twenties.However, can occur at any age up until menopause.Fibroadenoma is responsive to hormone levels therefore, women taking hormone therapy can get them even after menopause. Due to hormone sensitive, fibroadenoma can change in size varing hormone levels.

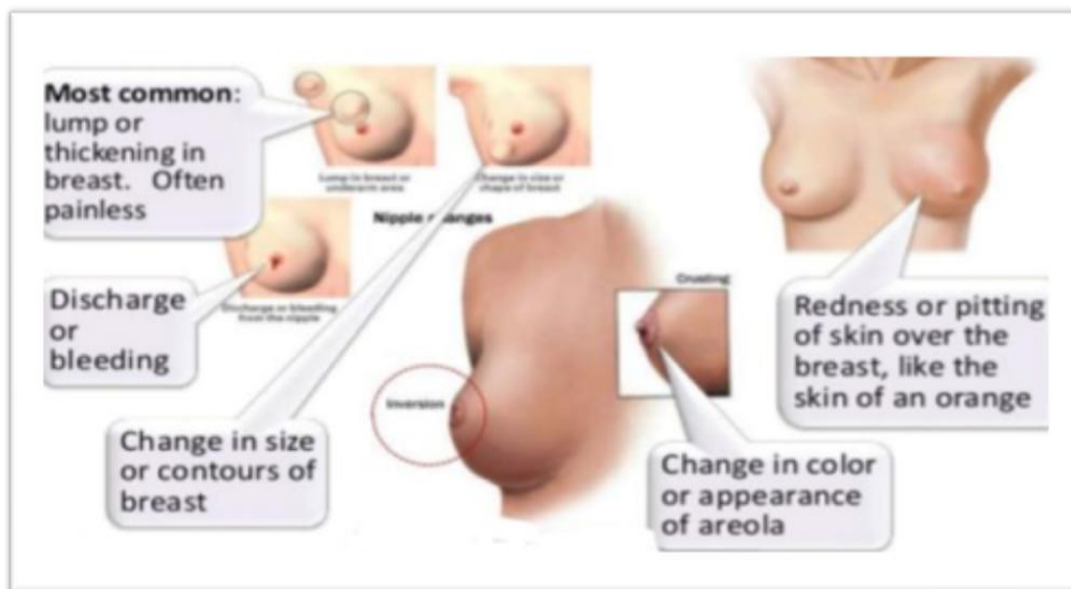


Fig No.8 signs and symptoms of fibroadenoma.^{11,12.}

The exact etiology of fibroadenoma is unknown. However, several studies show that estrogen influences the development of fibroadenomas. In a large population study of 265,402 women, risk factors for development of fibroadenoma include young age , self-breast examination, and prior history of benign breast disease. Exposure to an estrogen-progesterone oral contraceptive before menopause and increasing number of live births decreases the risk of fibroadenoma. There also a correlation between body mass index and incidence of fibroadenoma.

In a study mass index group of 25-29.9kg/gm. Fibroadenomasd can also be associated with syndromes

such as Beckwith-Wiedemann syndrome, Maffucci syndrome, and Cowden syndrome. Fibroadenomas themselves do not posture any danger of breast tumour growth all though the breast tissue. In many older articles, this is often comprised, it has been proposed that fibroadenomas may be linked with an improved probability of rising breast cancer.

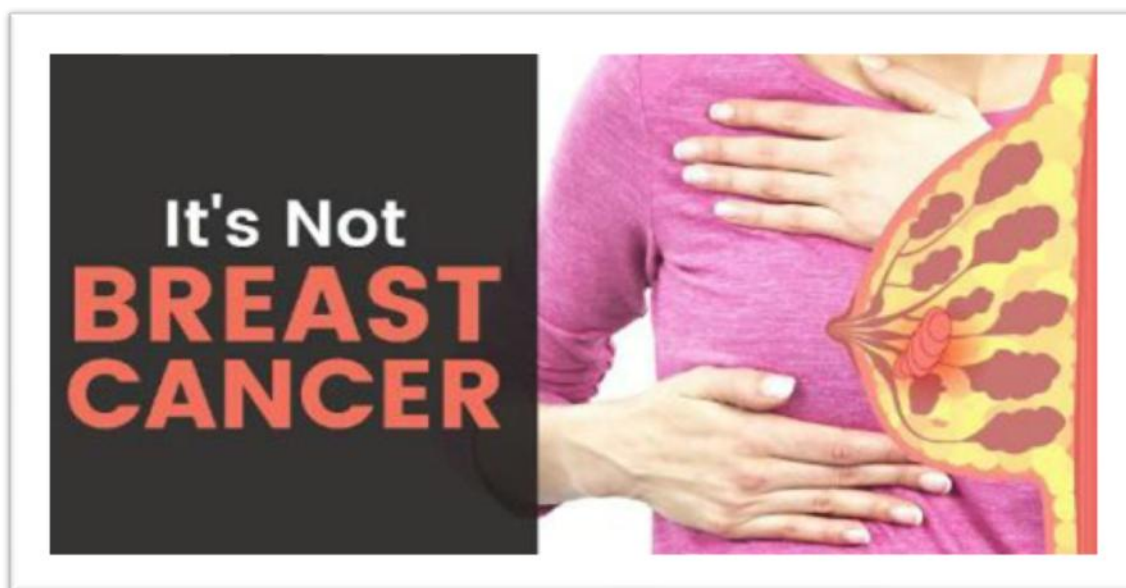

Fig No.9 Awareness about fibroadenoma its not an breast cancer.^{11,12.}

V. Pathogenesis¹⁰

Fibroadenoma is to be placed within the spectrum of fibroepithelial breast lesions as it is composed of both a stromal and an epithelial component, arising from the epithelium and stroma of the terminal duct-lobular unit. Fibroadenomas have been suggested to arise within sclerosing lobular hyperplasia which is present in the surrounding breast tissue of about 50% of fibroadenomas. And can imagine that some fibroadenomas arise as localised foci of accelerated proliferation in a background of sclerosing lobular hyperplasia. On the other hand, fibroadenoma may even arise from continuous expansion of only one lobule. However, this is probably rare, as only a single case of fibroadenoma with monoclonal stroma has been described. As the lobular unit is the monoclonal “patch” of the human breast meaning that all cells in one lobule derive from one progenitor cell, we conclude that most fibroadenomas probably derive from several lobules. Fibroadenomas may develop usual ductal hyperplasia.

VI. Diagnosis^{4,9,11}

Most often, fibrocystic changes are diagnosed based on symptoms, such as breast lumps, swelling, and/or tenderness or pain. These symptoms tend to worsen just before your menstrual period begins, and may change as you move through different stages of your menstrual cycle. Your breasts feel lumpy and, sometimes, you may notice a clear or slightly milky nipple discharge. Sometimes, one of the lumps might feel firmer or have features that lead to a concern about cancer. When this happens an ultrasound may be done to see if the lump is solid or is just filled with fluid (called simple cysts). If the ultrasound shows the lump is solid or if the cyst has both fluid and solid components (a complex cyst), a biopsy may be needed to make sure that it's not cancer.

Methods of diagnosis:

A lump is first noticed during a self breast exam or during clinical breast exam. Further investigation with a mammogram and/or ultrasound is often recommended to rule out other breast diseases. Ultrasound is a useful tool as it can most accurately measure the size, determine the number and provide information on the growth of fibroadenoma over time.

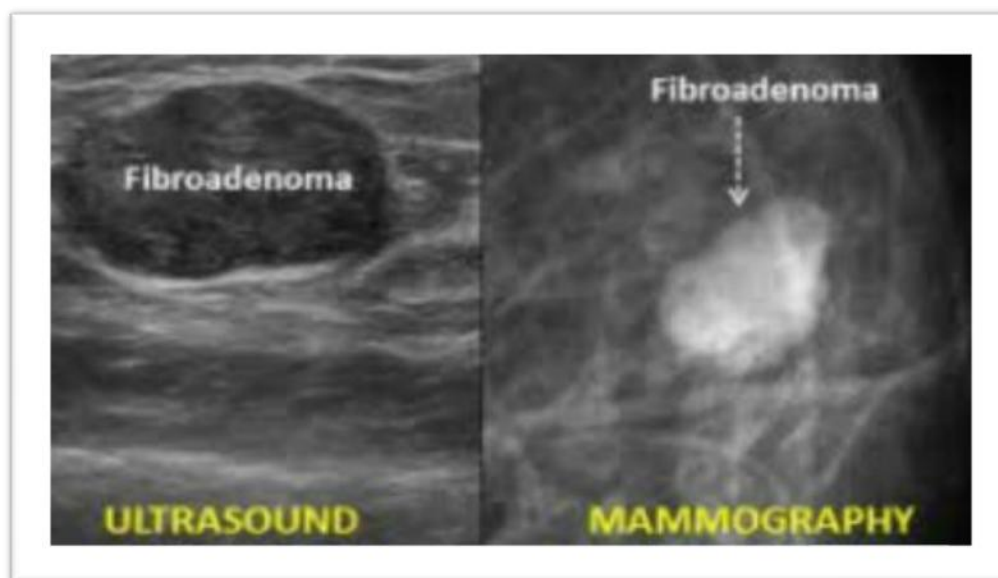


Fig No.10 Diagnosis methods^{11,12.}

Fibrosis :

Fibrosis refers to a large amount of fibrous tissue, the same tissue that ligaments and scar tissue are made of. areas of fibrosis feel rubbery, firm, or hard to the touch.

Cysts:

A round, movable lump, which can also be tender to the touch, suggests a cyst. Cysts are fluid-filled, round or oval sacs within the breast. They are mainly observed in 40s, but can occur in women of any age. Monthly hormone changes often cause cysts to get bigger and become painful and sometimes more noticeable just before the menstrual period. To diagnose a breast lump as a fibroadenoma, the specialist will take into account:

- Any need for further testing to confirm the diagnosis i.e. taking some cells from the lump for testing, needle cytology or surgical removal.
- The results of a physical examination and ultrasound or mammogram.
- The history, shape and size of the lump
- Your age
- Whether there is a history of breast or ovarian cancer in your family.
- If the lump is growing over time.

Fibroadenomas usually become noticeable as a lump in the breast. If you find a breast lump, see your GP (local doctor). They're likely to refer you to a breast clinic where you'll be seen by specialist doctors or nurses. At the breast clinic you'll have various investigations, known as 'triple assessment', to help make a definite diagnosis.

The assessment consists of:

- A breast examination.
- Ultrasound scan (uses high frequency sound waves to produce an image) and a mammogram (breast x-ray).
- A core biopsy and/or a fine needle aspiration (FNA).
 - A core biopsy uses a hollow needle to take a sample of breast tissue.

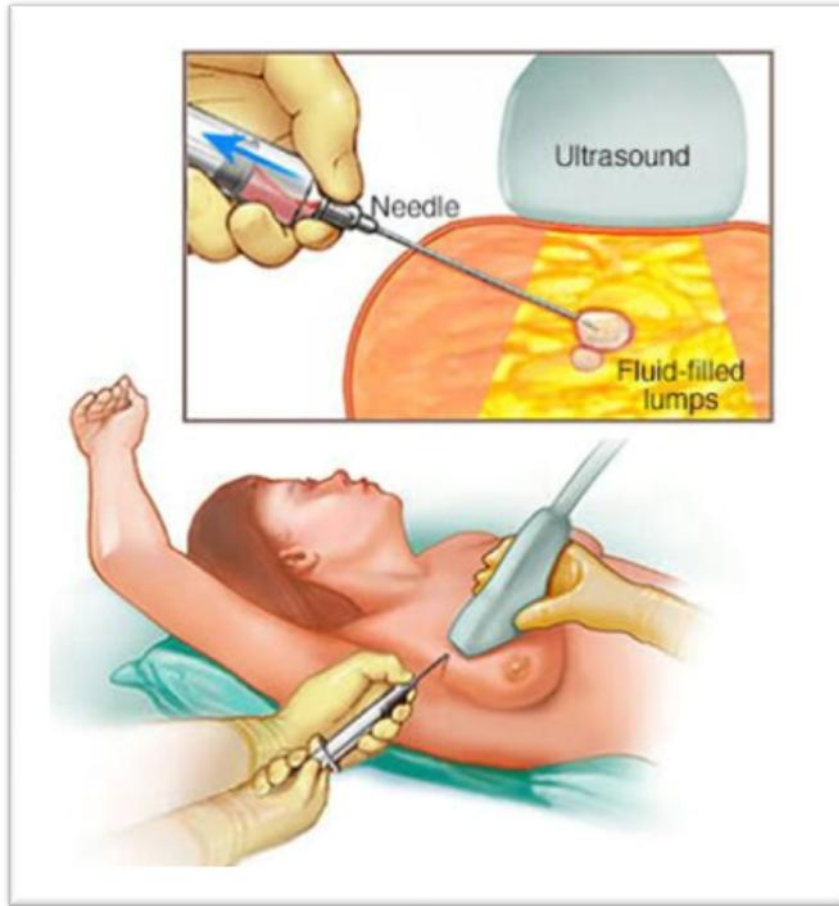


Fig No.11 Core biopsy method^{11,12.}

VII. Treatment^{9,12,13,14.}

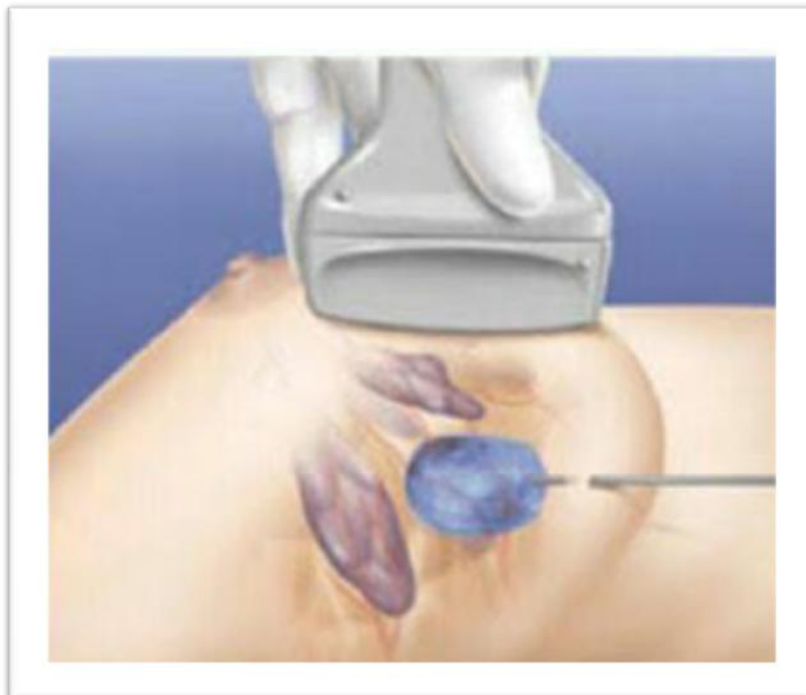

Fig No.12 Treatment^{11,12.}

Most of the fibroadenoma found in right breast (49%) with 9(5.4%) cases presenting bilaterally. Upper lateral quadrant was the main location of the tumors followed by lower medial. Ten cases presented with multiple lumps in the breast. The size of the tumors varies 1-18cm. Giant fibroadenomas >5 cm were found in 68(32%). In most of the cases you won't need any follow-up or treatment if you have a fibroadenoma. Usually you'll only be asked to go back to breast clinic if it gets bigger or you notice a change. Most fibroadenomas stay the same size. Some get smaller and eventually disappear over time. A small number of fibroadenomas get bigger, particularly those in teenage girls. Sometimes operation called an excision biopsy is needed to remove a fibroadenoma. This may be done using a local or general anaesthetic. Surgeon may use dissolvable stitches placed under the skin which won't need to be removed. However, if a non-dissolvable type is used, they will need to be taken out a few days after surgery. You'll be given information about this and about looking after the wound before you leave the hospital. A vacuum assisted excision biopsy to remove the fibroadenoma. This is a way of removing small fibroadenomas under local anaesthetic, without having anaesthetic, a small cut is made in the skin. A hollow probe connected to a vacuum device is placed through this. Using an ultrasound or mammogram as a guide, the fibroadenoma is sucked through the probe by the vacuum into a collecting chamber.

The biopsy device is used in this way until all of the fibroadenoma has been removed. The removed tissue is examined under the microscope. This procedure can cause some bruising and pain for a few days afterwards. Removing a fibroadenoma does not usually affect the shape of breast, but there may be a slight dent in the breast where it has been removed. Nutraceuticals also used in fibroadenoma. Nutraceutical is no new concept, it has always been around and practised by many mothers around the globe, but only after being given a fancy name tag. Nutraceutical has potential benefits of becoming the most popular sector in the near future and now itself the products are selling like hot cakes that too with everyone turning vegan and stuff. Being instrumental in the prevention and cure of fibroadenoma is just one aspect of nutraceuticals, it has much more such cures which are under stringent study and can be implemented in the future bringing commendable benefit to women and all mankind in general in a nutritious and organic way.

Diet which help to prevention of fibroadenoma:

- Consider higher intake of fruits and vegetables.
- Vit E also plays important role in prevention of fibroadenoma.
- Consume fish, nuts and walnuts.
- Include Vit C rich foods like citrus fruits, oranges, amla, mangoes, etc.
- Consume carotenoid rich food, which are usually yellow or orange coloured like carrots, oranges, papaya, sweet potatoes, pumpkin, melons,
- Include low fats in your diet like skimmed milk, low fat cheese, low fat cottage cheese, low-fat yogurt.
- Consume high fibrous foods like whole cereals, green leafy vegetables, whole fruits (instead of juices).⁹
- Avoid high fat food, fried foods, caffeine, and meats egg yolks.
- Avoid refined products like white sugar.

VIII. Conclusion:

The benign breast fibroadenoma diseases seen in a rural setup followed by fibroadenomatosis, giant fibroadenoma, tumor, cysts in that order. Those conservative observation can be followed by young women or the teenagers. Diagnosis of fibroadenoma should entail a detailed medical evaluation with imaging studies. Management of fibroadenoma may be conservative, but excision by total enucleation of the mass may be performed. Patients should undergo regular follow-up to assess complications, measure outcomes, and evaluate the need for subsequent reconstructive surgery. Throughout treatment, patients should be counseled about the benign nature of the mass, the different surgical and non-surgical approaches, and the need for continued follow-up determine if additional surgery is necessary. More long-term outcomes data are needed to inform treatment recommendations for adolescent patients presenting with fibroadenomas of the breast.

Reference

- [1]. Shukla HS An outline of benign breast diseases, In: Recent advances of surgery R L Gupta: 1992.
- [2]. www.breastcancercare.org.uk.
- [3]. www.recentscientific.com.
- [4]. Peterborough regional healthcare, 1 hospital drive (W3630) Peterborough. www.prhc.on.ca
- [5]. Ernest VL. The Epidemiology of benign breast disease. *Epidemiol Rev* 198;15:177-87.
- [6]. Iyer SP. Epidemiology of the of benign breast diseases in a females of childbearing age group. *Bombay Hosp Jr* 2000;42:10.,
- [7]. www.thebreastcenter.co.nz
- [8]. www.jsirljournal.com.
- [9]. www.thewomens.org.au
- [10]. Women's Health Matters (June 2007). benign breast tumours. Retrieved March 4, 2010 from <http://womenshealthmatters.ca/centers>
- [11]. www.google.com.
- [12]. www.Vectorstock.com/16178660.
- [13]. www.isca.in/www.iscs.me

- [14]. Bieicher RJ chapter 4: Management of the palpable breast mass. In: Harris JR, Lippman ME, Morrow M, Osborne CK, eds. *Diseases of the breast*, 5th ed. Philadelphia, Pa: Lippincott Williams and Wilkins; 2014.
- [15]. Breast cancer information exchange project (OBCIEP).
- [16]. Kneeece, J (2003) finding a breast lump in your breast lump. Where to go..... what to do. *Columbia Educare Inc.*
- [17]. Orchicha O. benign breast lesions in Kano. *The Nigerian Journal of Surg Research* 2002;4:1-5.
- [18]. Wilkinson S, Anderson TJ, Rifkin E, Chetty U, Forrest AP. Fibroadenoma of the breast: a follow-up of conservative management. *Br J Surg* 1989;76:390-1.
- [19]. Khanna S. Spectrum of breast disease in young females: A retrospective review of 22 years. *Indian Journal of surgery* 1980; August:419-25.
- [20]. CA: sanarus medical, Inc; 2008. available at <http://www.sanarus.com> or document or visica-2-Brouchuer.pdf.
- [21]. Haque the breast lesions a clinicohistopathological study of a 200 cases of breast lump. *Indian journal of surgery* 1980; August:419-25.
- [22]. Iglehart JD. Diseases of breast, In: Townsend CM ed. *Sabiston Textbook of Surgery*, 16th edition ed: Saunders Company; 2001:255-90.
- [23]. Ontario breast cancer information exchange project (1996). *benign breast disease OBCIEP*: Toronto, Ontario.
- [24]. Lauersen, N and Stukane, E (1998), *the complete book of breast care*. New York: columbine.

Mayuri.K.Lonare, et. al. "Breast Fibroadenoma an Overview." *IOSR Journal of Pharmacy and Biological Sciences (IOSR-JPBS)*, 15(4), (2020): pp. 59-69.